

The Effect of Fusion on the Adjacent Segment Motion in a Lumbar Spine

BY

MRUGA D. PATEL

B.Tech, Ganpat University, India, 2012

THESIS

Submitted as partial fulfillment of the requirements
for the degree of Master of Science in Bioengineering

in the Graduate College of the
University of Illinois at Chicago, 2014

Chicago, Illinois

Defense Committee:

Dr. Thomas Royston, Chair

Dr. Raghu Natarajan, Advisor, Rush University Medical Center

Dr. Jun Cheng

ACKNOWLEDGEMENTS

I would like to express my gratitude to my advisor, Dr. Raghu N. Natarajan for providing guidance in all areas that helped me accomplish my research goals and enjoy myself in the process. I would also like to thank my thesis committee members, Dr. Thomas Royston and Dr. Jun Cheng for their support and assistance. I would also like to acknowledge the Department of Orthopedic Surgery at Rush University Medical Center.

TABLE OF CONTENTS:

CHAPTER

1. Introduction.....	1
A. Anatomy of Spine	1
B. Disc Degeneration Disease.....	5
C. Low Back Pain.....	7
D. Lumbar Spine Fusion.....	11
E. Adjacent Segment Degeneration Disease.....	14
F. Thesis Goals.....	18
2. Background and Related Literature.....	19
A. In Vitro Studies.....	19
1) Motion Segments With Interbody Fusion.....	19
B. In Vivo Studies.....	23
1) Motion Segments With Interbody Fusion.....	23
C. Related Existing Finite Element Models.....	26
D. Purpose of Studies.....	28
3. Methods and Materials.....	30
A. Finite Element Intact Model Construction (Model 0).....	30
1) Geometric Considerations.....	30
2) Material Consideration.....	32
3) Boundary Conditions.....	34
B. Finite Element Fused Model Construction.....	34
1) L4/L5 Fused- Model 1: L4/L5 Fused: Grades Of Degeneration II, III, IV And V At L5/S1.....	36
2) L5/S1 Fused- Model 2: L5/S1 Fused: Grades Of Degeneration II, III, IV And V At L4/L5.....	36
3) L4/L5 And L5/S1 Fused- Model 3: Both L4/L5 & L5/S1 Fused: Grades Of Degeneration II, III, And IV At L3/L4.....	37
C. Inclusion Of Adjacent Segment Disc Degenerative Disease.....	38
D. Loading Conditions.....	40
4. Validating of grade specific finite element model of a lumbar spine.....	41
5. Results.....	42
A. Single Level Fusion.....	45
1) Effect Of Fusion On The Segment Adjacent To The Fusion.....	42
i) Normal Adjacent Segment.....	43
ii) Adjacent Segment Degenerated Disease.....	45
B. Double Level Fusion.....	59

1) Effect Of Fusion On The Segment Adjacent To The Fusion.....	59
i) Normal Adjacent Segment.....	60
ii) Adjacent Segment Degenerated Disease.....	61
6. Conclusion.....	79
7. Discussion.....	84
8. Cited Literature.....	86

LIST OF TABLES:

1. Element Definition for Finite Element Model.....	31
2. Material Properties in Finite Element Model.....	32
3. Stress-Strain Relationship Defined For The Annular Fibers And Spinal Ligaments.....	33
4. Geometrical Parameters Used To Generate Degenerated Discs From Normal Disc.....	38
5. Annulus Material Properties Assumed for Degenerated Discs.....	39
6. Nucleus Material Properties Assumed for Degenerated Discs.....	39

LIST OF FIGURES:

1. The anatomy of spine: Cervical, Thoracic, Lumbar, Sacrum, Coccyx.....	1
2. Overhead View Of Vertebra.....	2
3. 3a. Motion Segment And Intervertebral Disc.....	3
3b. Components of an Intervertebral Disc.....	4
4. Discs Degeneration Disease At Lumbar Section Of Spine.....	6
5. Bone Graft Placed In The Lumbar Spine At L4/L5 For Fusion.....	12
6. Anterior Lumbar Interbody Fusion.....	13
7. Disc Degeneration At L3/L4 After L4-S1 Fusion.....	17
8. Model 0: Intact Model Of Lumbar Spine.....	34

SUMMARY

Back Pain is one of the most prevalent work related injuries in the United States. It has been shown that heavy physical work, and injuries in addition to other physiological conditions cause back pain. In cases of severe back pain, surgeries are conducted and grafts are implanted at sites where disc material is removed. Thus it is important to understand how these grafts affect the mechanical response of the spine to loading in postoperative conditions. A finite element model of the lumbar spine was constructed to study the biomechanical response due to loading. The model was used to conduct the investigation of the change in motion at the segment adjacent to the fusion. The study was repeated with the inclusion of adjacent segment degenerated disease. For a single level fusion, it was observed that in a spine with bone graft fusion produced decreased motion at the level of fusion as compared to the motion in normal lumbar spinal motion segment. For all the loading modes considered, segment fused with the graft was found to be stiffer than the normal segment. Similar observation was made in a spine with ASDD. The finding that the fusion makes the motion segment stiffer is consistent with experimental and clinical findings. The graft bone deformed more like a solid along with the adjacent vertebra and thus produces lesser rotational motion due to bending loads. When fusion was modeled using a graft bone either in a spine with normal bone or a spine with ASDD, the reduction in motion due to fusion remained nearly the same. The motion in the segments superior and inferior to the segment fused by the graft in normal bone increased marginally, But when the fusion was modeled with the spine having ASDD, the motion at that adjacent segment decreased with the increasing grades of degeneration. Thus, motions in the segments adjacent to the fusion behaved differently when fusion was achieved in normal bone as compared to the spine with the ASDD. For a two level fusion, it was observed that the bone graft fusion in normal bone produced decreased motion at both the levels of fusion as compared to the motion in a normal lumbar

spinal motion segments. For all the loading modes considered, segment fused with the graft was found to be stiffer than the normal segment. Similar observation was made in a spine with ASDD. Reduction in motion at L4/L5 level was similar to those observed when single level fusion at L4/L5 was studied. This phenomenon was observed both in normal spine as well as spine with ASDD. . The motion in the segments superior and inferior to the segment fused by the graft in normal bone increased marginally, But when the fusion was modeled with the spine having ASDD, the motion at that adjacent segment decreased with the increasing grades of degeneration. Thus, motions in the segments adjacent to the fusion behaved differently when fusion was achieved in normal bone as compared to the spine with the ASDD.

From the current study, it was concluded that the behavior of the fused segments was similar in both single level and two level fusion cases. The percentage reduction in motion was also similar in both single level and two level fusions either with normal spine or the spine having ASDD. The effect of fusion on the motions of adjacent segments was also similar in single level fusion and two level fusions. The motions at the adjacent segment were affected by the grades of degeneration at that particular segment adjacent to the fusions.

The following conclusions are achieved from the current study:

- 1) The fusion with graft in both normal bone and with ASDD produces decrease in motion at the level of fusion and increase in motion at the adjacent segments when compared to the motion at normal lumbar spinal motion segment. This conclusion was applicable for both single level and two level fusions.
- 2) When the fusion was modeled with the spine having ASDD, the motion at that adjacent segment decreased with the increasing grades of degeneration. This conclusion was applicable for both single level and two level fusions.

To determine the effect of fusion on the adjacent segment motion in a lower lumbar spine

INTRODUCTION

A. Anatomy of the Spine

The spine plays an extremely important role in a body as it supports the weight of the upper body, protects the spinal cord as well as, provides posture while allowing movement and flexibility. The spine is also known as a spinal column because it has a column of 26 bones in an adult body i.e., 24 separate vertebrae interspaced with cartilage, and then additionally the sacrum and coccyx which are connected in the front of the spine by intervertebral discs. There are seven cervical, twelve thoracic, five lumbar, a single bone in sacral fused by five small vertebrae and a single bone in coccyx fused by four small vertebrae (Figure 1).

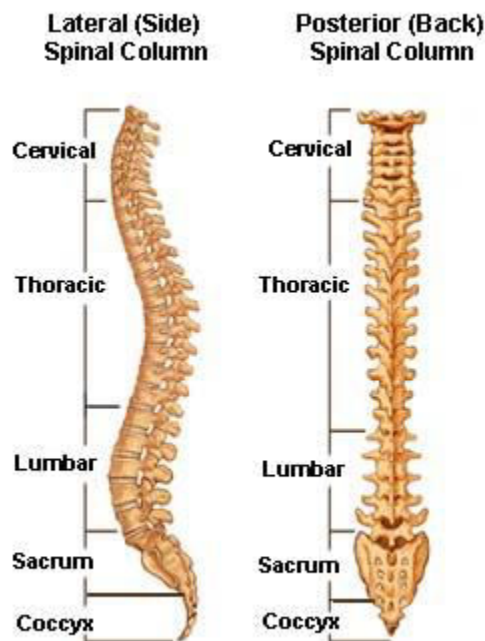


FIGURE 1: The anatomy of the spine-Cervical, Thoracic, Lumbar, Sacrum, Coccyx.
(www.spineuniverse.com)

Each vertebra consists of substructures namely the body, vertebral foramen, spinous process and the transverse process. The vertebral body bears all the weight, which makes the body's mass up. The transverse process, extending from the body are the thin columns of the bone that points towards left and right sides of the body. The spinous process extends from the ends of the transverse processes in the posterior direction. The vertebral foramen is between the body, spinous process and transverse process. The vertebral foramen is the hollow space that contains spinal cord and meninges. The laminae form the walls of the spinal canal. The below is the figure of the vertebra (Figure 2).

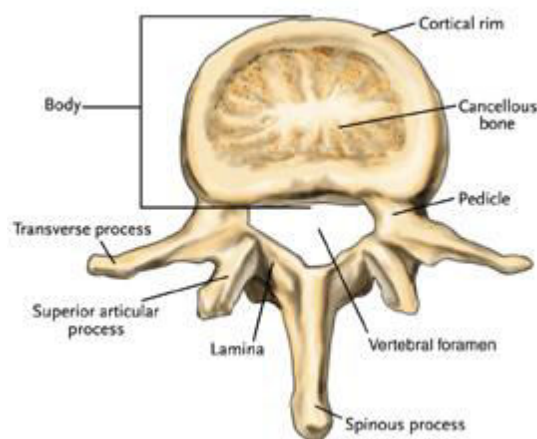


FIGURE 2: Overhead view of the vertebra. (www.indyspinemd.com).

A motion segment, also known as functional spinal unit is the functional unit of the spine (Figure 3a). Motion segment is made up of the bony and soft tissue structures; motion segment comprises of two adjacent vertebral bodies, the facet joint created by the articular processes and the intervertebral discs separating the two vertebrae. Mobility and stability makes lumbar spine motion more complex. The

stability is provided by the motion segment, by allowing restricted motion range. The primary motion in the upper lumbar motion segment is lateral bending. The primary motions in the lower spine and the lumbo-sacral region are flexion and extension. The facet joints and the intervertebral disc allow the flexion, extension, lateral bending and the axial rotation of the motion segment. The facet joints are formed by the overlapping of the projections of the upper portion of the lamina known as superior articular process and are overlapped by the lower projection of the lamina namely inferior articular process of the adjacent vertebra. The main purpose of these structures is to protect the spinal cord and to provide the site of muscle attachment.

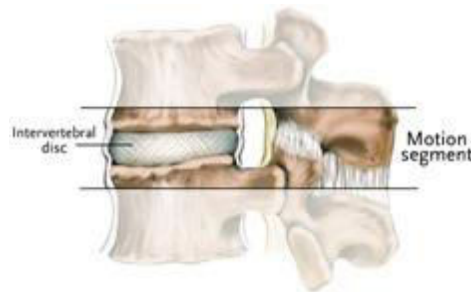


FIGURE 3a: Motion segment and intervertebral disc. (www.brianjogrady.com).

Intervertebral discs are the thin regions of the cartilage between the vertebrae of the spine (Figure 3a). The outer shell of the intervertebral disc is known as annulus fibrosus and the pulpy region in the middle is known as nucleus pulposus (Figure 3b). The fibrocartilage in the annulus fibrosus binds the vertebrae together but, its flexibility allows all the movements. The vertebrae is prevented from crashing into one another because of the shock absorber and support of the body weight, the nucleus pulposus. Intervertebral disc has the higher water content. A normal healthy disc is one of the strongest parts of the spine. A normal disc can be damaged by extreme forces.

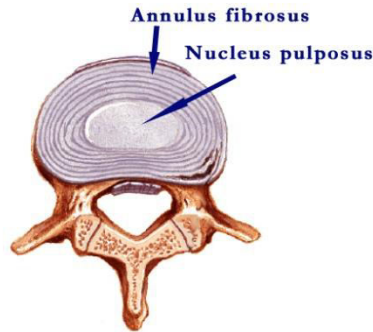


Figure 3b: Components of an Intervertebral disc.

The lumbar spine is the complex structure between the ribcage and the pelvis, which includes 5 vertebrae, intervertebral discs to absorb shock, joints, the spinal cord, and five nerve roots. There is an increase in size of the vertebra from L1 through L5, indicating the higher loads the lower lumbar vertebra bears. The heaviest vertebra with the spinous process being smallest and the transverse process being thickest is L5. From the spinal cord, nerve roots branch like tree through foramen. The transmission of the impulses to the brain and back is done by the nerve roots.

The lumbar spine is subjected to a vast array of complex conditions while performing daily activities. The lumbar spine is responsible for the flexibility: lifting, twisting, and bending. All these motion not only include flexion and extension but also lateral bending and rotation. Spinal fusion with cages decreases motion in those lumbar segments where placements of these devices take place.

B. Disc Degeneration

Disc degeneration is a term used to describe the normal changes that takes place in the spinal discs as a result of ageing. The intervertebral discs are very soft, compressible discs which separate vertebrae from each other building up the spine. The discs are the shock absorbers of the spine allowing flexion, bending and twisting. Degenerative disease can take place throughout the spine but, it often occurs at the lower lumbar section (Figure 4) of the spine causing lower back pain and in the neck (cervical) region.

Discs Degeneration can be caused due to loss of fluidic materials from the disc. This decreases the ability of the discs to perform their very important role as a shock absorber and also reduces the flexibility. The discs become thinner because of the loss of the fluid and also the distance between the two vertebrae is reduced. If there are any tears or cracks in the outer layer of the disc, specifically, annulus or capsule, jelly like material from the nucleus may be forced out through that cracks into the capsule causing the disc to either bulge, rupture or break into fragments. Disc degeneration is seen more often in people who smoke cigarettes or do heavy physical work.

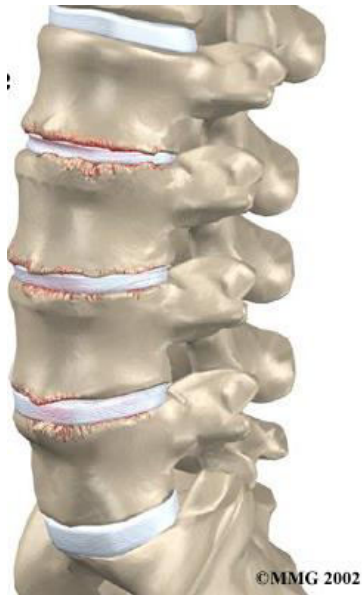

Figure 4: Discs degeneration disease at the lumbar section of the spine
(www.methodistorthopedics.com)

C. Low Back Pain

Back pain is felt in the back originating from the structures of the spine mainly muscles, bones, joints and nerves. Back pain and more specifically lower back pain are seen most commonly in the human beings. About 90% of the individuals have the pain of lower back at some point throughout their life as well as 50% of the working individuals experience back pain every year (Patel et al., 2007). Low back pain causes 40% of missed days of work in the United States (Manchikanti et al., 2009). Also, it's the single leading cause of disability worldwide (Institute for health Metrics and Evaluation). Herniated disc is the most common neurologic impairment which is associated with the lower back pain condition, from which 95% of disc herniation occurs at the lowest two lumbar intervertebral levels (Back Pain, 2010). 40% of the adults do experience this pain. Classification of lower back pain whether acute, subchronic or chronic is done by the duration of the pain the individual have had. Also, more classification can be done as mechanical, referred pain or non-mechanical. Low back pain is developed after the movements that involve lifting, twisting or bending forward. It may also be experienced during the movements like raising the legs or positions like sitting and standing. The radiation of the pain down the legs (sciatica) may also be experienced. The acute lower back pain may be triggered between the age 20 and 40.

The lumbar spine has a complex anatomy and has an exceptional combination of five sturdy movable vertebrae (L1-L5), tendons, ligaments, bony elements, muscles and the nerve roots. The lumbar spine is designed in an astonishingly strong way to protect the supersensitive spinal cord and spinal nerve roots. The lumbar spine is very yielding and allows motion in flexion, extension, lateral bending, and axial rotation. This combination of complexity and mobility makes the back susceptible to pain and injury. Lower back pain can significantly reduce a patient's range of motion and his/her ability to perform normal back motions. Degeneration of the intervertebral discs has been found to be one of the major

factors leading to severe back pain. Commonly, the lower levels of the lumbar spine are more susceptible to the disc degeneration.

The common causes of the lower back pain are:

- Injury or overuse of muscles, ligaments, and joints.
- Pressure on the nerve roots in the spinal canal. The common causes are:
 - Herniated disc: caused by repeated motion or vibration, or a sudden increased pressure or a heavy strain on the lower back.
 - Osteoarthritis: result of ageing. It affects the small joints in the spine, which may lead to back pain. Osteoarthritis in hip joints may cause a patient to change the way of walking, it can again lead to low back pain.
 - Spondylolisthesis: a defect that allows sliding of one vertebra over another.
 - Spinal Stenosis: result of ageing, it causes narrowing of the spinal canal.
 - Fractures: caused by a lot of force, such as an accident- a direct blow to the spine from an automobile or a bike accident, or even a compressive fracture by compressing a spine by falling onto the head or buttocks.
 - Spinal deformities: curvature problems- kyphosis or scoliosis.

To determine the best course of treatment, obtaining a proper diagnosis is mandatory. A patient's medical history is carefully studied. Apparently, the diagnosis of the lower back pain involves the history of illness and physical examination. A thorough review of the history of the injury, aggravating and alleviating conditions, associated symptoms like fever, tingling, numbness, as well as, duration and the progression of the symptoms is conducted. Apart from the routine evaluations in the abdomen and

the extremities, rectal and pelvic evaluation may also be required to be conducted eventually, in some cases. Further diagnosis of lower back pain can include blood and urine tests. Radiographic tests like X-ray, CAT scanning, magnetic resonance imaging scanning, bone scanning, and tests of nerves such as myelograms and electromyograms as well as nerve conduction velocities may also be conducted.

Most cases of the back pain origin from the strain. Patients may be recommended to stop the normal physical activities for the first few days. Physical therapy is often incorporated into the treatment plan. Applying heat or ice to the painful area is also recommended, ice is applied for first few days and then heat is applied. These passive forms of physical therapy may help in alleviating the pain. Depending upon the cause of the back pain, taking over the counter pain relievers such as ibuprofen and acetaminophen may be prescribed. Light aerobic training and stretching and strengthening exercises helps in building strength and increase the range of motion.

In some cases, excruciating pain and weakness unrelieved by conservative measures are indications of the surgical intervention. The type of surgical procedure is dependent on the patient's age, needs, medical history, and general physical condition. In addition, lower back pain surgery should only be considered when all the non-surgical treatment options have been tried and failed. Some types of chronic back pain cannot be treated without the surgery.

There are several surgical procedures that may be used to treat the lower back pain:

- Spinal Fusion: the design used here is to fuse the vertebrae causing pain together and causing them to heal in a single bone restricting the motion. Spinal fusion restricts the mobility between those vertebrae. This is an alternative when the source causing the pain is motion.

- Disc replacement: This involves the procedure in which the disc is removed and replaced with the artificial parts. The main aim of the disc replacement is to allow the spinal segment to maintain some flexibility and perform normal motion to more extent.

D. Lumbar Spine Fusion

Lumbar Spinal fusion is the surgical technique in which one or more vertebrae are fused together in order to reduce the motion considerably. There are many potential reasons for a surgeon to consider the fusion of vertebrae such as treatment of a fractured vertebra, correction of a deformity including spinal curvatures, elimination of pain caused by motion, treatment of instability and some lumbar disc herniations. There are many surgical methods to fuse the spine and they all involve the removal of the affected disc materials and replacing it with other artificial materials or the bone graft. It is really very important for the source of pain to be known and also the location of the instability in order to treat the cause in a very effective manner. After the cause is known, the technique and the appropriate instrumentation can be chosen for the surgery.

Bone Graft:

Bone grafts for the spinal fusion may either be harvested from the patient that are called autologous grafts (provides calcium scaffolding, and osteophytes that allows cell growth) or from a cadaver called allograft bone (provides calcium scaffolding, does not allow cell growth so less chance of fusion compared to the patient's bone). The graft is placed using anterior, posterior or combination of both the approaches. Bone has an ability to regenerate itself completely, but it requires a scaffold for that. Many of the bone grafts are either reabsorbed or replaced by the natural bone over the time of months. The bone graft does not form fusion at the time of the surgery but it provides the environment to the body to form a new bone and fuse that section of spine together. In posterior lumbar interbody fusion, the disc is accessed from the posterior side by posterior incision. There are many considerations to be taken into account in order to decide the type of bone graft to be used. Those factors are:

1) Type of fusion:

It can be Anterior Lumbar Interbody Fusion or Posterior Lumbar Interbody fusion.

2) Total number of levels in the spine involved.

3) Location or site of fusion.

4) Risk factors of the patients:

If the patient is obese, or a smoker or the patient has poor bone quality.

5) Experience of the surgeon and the preference.

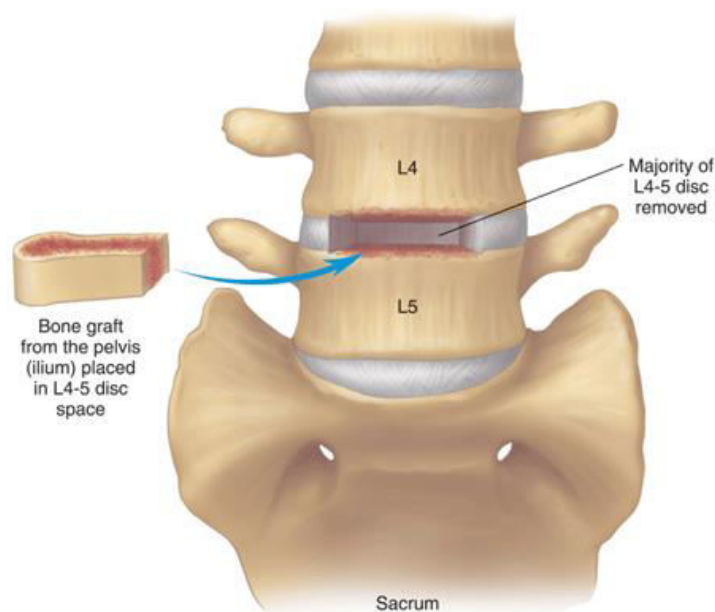


FIGURE 5: Bone graft placed in the lumbar spine at L4/L5 for fusion

Anterior Lumbar Interbody Fusion:

Anterior Lumbar Interbody fusion procedure treats problems such as disc degeneration, instability, and the deformities in the curvature of the spine. In this surgery, the procedure involves to operate the spine anteriorly and remove the disc in the lower lumbar spine. The bone is inserted between the two vertebrae where the disc is removed. The aim of the procedure is to simulate the vertebra to grow together into one

solid bone. This procedure of rigid fixation is called fusion. Fusion is used to create a rigid immovable column of the bone in the spine where there is a problem. This type of procedure is done to reduce the problems like back pain.

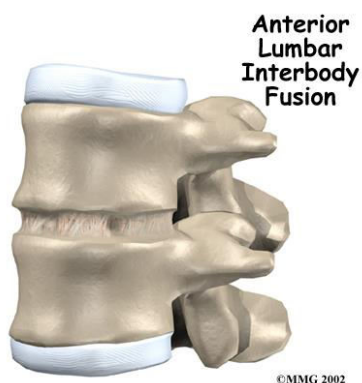


FIGURE 6: Anterior Lumbar Interbody Fusion (www.methodistorthopedics.com)

E. Adjacent segment degeneration disease (ASDD):

The adjacent segment degeneration disease has always been controversial. There was also a controversy on the development of the adjacent segment degenerated disease that, was it happening due to progression of the disease or was it associated with the phenomena of fusion. But then, Later it was found out that fusion has only small effect in the development of the adjacent segment degenerated disease (Song et al., 2011).

Adjacent segment degeneration is a condition that occurs after the spinal fusion or other surgery in the back is done. This disease affects the intervertebral joints either above or/and below the area that underwent the surgery. The factor that works in development and progression of this condition is the increasing age. The reason behind the development of this disease is that after the spinal fusion, a patient is likely to lose the ability to move the spine at the place where surgery was done. So, the patient would no longer be able to move or bend forward, tilt, or twist. But then, the motion has to be compensated in order to perform various tasks. So ASDD causes the additional wear and tear of the intervertebral joints above and below the surgery. These joints have to make more efforts in order to make up for the (now) immovable portion of the spine. As such they are subject to extra stress, and this leads to degenerative changes.

In (2009, Choon et al.,) assessed the adjacent segment degenerated disease and their risk factors associated with the lumbar fusion. The incidence of adjacent segment degenerated disease was assessed in the patients who underwent the lumbar and the lumbosacral fusion. The diseased patients were matched with the patients in the control group by age, sex, fusion level, and the follow up period. It was observed that there was a relatively low incidence of the adjacent segment degenerated disease after lumbar or lumbosacral fusion. But then, the patients with adjacent segment degenerated disease had severe symptoms and frequent neurological abnormalities.

(Perrin et al., 2003) suggested in the paper Prevention of the adjacent level degeneration above a fused vertebral segment. There should be an intermediate zone to transition load between the fixed segment and the free segment.

The five main reason that are considered responsible for the adjacent segment degenerated disease are:

1. Reason for the back surgery:

The diagnosis that is done for the back surgery, can give an idea if the patient is at the risk of developing adjacent segment degeneration disease. People who undergo the spinal fusion are at the increased risk of developing the adjacent segment degenerated disease, because the degeneration has already started in the levels above and below the problematic area even though the symptoms are not noticed (Dr. Toerge, National Rehabilitation Hospital's Musculoskeletal Institute). People with severe arthritis are also at increased risk of developing adjacent segment degenerated disease because they have fewer mechanical elements that can reduce risk.

2. Age:

Age is widely accepted factor for degeneration. As we age, our spine will degenerate. If such changes are occurring in the spine, they may be already there or may develop in more than one level, either with or without the surgery.

3. Location site of the surgery:

Spine has curvaceous areas that were divided into cervical, thoracic, lumbar, and sacral. The spine has opposing curves that allows us to move. If the surgery is done at the place where one curve transitions into the other curves, like if it is done at place when it transfers from thoracic to lumbar (T12-L1), the risk of developing the degenerated disease is higher. It is because these portions are called active motion segments and the fusion at the active motion segments often causes problems. Such fusions may

result in increased load at the intervertebral joints which ultimately leads into the adjacent segment degenerated disease.

It also depends on the level.(Disch et al., 2008) found lower risk of degeneration in patients with L5/S1 fusion and L5/S1 and L4/L5 fusion (two level) compared to fusion at L4/L5 only.

4. Length of the fusion:

There is significant higher risk of developing degenerated disease when multiple levels are fused than the single level. (Cheh et al., 2007) found that the length of the fusion was a significant risk factor in the development of the adjacent segment degenerated disease rather than the type of fusion. (Weinhoffer and associates in 1995) showed that increase in pressure within the adjacent levels correlate with the number of levels fused. (Schulte et al., 2007) studied the adjacent segment disc height reduction as an indication to the adjacent segment degenerated disease. Multiple level fusions led to more disc height change than the single level fusions with tendency towards more height reduction in the first adjacent disc compared to the second.

On the other hand, (Ghiseli et al., 2004)found that the single level fusion had a three times higher risk for development of the adjacent segment degenerated disease than the multiple level fusion.

5. Posture Before and During the surgery:

The posture as well as the alignment of the bones during the surgery may affect the risk of development of adjacent segment degenerated disease. The pelvis should not be tilted back at the time of surgery, and the angle of the sacrum should be in the proper direction. It should not be tilted slightly forward. So if this happens, the muscle that is responsible for holding the patient upright may fatigue and this would lead to pain and degenerative changes in the spine. And head should also not be in the forward position during the spinal surgery because then it would increase the chances of degeneration.

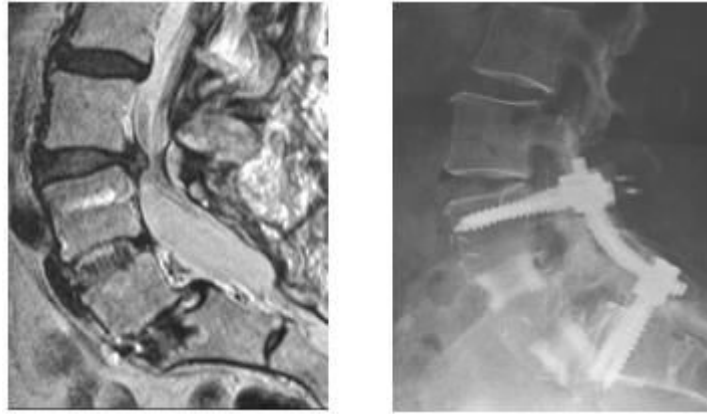


FIGURE 7: Disc degeneration at L3/L4 after L4-S1 fusion

Thesis Goals

Using the finite element modeling, the current study quantifies the biomechanical response of a lumbar spine model due to single-level and two-level interbody fusion procedures under flexion, extension, lateral bending and axial torsion. The following were the objectives:

1. To determine the effect of fusion on the adjacent segment motions in a lower lumbar spine considering:
 - a) Site of fusion
 - b) Number of levels fused
 - c) Grades of degeneration at the segment adjacent to the fusion level.

BACKGROUND AND RELATED LITERATURE

A. In Vitro Studies

1) Motion segments with Interbody Fusion:

Several in vitro experiments that used animal and human cadaveric spine models showed increase in mobility of adjacent segment because of fusion. (Bastian et al., 2001) presented a paper on a biomechanical study on evaluation of mobility after posterior thoracolumbar fusion. A two level fusion was conducted starting T12 through L2, in order to find out the effects on the mobility of the adjacent segments that were not fused. The motion of the segments adjacently inferior and superior to the fused segments in 10 human cadaveric thoracolumbar spine specimens were measured pre-fusion and the post-fusion by biomechanical testing in flexion, extension, lateral bending, rotation, data were collected and compared. There was significant increase in mobility during flexion and extension for T11/T12 segment. There was practically no increase in motion at the segment below the fusion L2/L3.

(Chow et al., in 1996) studied the effects of short anterior lumbar interbody fusion at one level and two levels of the lumbar spine and biomechanics of the adjacent unfused segments. In the study, six cadaveric lumbar spine specimens were tested biomechanically in flexion and extension. Before introducing a single level (L4/L5) and double level (L4-L5-S1) anterior interbody fusion, intradiscal pressure and the mobility of the segments were measured. The segmental mobility and the intradiscal pressure were also measured after simulating the single and double level fusion. The results of this study showed an evidence of increase in motion in flexion and extension in all the segments above and below the fused segment (L4/L5). When L5/S1 was also fused along with L4/L5, there was a loss of

segmental motion at L4/L5 and L5/S1 in flexion and extension which was then compensated by the increase in motion at all the segments above the fusion and the intradiscal pressure of all the intervertebral discs increased after the single and double level fusion.

(Esses et al., in 1996) analyzed the stiffness and motion in the anterior and posterior columns of the index and contiguous spinal motion units of anterior, posterolateral, and circumferential fusion. In the study, eight human cadaveric lumbosacral spines were biomechanically tested in compression-flexion and torsion using advanced biplanar radiography technique. Each specimen was first tested in the compressive loading. The loads applied were increased to 66.66N, 97.77N and 120N. With the preload and applied loads, the specimen was compressed and flexed. This combined compressed-flexion loading avoided much instability that may be caused during pure compression. After application of this combined motion the displacements were measured after initial small motions were dissipated. The axial torsion was also tested for each specimen. The loads applied were 8.88N, 17.77N, and 26.66N. After this, the fusions were simulated and then the specimens were retested in the same protocol. After completion of the loading protocol, the radiographic developed. At the level of fusion, the simulated anterior and posterolateral fusion, prevented more motion in torsion compared with compression-flexion. And the circumferential fusions were stiffer than the intact specimen. In comparison with the posterolateral fusion, anterior fusions have greatest effect of increasing motion at the adjacent levels. The effect of circumferential fusions on the adjacent segments was not significantly greater in comparison to the anterior fusion.

A similar study was done by (Lee Ck in 1984), investigating the change in kinematics and biomechanics of three types of spinal fusion- anterior, posterior, and bilateral-lateral, on the adjacent segments that were not fused as well as within the fused segments, and to

investigate their clinical implications. Sixteen human cadaveric spines were tested under a physiologic loading condition. The testing was done on L3-L4, L4-L5 and L5-S1 under combination of compressive and bending load. The unfused segment was tested first and then the fused segment was retested under the identical loading conditions. All types of fusion resulted into increased stiffness and bending. The maximum stiffness was seen in the anterior fusion, followed by the bilateral-lateral fusion and then the least increase in stiffness from all these three conditions was in posterior fusion.

The effect of immobilization and configuration on lumbar adjacent segment biomechanics was studied by (HA KY in 1993) and by using the canine spines; the motion and the facet load changed after the lumbo-sacral fusion in vitro at the segment adjacent to the fusion. The changes were observed under flexion, extension and lateral bending. An increase of 62% in extension, 85% in flexion, 30% in left bending and 26% in right bending in motion at the adjacent segment was observed after immobilization. Adjacent segment facet load remained unchanged under immobilized configuration or any load state. This study concluded that after the fusion at the segment adjacent to the fusion, the facet contact pattern changed, no change in load, and the motion at the segments increased when the lumbar spine reproduced the similar range of motion.

Similarly, (Nagata H in 1993) studied the effects of immobilization of long segments of the spine on the adjacent and distal force and lumbosacral motion. The changes in lumbar facet loading and lumbosacral motion were evaluated with increase in number of immobilized levels. After evaluation, it was concluded that the lumbosacral motion as well as the facet loading increased significantly. It also suggested that this immobilization of segments not

only influenced the motion at the adjacent segments but also the segments not adjacent to the fusion.

Mobility was measured before and after posterolateral fusion of the spondylolytic vertebra and its adjacent segment by (Alexsson P in 1997). it was done to measure the mobility effects on the adjacent segment to the lumbar fused segment over the time from the postoperative situation until the fusion heals. Six patients with low grade Spondylolisthesis were scheduled for spondylolytic lumbosacral segmental fusion. Each patient was examined using roentgen stereo photogrammetric analysis technique before the fusion and then 3 months, 6 months and 1 year after fusion. Fusion was done at the L4-L5 level where as Spondylolisthesis was at L5-S1. The translation motion of L5 with respect to S1 and L4 vertebra with respect to L5 were calculated. The mean values of the intervertebral translations were not affected significantly at the adjacent levels during the fusion consolidation period. In the first two patients, the mobility was increased and the transformation of the preoperative mobility in the lumbosacral to the L4-L5 segment during fusion consolidation was also verified. In the third and fourth patient, the mobility of the segment decreased. And in the last two patients, it was seen that the preoperative mobility was small and it was not significantly affected by the fusion.

B. In Vivo studies

1) Motion segments with interbody fusion:

Recent in vivo studies suggest that fusion can induce adjacent segment degenerated disease. A recent MRI after an interbody fusion with pedicle screw fixation for Spondylolisthesis found that more than 70% of the patients developed degeneration at the adjacent segments that were normal before surgery. (This study was done by K.H. Kim and colleagues in 2010). 69 patients underwent the instrumented single-level interbody fusion at L4-L5 and they showed no evidence of definitive disc degeneration at the adjacent segments when preoperative MRI was done. Plain radiographs evaluation was done after more than five years of the surgery. The patients were divided into two groups: Group I was isthmic Spondylolisthesis patients and Group II consisted of degenerative Spondylolisthesis patients. To diagnose radiologic adjacent segmented disease, MRI and plain radiographs were used. Clinical adjacent segmented disease means the symptomatic spinal stenosis, resulting into radio graphical changes. Symptomatic spinal stenosis is diagnosed using MRI and combined with neurological claudicating. The existence of radiologic adjacent segment disease on group I was 72.7% and on group II was 84%. In group I, 7 patients showed clinical adjacent segmented disease. And in group II, 6 patients showed clinical adjacent segmented disease. Patients with clinical adjacent segment disease showed less postoperative lordotic angle at L4-L5 level. If postoperative lordotic angle is maintained at about 20 or more, clinical adjacent segmented disease can be prevented in single level fusion.

In another study, lumbar fusion was also associated with adjacent segment morbidity. In (2009, Kanayama M.), studied to determine the presence and the type of the adjacent

segment deterioration once the posterior ligamentoplasty, posterolateral lumbar fusion, versus posterior interbody lumbar fusion was performed. 218 patients who underwent either single- level posterior L4-L5 pedicle screw instrumented fusion or ligamentoplasty were reviewed after 2 years. Patients included 91 males and 127 females. There were 75 cases of posterolateral lumbar fusion, 78 cases of posterior lumbar interbody fusion, and 65 cases of ligamentoplasty. The prevalence of adjacent segment morbidity in PLIF was 14.1%, 13.3% in PLF, 9, and 2% in ligamentoplasty. Prevalence of adjacent segment disease and re-operation rates seemed lower in ligamentoplasty than in fusion surgeries. PLIF developed adjacent-level instability and it required more frequent fusion surgeries than PLF.

A retrospective study conducted by (Suratwala S J, in 2009) reported that after 2 years of fusion, eleven out of eighty patients had developed adjacent segment degenerated disease.

A prospective randomized study on the long term effect of lumbar fusion on adjacent disc degeneration was conducted by (Ekman P in 2009). The objectives of this study were to determine whether the lumbar fusion in the long run accelerates the adjacent disc degeneration. 111 patients with isthemic Spondylolisthesis were randomized to exercise (n=37), 77 patients had posterolateral fusion, 37 with pedicle screw instrumentation, and 40 without pedicle screw instrumentation. Two digital radiographic measurement methods and the semi quantitative ucla grading scale were used to quantify the adjacent segment disease. One digital measurement method showed that the mean height reduction in EX group was by 2%, and by 15% in the posterolateral fusion group. The other method showed 0.5 mm disc height reduction in posterolateral fusion group compared to the EX group. The ucla grading showed 100% normal discs in EX group, compared to 62% in posterolateral group. There were no significant differences between the groups with the instrument and without the

instrument. In 47 patients with laminectomy, 27 patients had incidence of adjacent segmented disease. When longitudinal analysis was conducted, the posterior and the anterior disc height were reduced significantly in the posterolateral fusion, whereas in the EX group only the posterior disc height was significantly reduced. This study concluded that fusion accelerates degenerative changes at the adjacent segments compared with natural history. The study suggests that not only fusion but laminectomy is also of pathogenic importance.

(Disch A C in 2008) studied that after lower lumbar fusion, there is a higher risk of adjacent segment degeneration. In this study, long term clinical and radiologic outcome measures were used to determine the effect of lumbar fusion resulting into degenerative changes in the adjacent motion segment. Patients (20%) who underwent fusion at the L5/S1 segment showed lower risks of adjacent segmented disease compared to patients (46%) with fusion at L4/L5. Also, fusion at L4/L5 has higher risk of adjacent segmented disease in comparison with bisegmental fusion L4-L5-S1 (24%).

In a study done by Ishihara and colleagues for evaluating long term clinical and radiologic results for anterior interbody lumbar fusion for isthmic Spondylolisthesis, 23 patients were studied who were followed for more than 10 years. Radiographs demonstrated new adjacent disc degeneration by 52% in the upper adjacent level and in 70% of cases in the lower adjacent level at final follow up: rates of 4% and 5% per year occurred, respectively. MRI of eleven patients at final follow-up demonstrated 73% presence of intervertebral disc degeneration at the superior adjacent level and 100% at the inferior adjacent level. In a radiographic study evaluating the transfer of stress, (Frymoyer and colleagues in 1979) noted that the motion increased in order to compensate the motion at the adjacent segments following lumbar fusions using flexion-extension radiograph.

C. Related Existing Finite Element Models

Finite element studies of normal and fused spine models have shown an increase in intradiscal pressure in the disc adjacent to a fused level. A biomechanical comparison of posterolateral fusion and posterior fusion in lumbar spine was done by (Cheng CS and colleagues in 2002). Late postoperative complications occurred after posterior fusion and posterolateral fusion as a result of biomechanical alterations. The changes in the stress between those two fusion procedures have not been reported. To distinctly identify the biomechanical alterations those occur in the posterior fusion and the posterolateral fusion of lumbar spine, the load sharing of the vertebra, disc, facet joint, range of motion and the bone graft were computed in a finite element model. For stress analysis, five finite element models were created including intact lumbar spine, posterior fusion, posterolateral fusion, posterior fusion with implant and posterolateral fusion with implant. The differences between these two fusion procedures were estimated by the finite element model, and that were within 7% in stress of the adjacent disc, 3% in force of the facet joint above the fusion mass, and 5% in the range of motion. In lateral bending, the stress of pedicle in the posterolateral fusion without an implant was almost two times greater than intact lumbar spine. Similarly, the stress of pars interarticularis in the posterior fusion without an implant was again two times greater than the intact lumbar spine. After addition of implant, the difference between the two fusion procedures decreased but still the difference was relatively high.

(Chen CS and colleagues in 2001) also analyzed the stress on the disc adjacent to the interbody fusion in lumbar spine. Accelerated disc degeneration in the disc adjacent to the fusion was observed after anterior lumbar interbody fusion. A finite element model from L1-L5 was created to study and understand the stress distribution of the adjacent disc. The intact model was

modified to create a fusion model and anterior interbody fusion was simulated. Loading conditions in all degrees of freedom were applied to the finite element model to study the corresponding stress distribution. From the finite element model, it was concluded that at lower fusion sites or more fusion levels, the stress of the disc adjacent to the interbody fusion increased than the superior fusion site or single level fusion under flexion, lateral bending and torsion. Larger stress was seen at superior disc adjacent to the interbody fusion than the inferior disc adjacent to the fusion. The superior disc adjacent to the fusion had little alteration under torsion, in stress distribution.

D. Purpose of Study:

Much discussion to the biomechanics of interbody fusion can be found in past and current literature. Little is known regarding the immediate postoperative biomechanical environment at fusion site either from clinical or an experimental point of view (Maciejczak et al., 2001). The biomechanical effect of the stability of the segment which has undergone fusion as well as the change in flexibility in the adjacent segments has not been well defined in the literature. Adjacent segmented degenerative disease can develop in the unfused segments after the fusion surgery. The critical barrier to progress in understanding the development and progression of adjacent segmented degenerative disease is that changes in biomechanics at the segments adjacent to degenerated discs or adjacent to surgically altered or treated segments have not been studied in a comprehensive and systemic fashion. Each study developed their own modeling techniques which were widely different from each other with different disc geometries and disc material properties. Thus while comparing the conclusions reached from the existing studies, the unknown factors of the effect of disc geometry, disc material properties, and other assumptions while developing the finite element models had to be taken into account. Moreover, the existing studies focus on a single variable that affects the adjacent segment motion such as fusion or a motion preservation system. So because of this, net effect of different variables that may cause adjacent segmented degenerative disease cannot be compared and prioritized. A refined 3D poro-elastic model of a lumbar spine with inclusion of parameters such as osmotic pressure and strain dependent permeability at all segment levels does not exist in current literature.

One of the challenging questions regarding adjacent segmented degenerated disease is to what degree the biomechanics of the adjacent segment is affected by severe disc degeneration and whether this is different from the effect of a fusion. No in vivo or model studies exist in literature on this issue even though disc degeneration is a very common occurrence in lumbar spine. Even though

several finite element studies exist in literature on the effect of fusion on adjacent segment motion, it is not possible to compare their results and prioritize the different variable that influences the adjacent segmented degenerative disease. This is because, each of these models are different (single level, three level, or five level lumbar spine models) and the model characteristics are unique to each one (factors like geometry of disc, material property of the disc etc.).

The current study built a single generic full lumbar spine poro-elastic finite element model validated by novel method. The models was built in such a way that the level of degeneration at each specimen corresponds to the cadaver specimen, as the model was validated by comparing the model predicted motions with cadaver test results. The results were compared using the analysis of variance technique. This validated model was then used to study different variables on adjacent segmented degenerative disease. The current study also proposed the analysis of the biomechanical effects of degenerations in a systematic fashion using the validated finite element model.

So, a single validated finite element model allowed a study of the effect of different variables such as type of fusion, number of levels fused, segments fused and degeneration grade at the adjacent segment and compared and prioritized various fusion options available based on the adjacent segmented degenerative disease.

METHODS AND MATERIALS

A. Finite Element Intact Model Construction

1) Geometric considerations

The finite element model was previously created using the ADINA module that is included in the commercial finite element software package ADINA (ADINA R-D Inc., Watertown, MA) by (Renner et al., 2007). A refined three dimensional poro-elastic finite element model of a lumbar spine with inclusion of parameters such as osmotic pressure and strain dependent permeability at all segment levels was built. The cortical and cancellous bone, nucleus, annulus, endplates and posterior elements were modeled by three-dimensional solid elements. The quadrilateral surfaces were defined by eight node three dimensional solid elements at the corner of the hexahedron. The triangular surfaces were defined as six node three dimensional solid elements, located at the corners of the prism. The three layers of annular fibers and the spinal ligaments were defined as three dimensional truss elements. This is because the trusses specifically react only to the tensile loads and has an ability to resist the axial forces. To define the truss elements, two end nodes were defined at the cross-sectional area of the given element. The model has 6291 number of elements. Within the finite element model, 92 groups of elements were defined. Three layers of annular fibers were embedded in the annulus at an angle of $\pm 30^\circ$ with the horizontal plane, which is similar to the actual structure of the annulus (White and Panjabi, 1990).

Facets, both, superior and inferior for each vertebra were also modeled. To define the gap between the articulating surfaces of the superior and inferior facets, three dimensional moving contact surfaces were also defined. This allows two bodies to come in contact with each other, which are not in direct contact as defined by the initial condition, when subjected to external loading conditions, and interact by transferring the load. Each node on the right and left inferior

facet of L1 was paired with a node on the adjacent superior surface of L2. Similarly, contact surfaces for the facets were created for L2-L3, L3-L4, L4-L5 and L5-S1. At an inclination of 45 degrees to the transverse plane, facet cartilage layers were attached (White and Panjabi, 1990).

Spinal Component	Element group	Element type
Cortical	1-6	ThreeD Solid
Cancellous	11-16	ThreeD Solid
Posterior Element	21-26	ThreeD Solid
Superior Endplate	30,32,34,36,38,40	ThreeD Solid
Inferior Endplate	31,33,35,37,39,41	ThreeD Solid
Annulus	41-45	ThreeD Solid
Nucleus	51-55	ThreeD Solid
Facet Cartilage	150-154	ThreeD Solid
Annular Outer Fiber	61,64,67,70,73	ThreeD Truss
Annular Middle Fiber	62,65,68,71,74	ThreeD Truss
Annular Inner Fiber	63,66,69,72,75	ThreeD Truss
Anterior Longitudinal Ligament	80-84	ThreeD Truss
Posterior Longitudinal Ligament	90-94	ThreeD Truss
Ligament Flavum Fiber	100-104	ThreeD Truss
Interspinous Ligament	110-114	ThreeD Truss
Intertransverse Ligament	120-124	ThreeD Truss
Supraspinous Ligament	130-134	ThreeD Truss
Capsular Ligament	140-144	ThreeD Truss

Table 1: Defining Spinal Components, Element Group and Element Type

2) Material Considerations

The material properties were taken from the literature (KIM, GOEL et al., SPINE VOL.16, No.3, 1991).

The vertebral, body the cancellous bone, the cortical bone and the posterior elements were modeled with linear isotropic elastic law. The material properties of cortical and cancellous bone, annulus, nucleus, endplates facet cartilages, and posterior elements were taken (as in table 2). Three layers of annular fibers were embedded in the annulus at an angle of $\pm 30^\circ$ with the horizontal plane. The modulus of elasticity of those fibers varied from the outermost layer to the innermost, where the highest modulus is at the outermost layer. The nucleus pulposus was modeled with linearly elastic law as a fluid element.

Material	Young's Modulus(MPa)	Poisson's ratio	Reference
Vertebra			
Cortical Bone	12000	0.3	Cassidy et al.(1989)
Cancellous Bone	100	0.2	Goulet et al.(1994)
Posterior elements	3500	0.25	Shirazi-Adi et al.(1986)
Endplate	24	0.4	Shirazi-Adi et al.(1986)

Table 2: Material Properties of the Spinal Components

The spinal ligaments and three layers of annular fibers were defined as nonlinear elastic because these structures are tensile load bearing only and the strain is equal to zero for all compressive loads. The material properties for all the three layers of the annular fibers were taken from the literature (Kumaresan et al., 2000). The three layers of annular fibers were taken from (Natarajan et al., 2000). The stress-strain relationships defined for the spinal ligaments and the annular fibers are given in the table 3 below.

Element Group	Structure	Material Type	Stress-Strain Relationship
41-45	Annular Fibers	Non-Linear Elastic	If $\epsilon < 0$; $E=0$ If $\epsilon > 0$; $E=500$ MPa
80-84	Anterior Longitudinal Ligament	Non-Linear Elastic	If $\epsilon < 12\%$; $E=15$ MPa If $\epsilon > 12\%$; $E=30$ MPa
90-94	Posterior Longitudinal Ligament	Non-Linear Elastic	If $\epsilon < 12\%$; $E=10$ MPa If $\epsilon > 12\%$; $E=20$ MPa
110-114	Interspinous Ligament	Non-Linear Elastic	If $\epsilon < 40\%$; $E=2$ MPa If $\epsilon > 40\%$; $E=8$ MPa
100-104	Ligament Flavum	Non-Linear Elastic	If $\epsilon < 25\%$; $E=5$ MPa If $\epsilon > 25\%$; $E=10$ MPa
140-144	Capsular Ligament	Non-Linear Elastic	If $\epsilon < 12\%$; $E=7$ MPa If $\epsilon > 12\%$; $E=30$ MPa

Values for Stress (ϵ) and Young's Modulus (E) were taken from the literature (annular fibers from Kumaresan et al., 2000 and Spinal ligaments from Natarajan et al., 2000.)

Table 3: The Stress-Stress Relationships Defined For the Spinal Ligaments and the Annular Fibers

3) Boundary Conditions

Boundary Conditions were required in order to constrain the model properly and to assure that the rigid body motion does not take place. Within the finite element model of the solid skeleton, the inferior surface of S1 vertebral body was constrained in all degrees of freedom including x, y, and z translation as well as x, y, and z rotations. This was accomplished by restraining every node of the inferior surface of S1 to have zero displacement during external loading. Thus L1-S1 intact lumbar spinal model was constructed using ADINA software and incorporating all the above conditions. The intact model is shown in Figure 8.

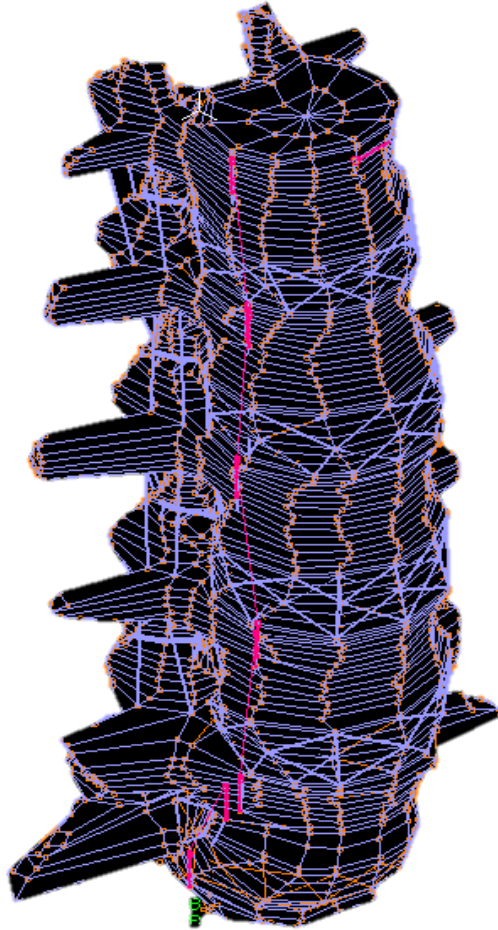


FIGURE 8: Case 0: Intact Model of Lumbar Spine

B) Finite Element Interbody Fused Model Construction:

Effect of Disc Degeneration:

The Intact finite element model having the healthy disc (grade-II) including the physiological parameters such as swelling pressure and strain dependent permeability and porosity of the disc tissues were modified to create models of Grade III, Grade IV, Grade V degenerated discs using the Thompson grading system. The geometry of the disc corresponding to the different grades of degeneration was simulated by decreasing the disc height and nucleus area. The disc height of an healthy disc =12 mm was reduced by 15%, 33% and 70% to represent mild, moderate, and severe disc degeneration conditions respectively. Nucleus area for the healthy and mild degeneration case was kept the same but this area was reduced by 67% for moderate and severe degeneration. Degeneration was simulated by decreasing the disc height and nucleus area by modifying the solid as well as porous material properties of the annulus ground substance and nucleus pulposus. Changes in porosity and permeability during the disc degeneration were also included in the model. The material properties and the geometrical parameters used for various components are as shown in the table below. Loss of disc height causes laxity in the ligaments surrounding the IVD and the embedded annular fibers. The decreased nucleus area was replaced with elements representing the annulus ground substance so as to maintain the same disc area. The biomechanical analysis of the normal and the three grades of degenerative discs were conducted in all the three directions to validate against the in vitro results presented by (Fujiwara et al., 2000). The results showed that the principle motions increased with mild degeneration and decreased as the motion further degenerated.

Model 1: L4/L5 Fused: Grades of Degeneration II, III, IV and V at L5/S1

Modifications were made in the intact model to simulate an immediate postoperative condition between the fusion and the endplates. In the finite element model, anterior disectomy was performed as follows: In the case of L4-L5 fusion, defined as **Model 1**(with grades of degeneration II, III, IV and V at lumbar segment L5/S1) the anterior longitudinal ligament of the L4-L5 motion segment was incised. The disc (nucleus, annulus, and annular fibers) was removed from the anterior edge to the posterior edge. The material property of the fusion was taken similar to the cortical bone having elastic modulus of 12 GPa and the Poisson's ratio of 0.3. The inferior endplate of the L4 vertebral body and the superior endplate of the L5 vertebral body were removed and then, the model was created by the use of finite element analysis. The fusion was performed to provide a rigid fixation between the inferior endplate of the L4 vertebra to the superior endplate of the L5 vertebra. Contact surfaces were used to connect vertebra and the endplates.

Model 2: L5/S1 Fused: Grades of Degeneration II, III, IV and V at L4/L5

In the case of L5-S1 fusion, defined as **Model 2**(with grades of degeneration II, III, IV and V at Lumbar segment L4/L5) in addition to the above procedure, the anterior longitudinal ligament of the motion segment L5-S1 was incised. The disc (nucleus, annulus, and annular fibers) was removed from the anterior edge to the posterior edge. The material property of the fusion was taken similar to the cortical bone having elastic modulus of 12 GPa and the Poisson's ratio of 0.3. The inferior endplate of the L5 vertebral body and the superior endplate of the S1 vertebral body were removed and then, the model was created by the use of finite element analysis. The fusion was performed to provide a rigid fixation between the inferior endplate of the L5 vertebra to the superior endplate of the S1 vertebra. Contact surfaces were used to connect vertebra and the endplates.

Model 3: L4/L5 Fused and L5/S1 Fused: Grades of Degeneration II, III, IV and V at L3/L4

In the case of L4-L5-S1 fusion, defined as **Model 3**(with grades of degeneration II, III, IV and V at Lumbar segment L3/L4) along with the above parameters, the anterior longitudinal ligaments of the motion segment L4-L5 as well as of the motion segment L5-S1 were incised. The disc (nucleus, annulus, and annular fibers) was removed from the anterior edge to the posterior edge. The material property of the fusion was taken similar to the cortical bone having elastic modulus of 12 GPa and the Poisson's ratio of 0.3. The inferior endplate of the L4 vertebral body and the superior endplate of the L5 vertebral body were removed and the inferior endplate of the L5 vertebral body and the superior endplate of the S1 vertebral body were removed and then, the model was created by the use of finite element analysis. The fusion was performed to provide rigid fixation between the inferior endplate of the L4 vertebra to the superior endplate of the L5 vertebra as well as the fusion was also performed to provide a rigid fixation at the center between the inferior endplate of the L5 vertebra to the superior endplate of the S1 vertebra. Contact surfaces were used to connect vertebra and endplates.

Thus three finite element models were created. The first model consisted of L1-S1 with L4-L5 fused. The second model consisted of L1-S1 with L5-S1 fused. And, the third model consisted of L1-S1 with both L4-L5 and L5-S1 fused.

C) Inclusion of Adjacent Segment Disc Degenerative disease

Modifications were made to simulate degenerated discs in the fused models with normal discs (as in the table below). The validated poroelastic finite element model of a healthy L4-L5 motion segment (Grade II) including important physiological parameters like swelling pressure and strain dependent permeability and porosity of the disc tissues was modified to create models of grade III, grade IV and grade V degenerated discs (Thompson grading system, which is a five tier MRI classification ranging from grade I (normal) to grade V (severe degeneration) Fujiwara et al., 2000). Degeneration was simulated by decreasing the disc height and nucleus area and by modifying the solid as well as porous material properties of the annulus ground substances and nucleus pulposus. During disc degeneration, changes in the permeability and porosity were also included in the model. The disc height (healthy disc height= 12mm) was reduced by 15%, 33% and 70% to represent mild, moderate and severe disc generation, respectively. Nucleus area was kept same for the healthy disc and mildly degenerated disc, but it was reduced by 67% to represent moderate and severe degeneration (Haefeli et al., 2006).

Table 4: Geometrical Parameters Used To Generate Degenerated Discs From Normal Disc (Grade II).

Degeneration Grade	Disc Height (% of Grade II disc height)	Nucleus Area (% of Grade II disc nucleus area)
Grade II	100	100
Grade III	85	100
Grade IV	67	33
Grade V	30	33

Table 5: Annulus Material Properties Assumed for Degenerative Discs

Degeneration Grade	Water Content (%)	Permeability			Porosity	Young's Modulus (MPa)	Poisson's Ratio	Initial Intradiscal Pressure (MPa)
		$m^4 N^{-1} s^{-1}$						
		K_x	K_y	K_z				
Grade II	65	1.68E-15	1.68E-15	1.64E-15	0.73	4.2	0.1	0.4
Grade III	60	1.23E-15	1.23E-15	1.7E-15	0.63	5.0	0.1	0.4
Grade IV	55	1.11E-15	1.11E-15	1.76E-15	0.59	5.0	0.1	0.2
Grade V	50	1.11E-15	1.11E-15	1.76E-15	0.57	2.0	0.1	0.2

Table 6: Nucleus Material Properties Assumed for Degenerative Discs

Degeneration Grade	Water Content (%)	Permeability			Porosity	Young's Modulus (MPa)	Poisson's Ratio	Initial Intradiscal Pressure (MPa)
		$m^4 N^{-1} s^{-1}$						
		K_x	K_y	K_z				
Grade II	85	2.13E-15	2.13E-15	1.45E-15	0.83	1.0	0.4	0.4
Grade III	80	1.63E-15	1.63E-15	1.47E-15	0.73	1.2	0.35	0.4
Grade IV	78	1.59E-15	1.59E-15	1.49E-15	0.72	1.2	0.35	0.2
Grade V	76	1.59E-15	1.59E-15	1.49E-15	0.71	1.2	0.35	0.2

D) Loading Conditions

In all the above cases, (L1-S1 intact, L4-L5 fused, L5-S1 fused, and both L4-L5 and L5-S1 fused with normal and degenerated disc conditions), a pre-compressive loading of 400N followed by 8Nm flexion, 6Nm extension, 6Nm lateral bending and 4Nm torsion was applied at the two points, one on the anterior most side and on the posterior most side of the superior surface of L1 vertebral body in the opposite directions to simulate bending moment. The moment load was applied over fifty time steps. The force was applied in the normal model and the degrees of motion of the lumbar spine as well as the segmental motion for each loading were noted. The models were then fused and the motions for the lumbar spine as well as the segmental motion were taken keeping the forces, same as that in the normal model. But, the motions were less than the normal model. In order to match the motion of the fused model with the normal model, the forces were increased and applied on the fused model. The forces were increased to an extent till the motions of fused as well as normal model were similar. The forces were decided by trial and error method. Data will be collected on the last loading cycle. Responses due to flexion, extension, bending and torsion were obtained for each vertebra in relation to the adjacent segment. The inferior surface of S1 vertebra was fixed in all three degrees of freedom. The data was analyzed using analysis of variance in order to estimate correlation. The percentage changes in the disc motion (L4-L5, in case of one level fusion, L5-S1 in case of one level fusion, and L4-L5 and L5-S1 (both) in the case of two level fusions) were calculated in each case and compared to the corresponding values of the L1-S1 intact model. In all the cases studied here, the loading cases were used to find out the motion of the adjacent segments due to fusion.

4) Validating the model:

Validation studies form the crucial link between the development of the finite element model and its final intended use. Validation is done to ensure that the model behaves like the real structure under conditions of intended external force application. Loading and boundary conditions applied during experimental research are used and the finite element model output is matched with the experimental results. After validation, the model can be used to predict behavior of the spine in situations in which the model has not been validated.

5) Results

A. Single level Fusion

L4/L5 Fused (Model 1):

The analysis of the model showed that when single level was fused, the motion considerably decreased at the fused level compared to the intact model. The models representing a single level fusion with a graft in a normal spine (Elastic modulus of cortical bone= 12GPa) at L4/L5 predicted an increase in motion under all types of moment load at the adjacent segment superior and inferior to the fusion level. The percentage change in motion of the spine with the fused motion segment with respect to the intact motion segment was calculated as follows:

$$\text{Percentage change in motion: } \frac{\text{Angle of fused disc} - \text{Angle of Intact disc}}{\text{Angle of intact disc}} * 100$$

L5/S1 Fused (Model 2):

The analysis of the model showed that when single level was fused, the motion considerably decreased at the fused level compared to the intact model. The models representing a single level fusion with a graft in a normal spine (Elastic modulus of cortical bone= 12GPa) at L5/S1 predicted an increase in motion under all types of moment load at the adjacent segment superior to the fusion level. The percentage change in motion of the spine with the fused motion segment with respect to the intact motion segment was calculated as follows:

$$\text{Percentage change in motion: } \frac{\text{Angle of fused disc} - \text{Angle of Intact disc}}{\text{Angle of intact disc}} * 100$$

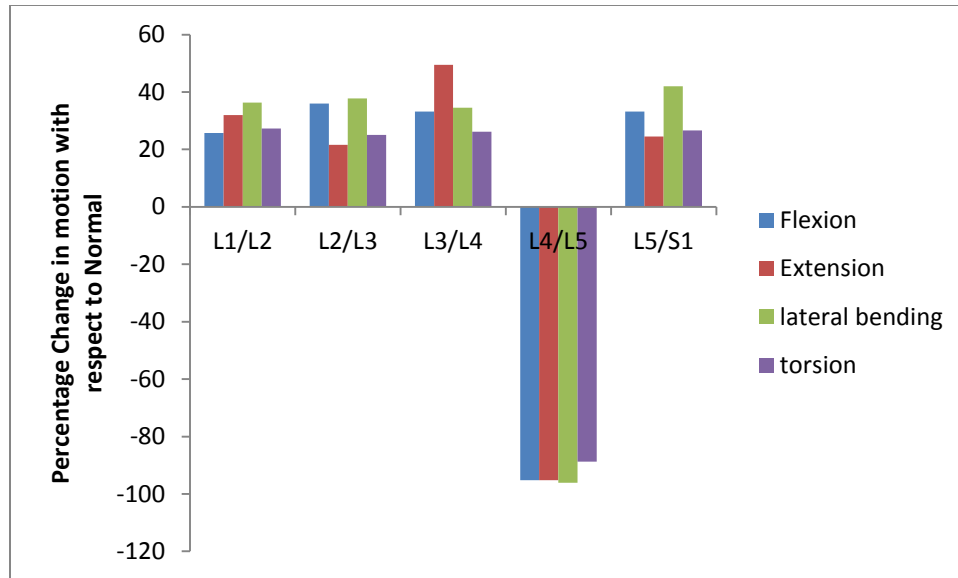
1) Effect of fusion on the segment adjacent to the fusion

i) Normal Adjacent Segment:

L4/L5 Fused (Model 1):

Model 1 A: L4/L5 fused with grade II at L5/S1

When L4/L5 was fused, the motion at the segment L4/L5 was reduced by more than 88% under each moment loading. This loss of segmental motion was compensated by the segments superiorly and inferiorly adjacent to the fusion under all types of moment load. The larger increase in motion at the segment superior to fusion was seen under the flexion and extension moment load, and the larger increase in motion at the segment inferior to fusion was seen under lateral bending and torsion. The maximum increase in motion by 49.9% was seen at the segment superior to the fusion (L3/L4 segment) under extension moment load. The minimum increase in motion by 26.6% was seen at the segment inferior to the fusion (L5/S1) under torsion moment load. The increase in motion by 42.03% was largest under lateral bending at the segment inferior to the fusion level. The largest increase in motion by 35.95% under flexion moment load was seen at the segment (L2/L3) superior to the superiorly adjacent segment to the fusion level. The superior most segment (L1/L2) showed largest increase in motion under torsion moment load (Chow et al., in 1996) showed an evidence of increase in motion in flexion and extension in all the segments above and below the fused segment (L4/L5). The graph shown below is motion at the segments of the lumbar spine when L4/L5 fused and grade II at L5/S1, under all types of moment loading.



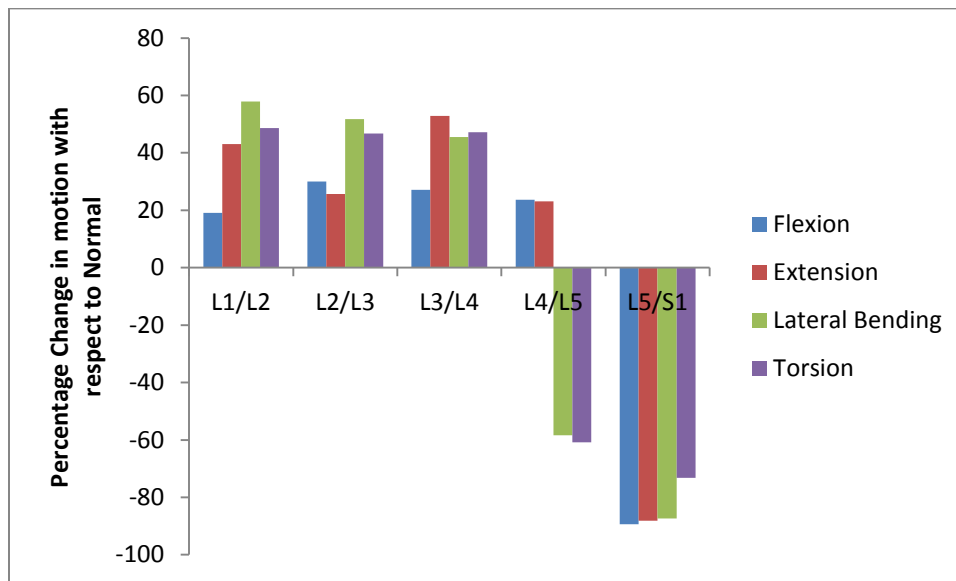
Graph 1: motion at the segments of the lumbar spine when L4/L5 fused and grade II at L5/S1

L5/S1 Fused (Model 2):

Model 2 A: L5/S1 fused with grade II at L4/L5

When L5/S1 was fused, the motion at segment L5/S1 was decreased by more than 72% under each moment loading. This loss of segmental motion was compensated by the segment superiorly adjacent to the fusion. The motion at the adjacent segment superior to the fusion(L4/L5) was decreased by 58.36% under lateral bending. The motion at the adjacent segment superior to the fusion level(L4/L5) was decreased by 60.85% under torsion moment load. The maximum increase in motion through the lumbar spine was seen at the superior most level of the lumbar spine (L1/L2) by 57.88% and 48.63% under lateral bending and torsion moment load, respectively. Also, the maximum increase in motion was seen at the segment superior to the superiorly adjacent segment to the

fusion(L3/L4) by 52.81% under extension moment load and under flexion maximum increase was seen at the second most superior level of the lumbar spine (L2/L3) by 29.9%. The graph shown below is motion at the segments of the lumbar spine when L5/S1 fused and grade II at L4/L5, under all moment loading.



Graph 2: motion at the segments of the lumbar spine when L5/S1 fused and grade II at L4/L5

ii) Adjacent Segmented Degenerated Disease:

L4/L5 Fused (Model 1 B):

Model 1 B: L4/L5 fused with grade III at L5/S1

The analysis again showed that at the level of fusion, the motion decreased and the motion at the segments adjacent to the fusion increased to compensate the loss of the segmental motion at fused segment L4/L5. The model representing a single level fusion at (L4/L5) with a normal motion segments at all the levels and grade III of degeneration at L5/S1 predicted an increase in motion under all types of moment load at the adjacent segment superior (L3/L4) and inferior (L5/S1) to the fusion level as compared to the intact model. However, the larger increase (by more than 30%) was seen at the adjacent

segment superior to the fusion level under all types of moment load. There is a smaller increase in motion (by less than 24%) due to the inclusion of grade III of degeneration at the segment inferiorly adjacent to the fusion level, L5/S1. The changes in motion after lumbar fusion were calculated by comparing the motions in the intact motion segment with the corresponding motions after anterior lumbar fusion including the effect of disc degeneration at the adjacent segment. The maximum increase in motion was seen at superiorly adjacent segment L3/L4 (49.39%) and the superior most segments L1/L2 of the lumbar spine (51.53%) under extension moment load and lateral bending, respectively. The maximum increase in motion under flexion moment load was seen at the second most superior segment (L2/L3) of the lumbar spine by 42.7%. Also, the maximum increase in motion under the torsion moment load was seen at the superior most segments (L1/L2) by 31.9%.

Model 1 C: L4/L5 fused with grade IV at L5/S1

The analysis again showed that at the level of fusion, the motion decreased and the motion at the segments adjacent to the fusion increased to compensate the loss of the segmental motion at fused segment L4/L5. The model representing a single level fusion at (L4/L5) with a normal motion segments at all the levels and grade IV of degeneration at L5/S1 predicted an increase in motion under all types of moment load at the adjacent segment superior (L3/L4) and inferior (L5/S1) to the fusion level as compared to the intact model. But, the motion increased only at the superiorly adjacent segment to the fusion.

The maximum increase in motion at the superior adjacent segment L3/L4 (57.35%) was observed under extension moment load. Under lateral bending and torsion moment load,

maximum increase in motion was observed at superior most segments L1/L2 by 60% and 40.8%, respectively. Under flexion, the maximum increase in motion through the lumbar spine was seen at the second most superior segment of the lumbar spine by 57%. Moreover, due to the inclusion of ASDD of grade IV at L5/S1, there is a loss of motion at the L5/S1 segment under all types of moment load except extension. Motion at the inferior adjacent segment (L5/S1) to the fusion decreased by 16.26% and 14.87% under lateral bending and torsion moment load, respectively.

Case 1 D: L4/L5 fused with grade V at L5/S1

The analysis again showed that at the level of fusion, the motion decreased and the motion at the segments adjacent to the fusion increased to compensate the loss of the segmental motion at fused segment L4/L5. The model representing a single level fusion at (L4/L5) with a normal motion segments at all the levels and grade V of degeneration at L5/S1 predicted an increase in motion under all types of moment load at the adjacent segment superior (L3/L4) to the fusion level as compared to the intact model. The motion rather decreased at the segment inferiorly adjacent to the fusion.

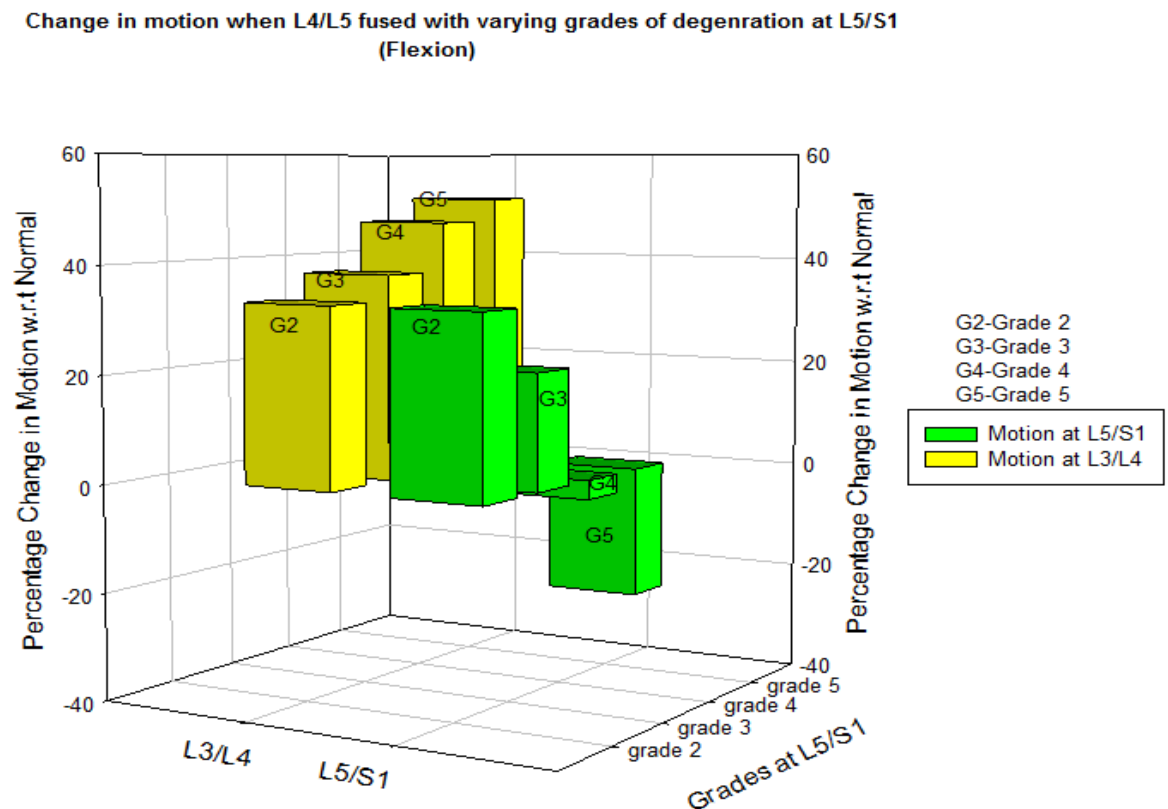
The increase in motion at L3/L4 (77.01%) and (51.28%) was observed under extension and flexion moment load, respectively. Under lateral bending and torsion moment load, maximum increase in motion was observed at superior most segments L1/L2 by 65.4% and 42.3%, respectively. Under flexion, the maximum increase in motion through the lumbar spine was seen at the second most superior segment of the lumbar spine by 74.3%.

Moreover, due to the inclusion of ASDD of grade V at L5/S1, there is a loss of motion at the L5/S1 segment under all types of moment loads.. The maximum decrease in motion at

L5/S1 by 35.46% was observed under lateral bending. The minimum decrease in motion by 14.83% was seen under extension moment load.

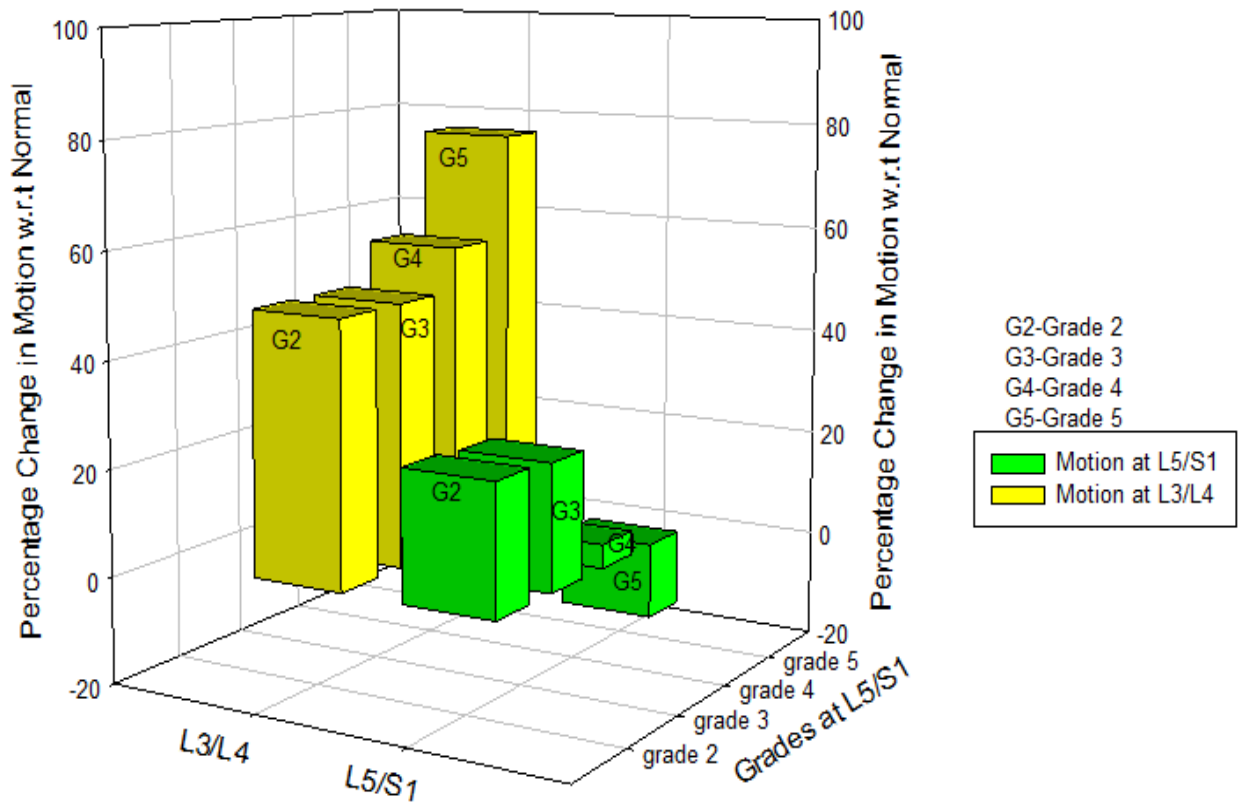
The analysis showed that the motion at the fused level, as well as at the level were disc degeneration has been simulated decreases considerably as compared to the normal model. The analysis also showed that the motion decreases as the grades of degeneration increases (i.e. from mild to severe).

The graphs for all the grades of degeneration under all the moment loads were plotted.



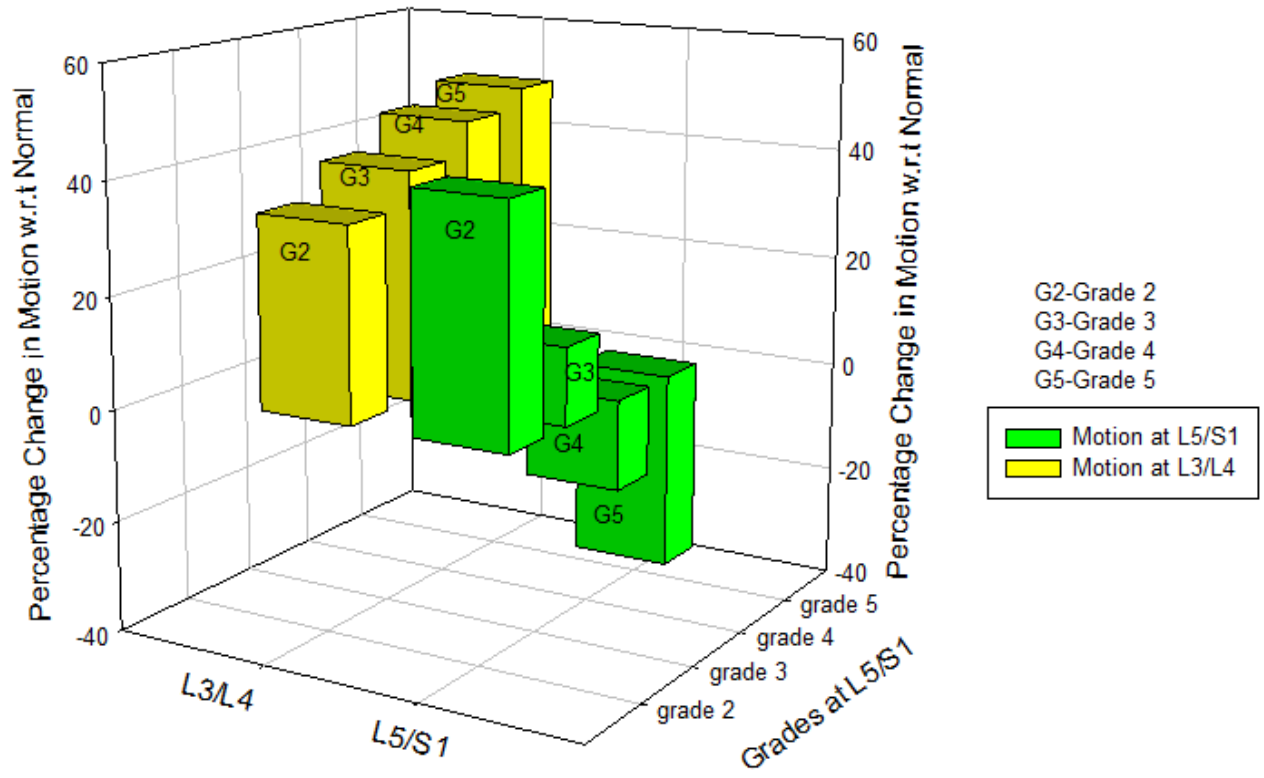
Graph 3: Change in motion when L4/L5 with varying grades of degeneration at L5/S1 under flexion

Change in motion when L4/L5 fused with varying grades of degeneration at L5/S1
(Extension)



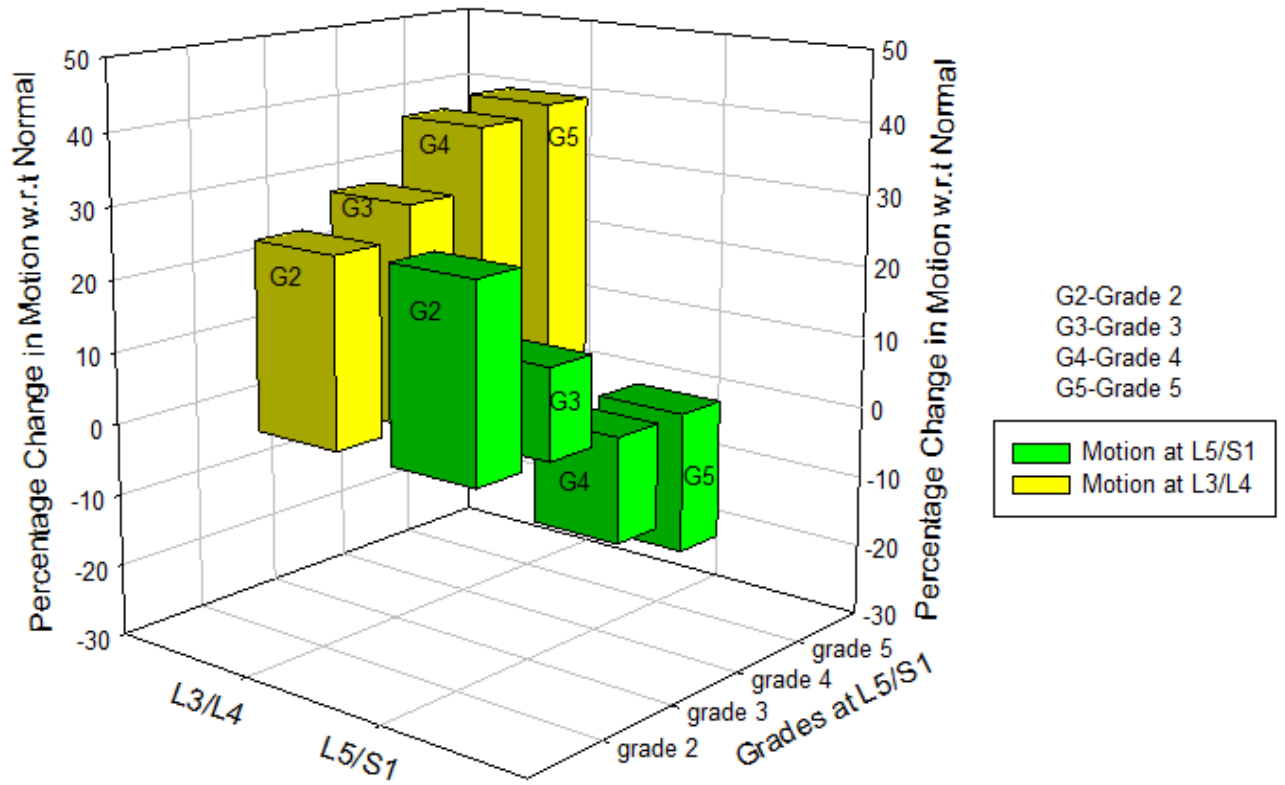
Graph 4: Change in motion when L4/L5 with varying grades of degeneration at L5/S1 under Extension

Change in motion when L4/L5 fused with varying grades of degeneration at L5/S1
(Lateral Bending)



Graph 5: Change in motion when L4/L5 with varying grades of degeneration at L5/S1 under Lateral Bending

Change in motion when L4/L5 fused with varying grades of degeneration at L5/S1
(Torsion)



Graph 6: Change in motion when L4/L5 with varying grades of degeneration at L5/S1 under Torsion

L5/S1 Fused (Model 2 B):

Model 2 B: L5/S1 fused with grade III at L4/L5

The analysis again showed that at the level of fusion, the motion decreased and the motion at the segments adjacent to the fusion increased to compensate the loss of the segmental motion at fused segment L5/S1. The model representing a single level fusion at (L5/S1) with a normal motion segments at all the levels and grade III of degeneration at L4/L5 predicted an increase in motion under all types of moment load at the segment (L3/L4) superior to the superiorly adjacent segment to the fusion level as compared to the intact model. The changes in motion after lumbar fusion were calculated by comparing the motions in the intact motion segment with the corresponding motions after anterior lumbar fusion including the effect of disc degeneration at the adjacent segment. The analysis also showed an evidence of decrease in motion at the adjacent segment having grades of degeneration. There was decrease in motion at L4/L5 under all moment loads except torsion (increase by 14.98%). But, this loss of segmental motion was compensated by all the segments above L4/L5, mainly, L2/L3 and L3/L4. The largest increase in motion was seen at the second superior most segments (L2/L3) under all types of moment load. The motion at those two segments increased by more than 41% under each moment loading.

Model 2 C: L5/S1 fused with grade IV at L4/L5

The analysis again showed that at the level of fusion, the motion decreased and the motion at the segments adjacent to the fusion increased to compensate the loss of the segmental motion at fused segment L5/S1. The model representing a single level fusion at (L5/S1) with a normal motion segments at all the levels and grade IV of degeneration

at L4/L5 predicted an increase in motion under all types of moment load at the segment (L3/L4) superior to the superiorly adjacent segment to the fusion level as compared to the intact model. Moreover, due to the inclusion of ASDD of grade IV at L4/L5, there is a loss of motion at the L4/L5 segment. The maximum decrease in motion at L4/L5 by 47.25% was observed under lateral bending. The minimum decrease in motion by 24.36% was seen under flexion moment load. The loss of the segmental motion at L4/L5 due to inclusion of ASDD and at L5/S1 due to fusion was compensated by all motion segments above those two. Under flexion, the largest increase in motion was seen at the second most superior segment L2/L3 by 61.6%. The largest increase in motion was seen at the superior most segment (L1/L2) of the spine under all types of moment load except flexion. The motion at all those segments except L4/L5 and L5/S1 increased more than 33% under each moment loading.

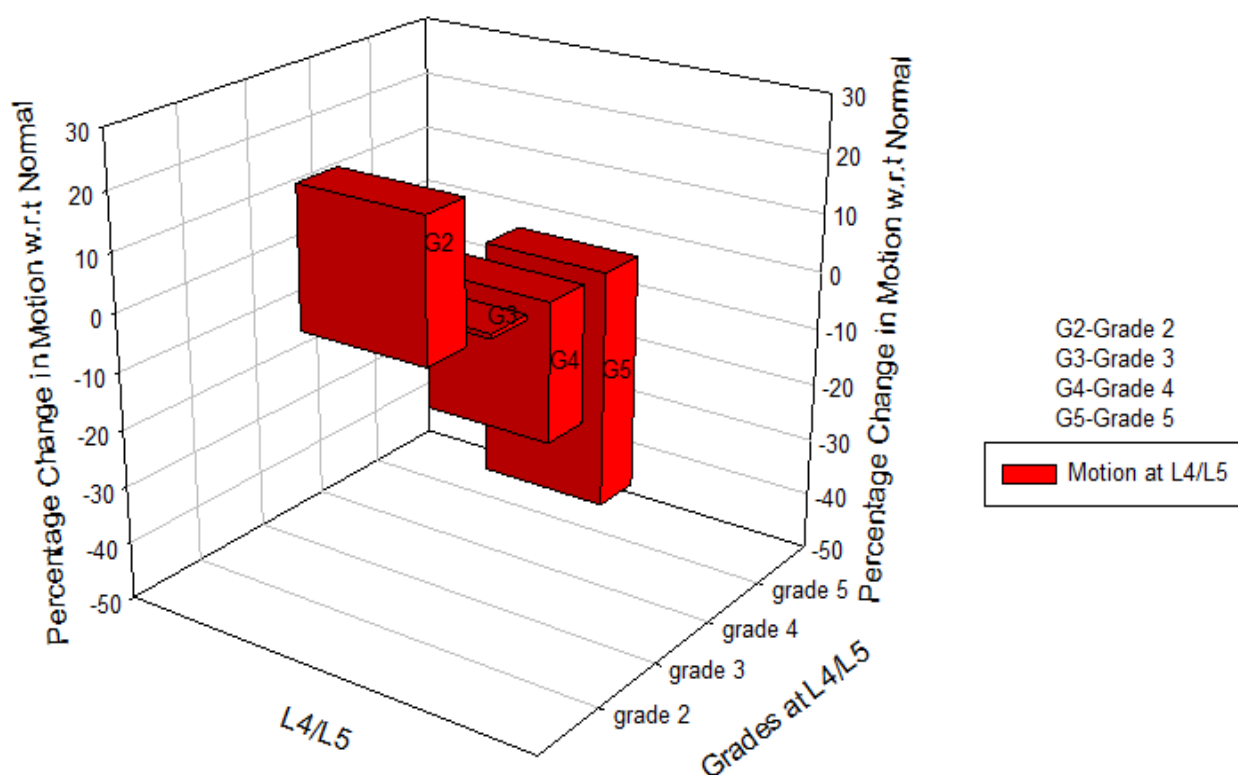
Model 2 D: L5/S1 fused with grade V at L4/L5

Similar results were seen as all the above models, when this model was studied. The analysis again showed that at the level of fusion, the motion decreased and the motion at the segments adjacent to the fusion increased to compensate the loss of the segmental motion at fused segment L5/S1. The model representing a single level fusion at (L5/S1) with a normal motion segments at all the levels and grade V of degeneration at L4/L5 predicted an increase in motion under all types of moment load at the segment (L3/L4) superior to the superiorly adjacent segment to the fusion level as compared to the intact model. Due to the inclusion of ASDD of grade IV at L4/L5, there is a loss of motion at the L4/L5 segment. The maximum decrease in motion at L4/L5 by 56.6% was observed under lateral bending. The minimum decrease in motion by 5.4% was seen under torsion

moment load. The loss of the segmental motion at L4/L5 due to inclusion of ASDD and at L5/S1 due to fusion was compensated by all motion segments above those two. Under flexion, the largest increase in motion was seen at the second most superior segment L2/L3 by 41.4%. The largest increase in motion was seen at the superior most segment (L1/L2) of the spine under all types of moment load except flexion. The motion at all those segments except L4/L5 and L5/S1 increased more than 27.9% under each moment loading.

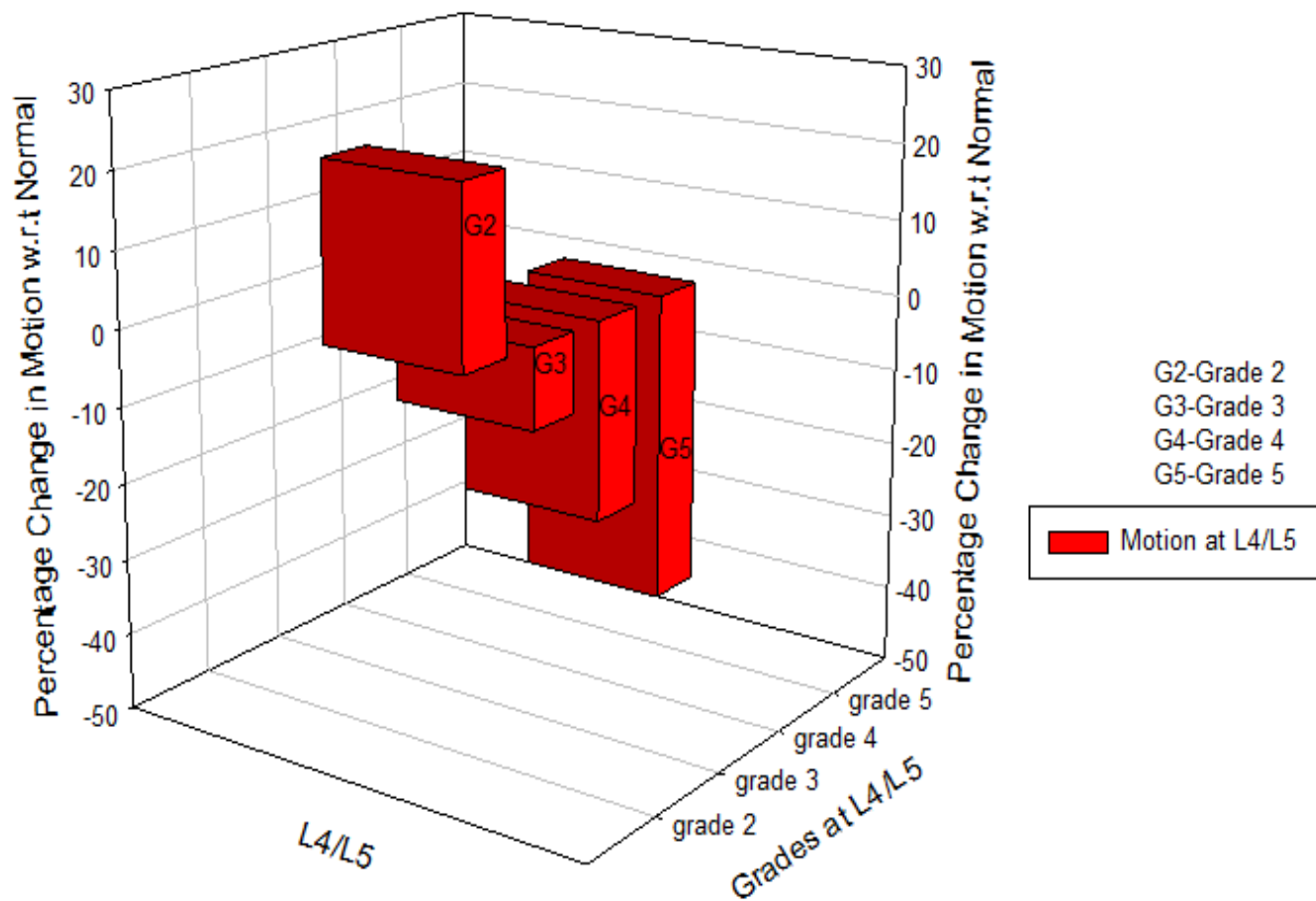
The graphs for all the grades of degeneration under all the moment loads were plotted.

Change in motion when L5/S1 fused with varying grades of degeneration at L4/L5
(Flexion)



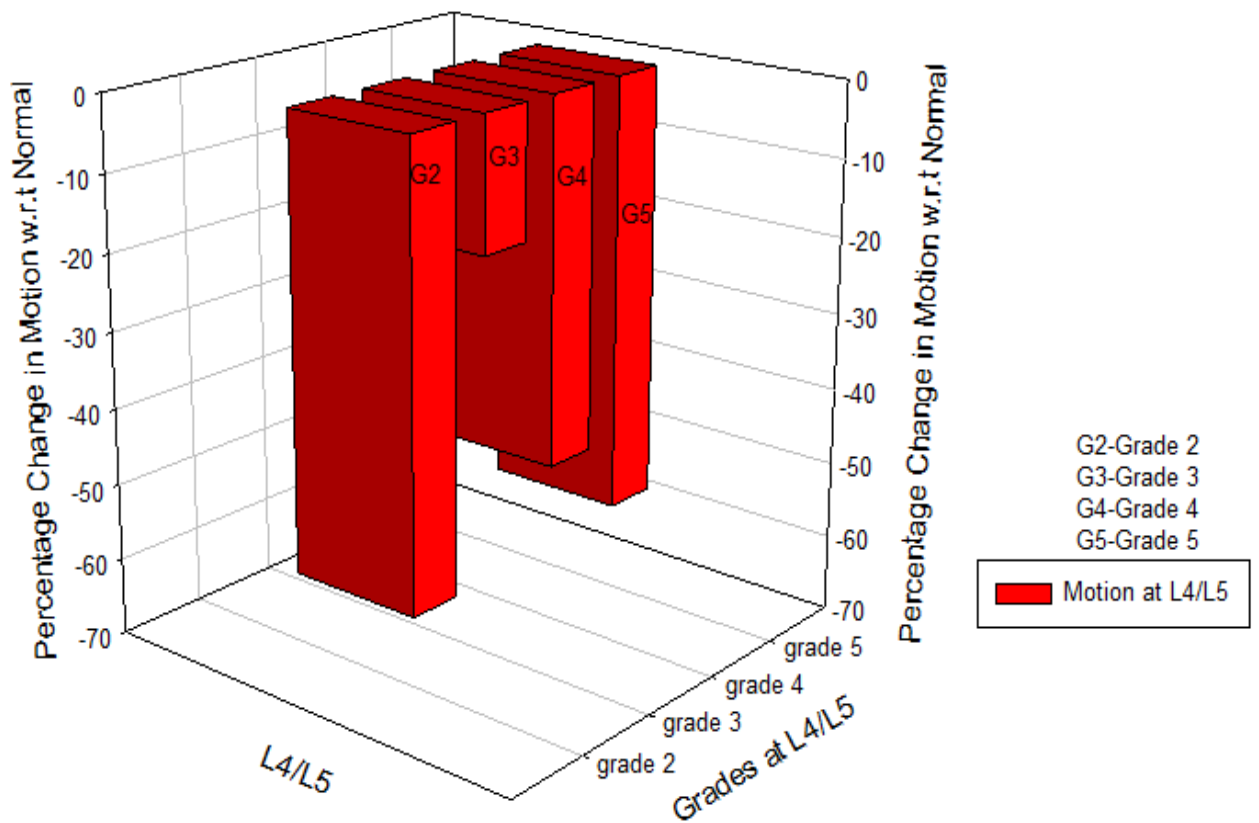
Graph 7: Change in motion when L5/S1 fused with varying grades of degeneration at L4/L5 under Flexion

Change in motion when L5/S1 fused with varying grades of degeneration at L4/L5
(Extension)



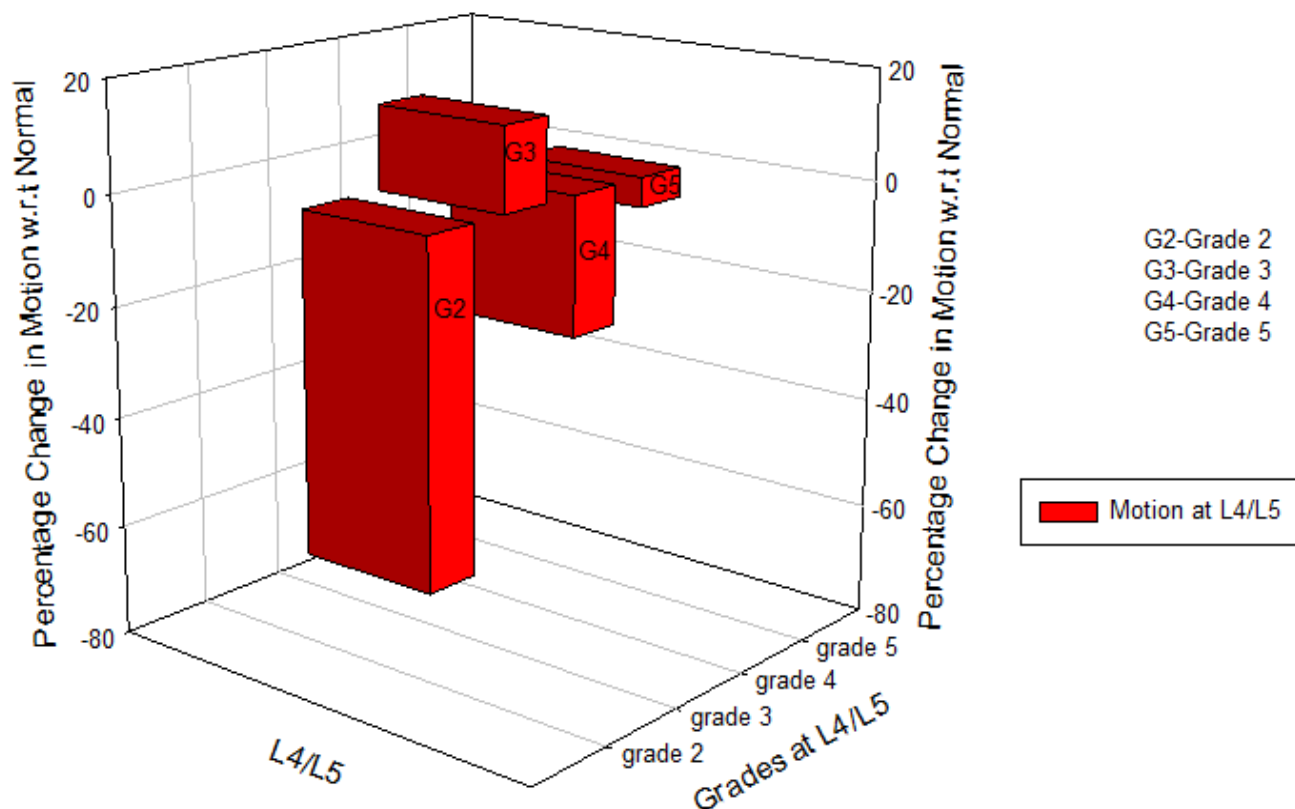
Graph 8: Change in motion when L5/S1 fused with varying grades of degeneration at L4/L5 under extension

Change in motion when L5/S1 fused with varying grades of degeneration at L4/L5
(Lateral Bending)



Graph 9: Change in motion when L5/S1 fused with varying grades of degeneration at L4/L5 under Lateral Bending

Change in motion when L5/S1 fused with varying grades of degeneration at L4/L5
(Torsion)



Graph 10: Change in motion when L5/S1 fused with varying grades of degeneration at L4/L5 under torsion

B. Double level Fusion

L4/L5/S1 fused (Model 3):

The analysis of the model showed that when double level was fused, the motion considerably decreased at the fused level compared to the intact model. The models representing a double level fusion with a graft in a normal spine (Elastic modulus of cortical bone= 12GPa) at L4/L5 and L5/S1 predicted an increase in motion under all types of moment load at the adjacent segment superior to the fusion level. The percentage change in motion of the fused motion segments with respect to the intact motion segment was calculated as follows:

$$\text{Percentage change in motion: } \frac{\text{Angle of fused disc} - \text{Angle of Intact disc}}{\text{Angle of intact disc}} * 100$$

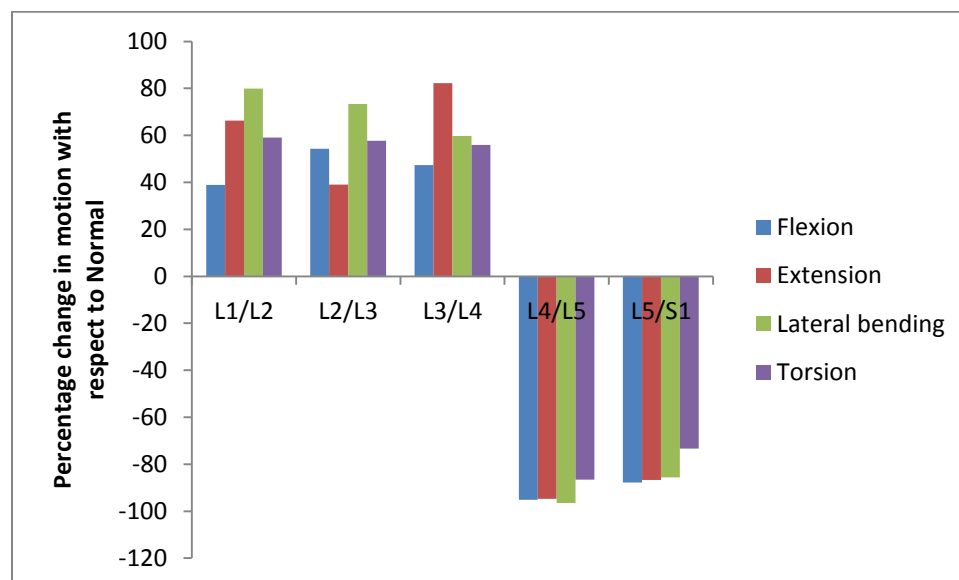
1) Effect of fusion on the segment adjacent to the fusion

i) Normal Adjacent Segment:

L4/L5/S1 Fused (Model 3):

Model 3 A: L4/L5/S1 fused with grade II at L3/L4

When L4/L5/S1 was fused, the motion at those two segments decreased considerably by more than 73% under each loading. The loss of segmental motion was compensated by the segments superiorly adjacent to the fusion. The motion increased at the segments above the fusion by more than 38% to 82%. There was increase in motion at the segment superiorly adjacent to the fused levels under all types of moment load. The largest increase in motion under lateral bending and torsion moment load was seen at superior most level L1/L2 of the lumbar spine by 79.8% and 59%, respectively. The largest increase in motion under flexion was seen at the second superior most level of lumbar spine by 54%. The largest increase in motion under extension was seen at L3/L4 by 82%.



Graph 11: motion at the segments of the lumbar spine when L4/L5/S1 fused and grade II at L3/L4

ii) Adjacent Segmented Degenerated Disease:

L4/L5/S1 fused (Model 3):

Model 3 B: L4/L5/S1 fused with grade III at L3/L4

The analysis again showed that at the level of fusion, the motion decreased and the motion at the segments adjacent to the fusion increased to compensate the loss of the segmental motion at fused segment L4/L5/S1. The model representing a double level fusion with a graft at (L4/L5) and (L5/S1) and grade III of degeneration at L3/L4 predicted an increase in motion under all types of moment load at segment (L3/L4) superior to the fusion compared to the normal model. The changes in motion after lumbar fusion were calculated by comparing the motions in the intact motion segment with the corresponding motions after anterior lumbar fusion including the effect of disc degeneration at the adjacent segment. The motion at the adjacent segment L3/L4 having grade III at that segment, increased from 4% to not more than 29%. The increase in motion at L3/L4 was minimum in comparison to the increase in motion at L1/L2 and L2/L3 under each loading condition. The maximum increase in motion under flexion and torsion moment load was seen at the second most superior segment (L2/L3) by 119% and 87.8%, respectively. The maximum increase in motion under extension and lateral bending moment load was seen at the superior most segment (L1/L2) by 106.5% and 117%, respectively. The analysis showed that the motion at the fused level, as well as at the level where disc degeneration has been simulated, decreases considerably as compared to the normal model. The analysis also showed that the motion at the segment where degeneration is simulated decreases as the grades of degeneration increases (i.e. from mild to severe).

Case 3 C: L4/L5/S1 fused with grade IV at L3/L4

The analysis again showed that at the level of fusion, the motion decreased and the motion at the segments adjacent to the fusion increased to compensate the loss of the segmental motion at fused segment L4/L5/S1. The model representing a double level fusion with a graft at (L4/L5) and (L5/S1) and grade IV of degeneration at L3/L4 predicted an increase in motion under all types of moment load at segment (L3/L4) superior to the fusion compared to the normal model. The changes in motion after lumbar fusion were calculated by comparing the motions in the intact motion segment with the corresponding motions after anterior lumbar fusion including the effect of disc degeneration at the adjacent segment. The motion at the superiorly adjacent segment to the fusion (L3/L4) having grade IV at that segment, increased by 9.17% under extension and by 56% under torsion moment load. The motion decreased at L3/L4 under flexion moment load and lateral bending. The maximum increase in motion under flexion and torsion moment load was seen at second most superior segment (L2/L3) by 140% and 80.5%, respectively. The maximum increase in motion under extension and lateral bending moment load was seen at the superior most segment (L1/L2) by 134% and 130.8%, respectively.

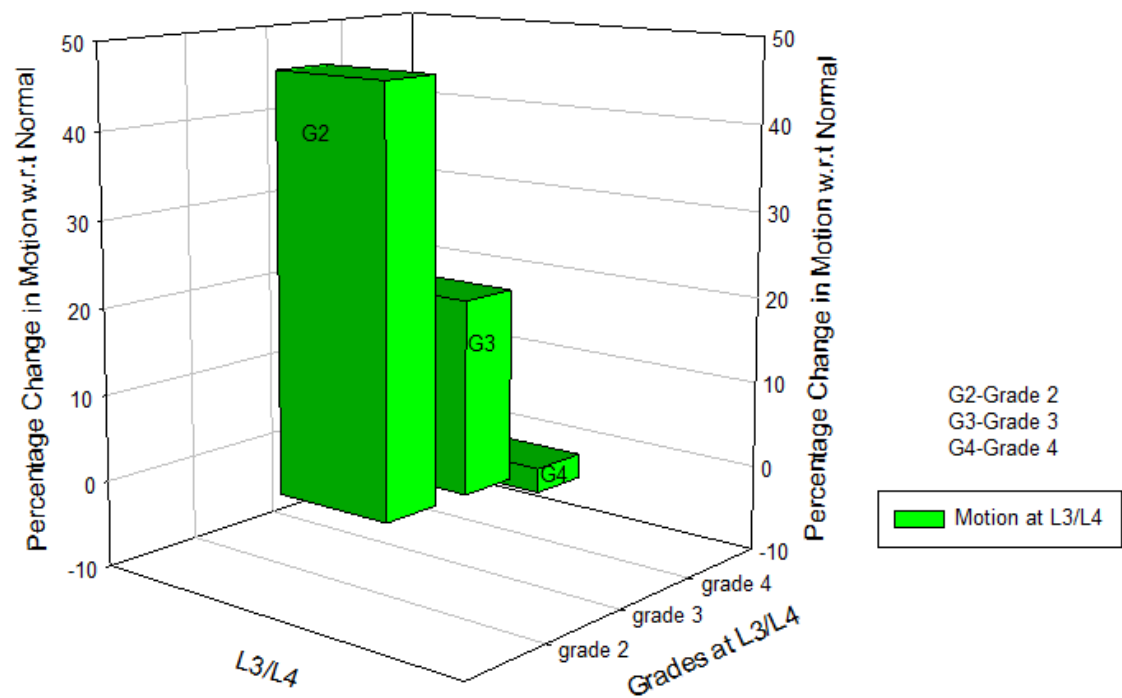
Case 3 D: L4/L5/S1 fused with grade V at L3/L4

Grade V is generally not seen at the segment L3/L4, so the model having graded V at L3/L4 was not studied.

.

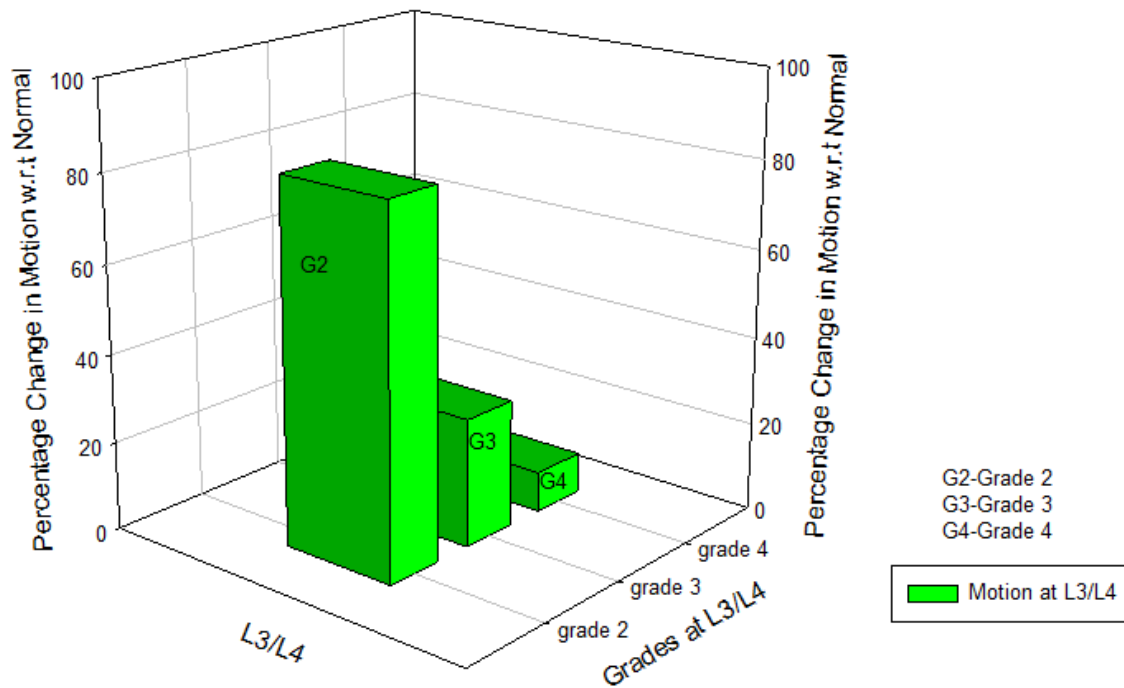
The graphs of all the grades of degeneration under each moment loads were plotted

Change in Motion when L4-L5-S1 fused with grades of degeneration at L3/L4 (Flexion)



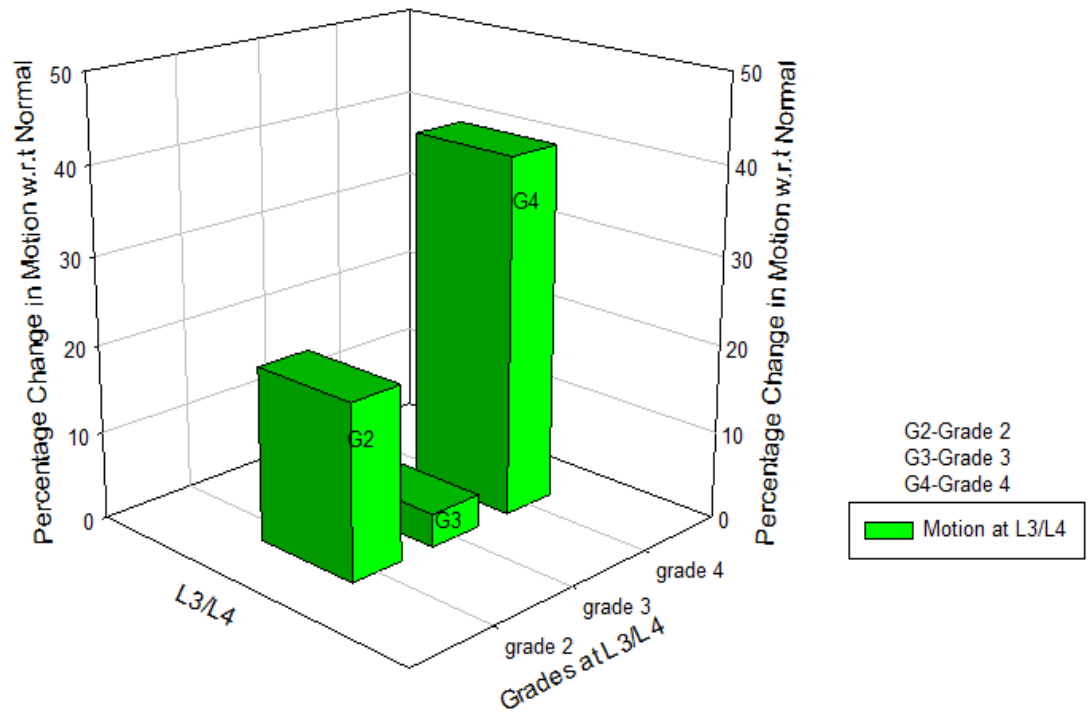
Graph 12: Change in motion when L4/L5/S1 were fused with grades of degeneration at L3/L4 under flexion

Change in Motion when L4-L5-S1 fused with grades of degeneration at L3/L4 (Extension)



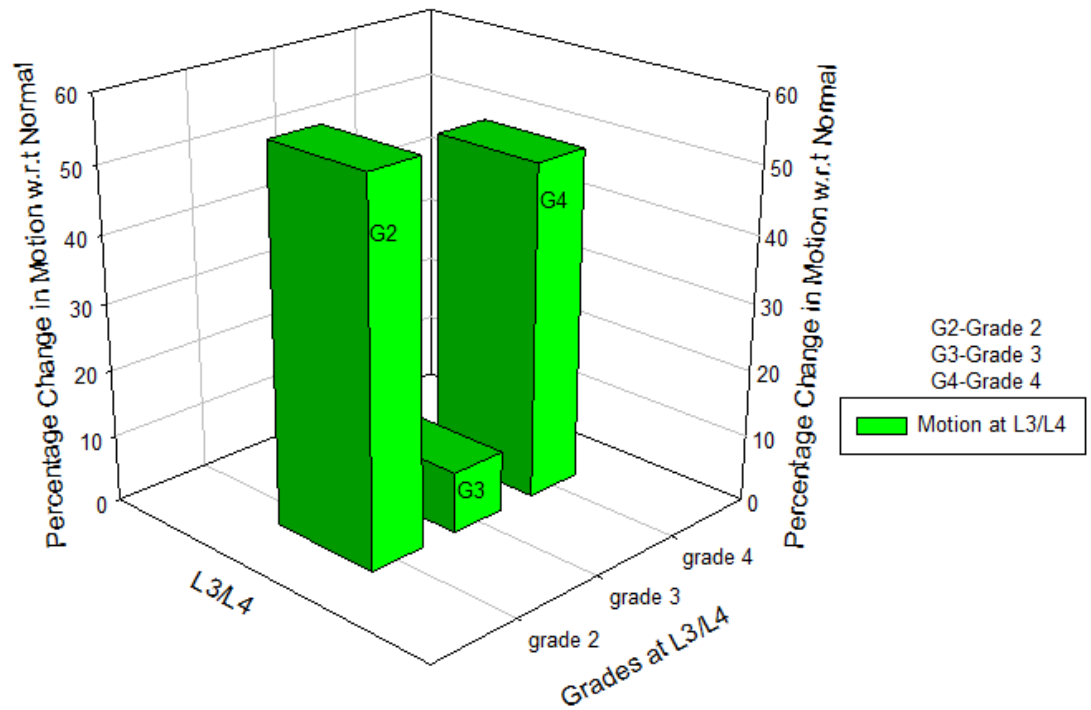
Graph 13: Change in motion when L4/L5/S1 were fused with grades of degeneration at L3/L4 under extension

Change in Motion when L4-L5-S1 fused with grades of degeneration at L3/L4 (Lateral Bending)



Graph 14: Change in motion when L4/L5/S1 were fused with grades of degeneration at L3/L4 under lateral bending

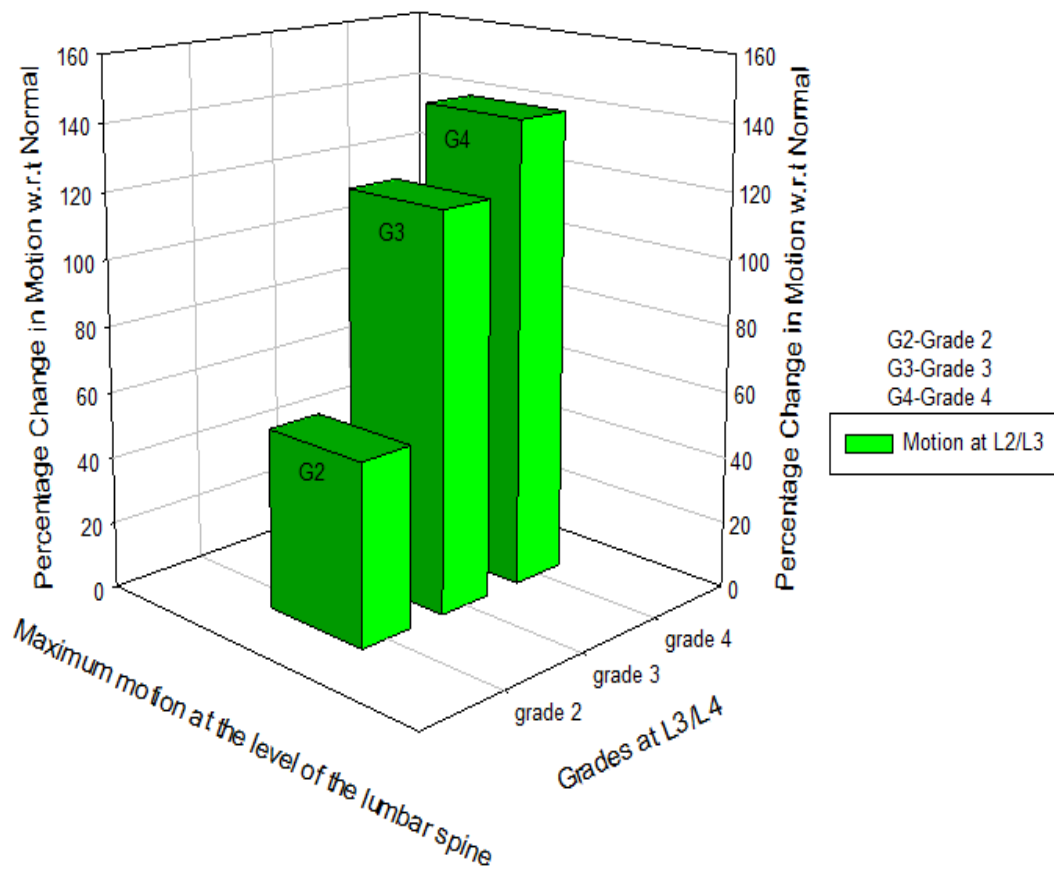
Change in Motion when L4-L5-S1 fused with grades of degeneration at L3/L4 (Torsion)



Graph 15: Change in motion when L4/L5/S1 were fused with grades of degeneration at L3/L4 under torsion

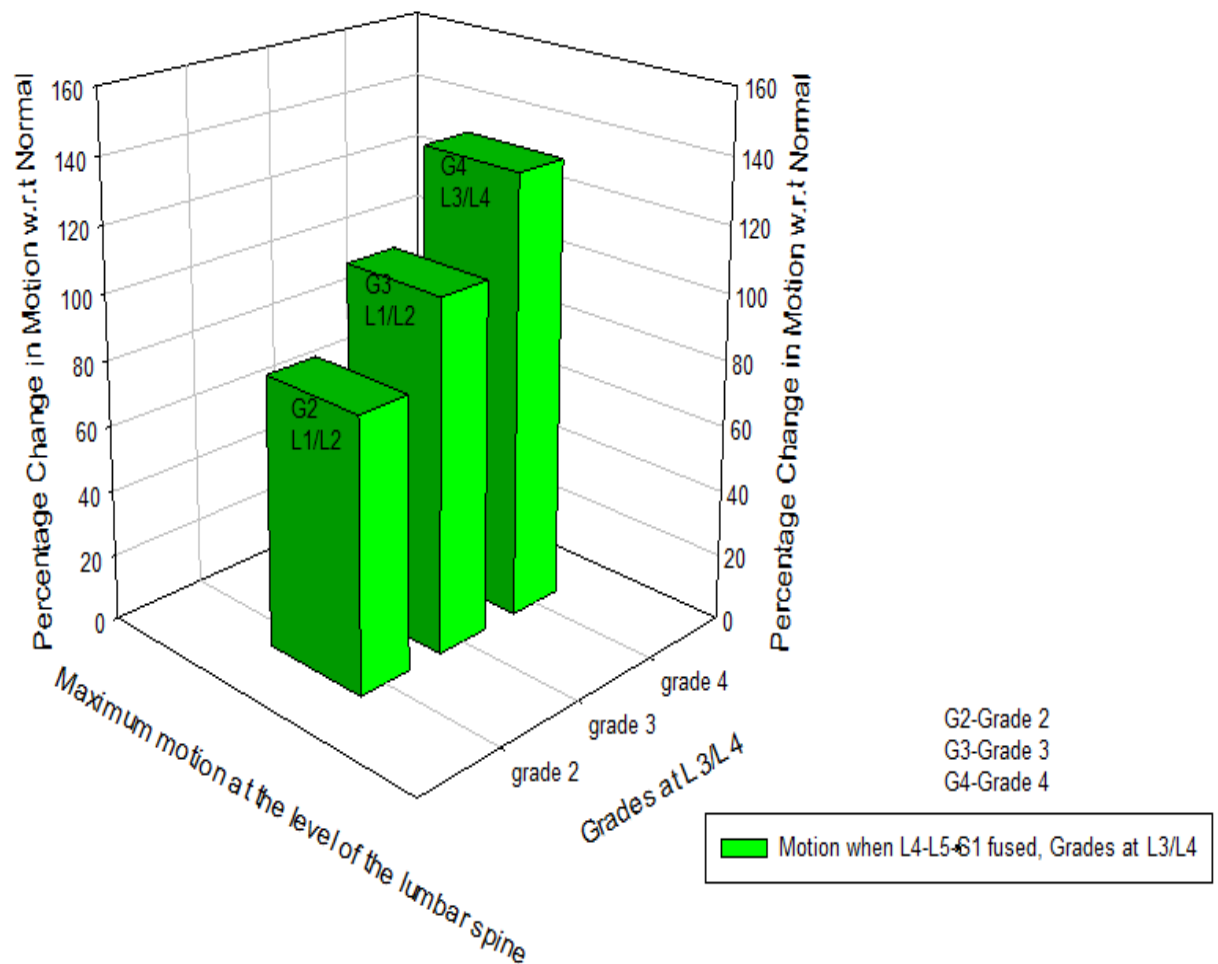
The graphs were also plotted with maximum increase in motion at through the lumbar spine when L4/L5/S1 fused and grades of degeneration at L3/L4

Change in Motion when L4-L5-S1 fused with grades of degeneration at L3/L4 (Flexion)



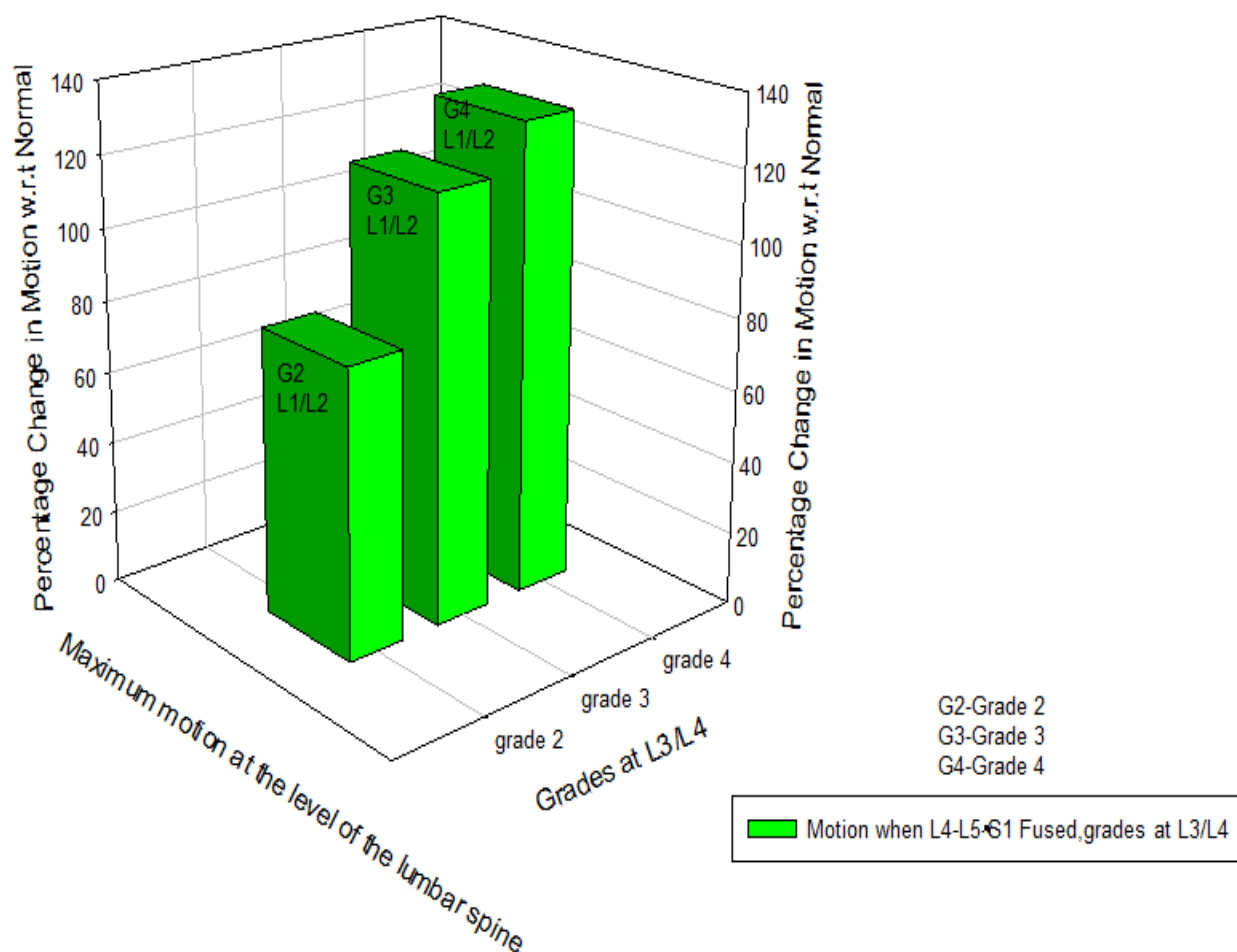
Graph 16: Maximum Change in motion at the level of lumbar spine under flexion

Change in Motion when L4-L5-S1 fused with grades of degeneration at L3/L4 (Extension)



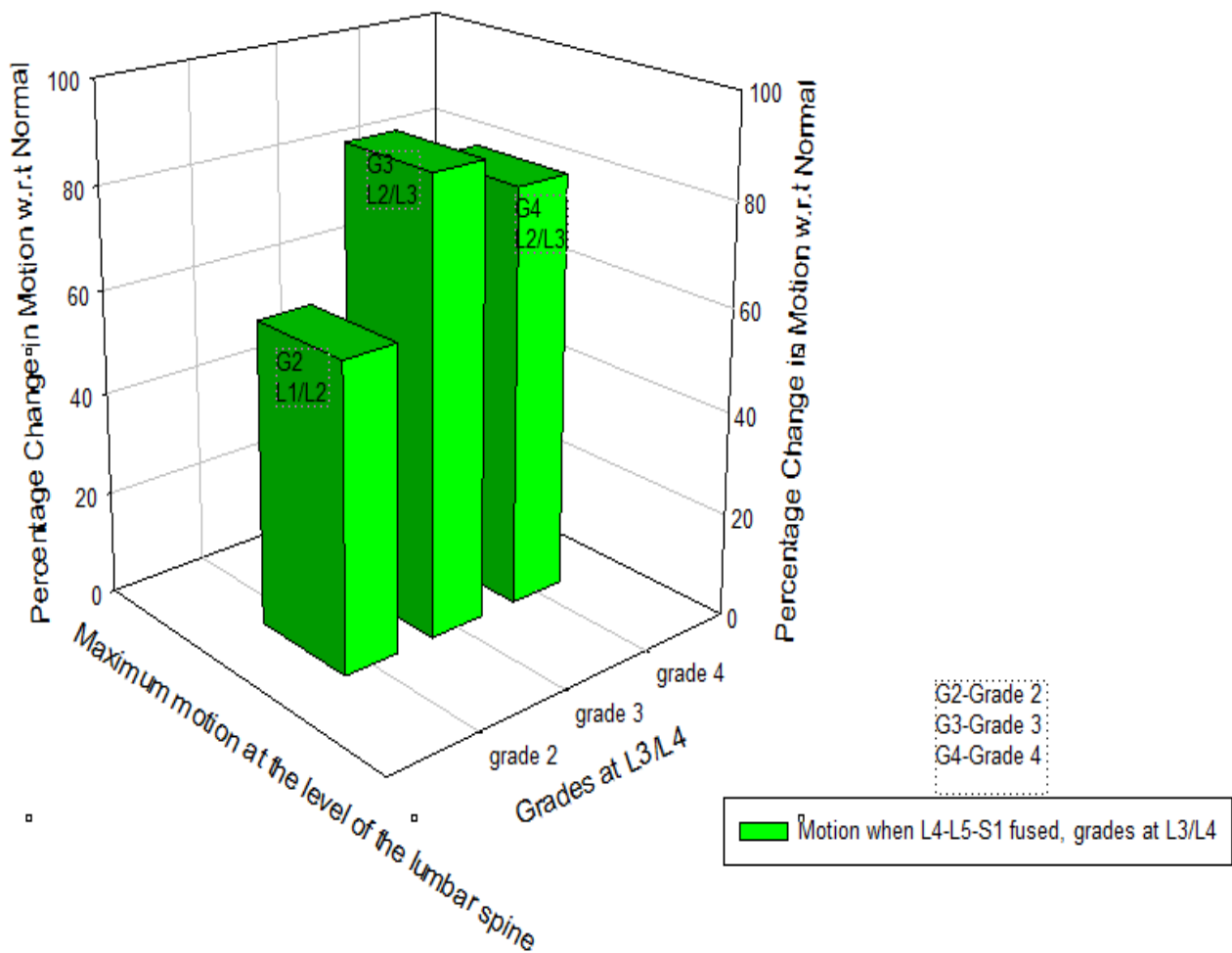
Graph 17: Maximum change in motion at the level of lumbar spine under extension

Change in Motion when L4-L5-S1 fused with grades of degeneration at L3/L4 (Lateral Bending)



Graph 18: Maximum change in motion at the level of lumbar spine under lateral bending

Change in Motion when L4-L5-S1 fused with grades of degeneration at L3/L4 (Torsion)

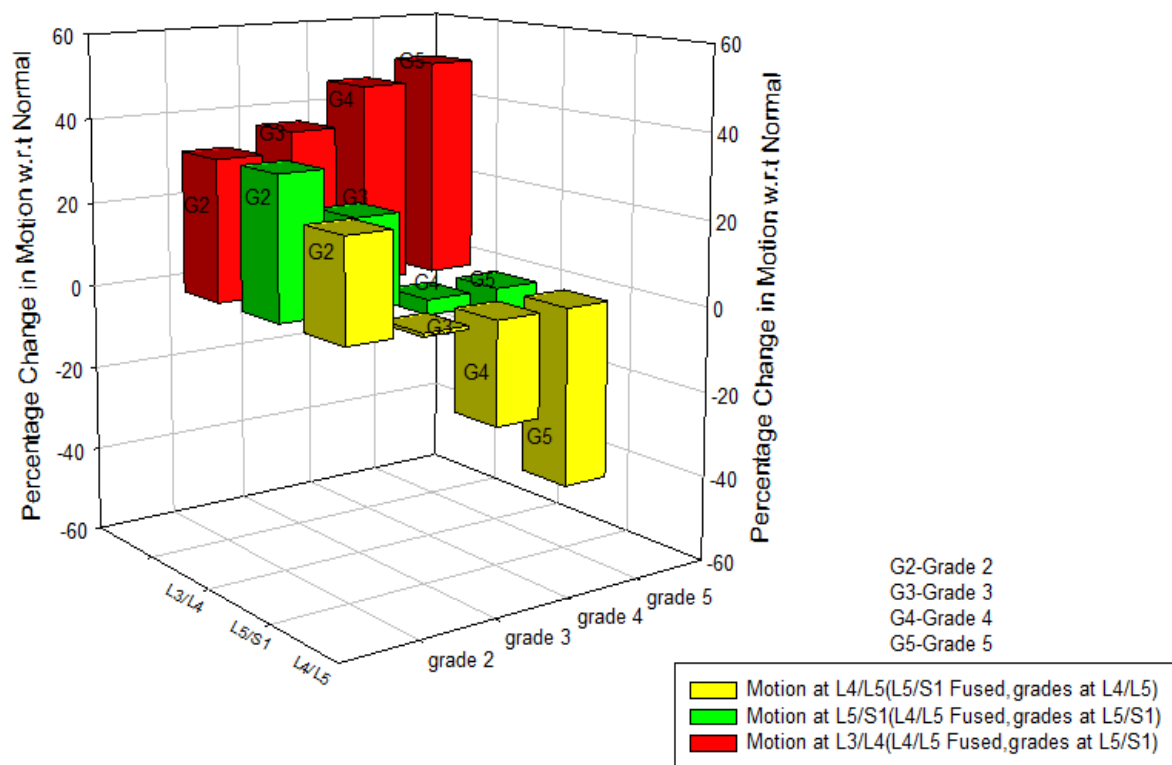


Graph 19: Maximum change in motion at the level of lumbar spine under torsion

The graphs with consideration of all the parameters including site of fusion, number of levels fused, and grades of degeneration for a single level fusion

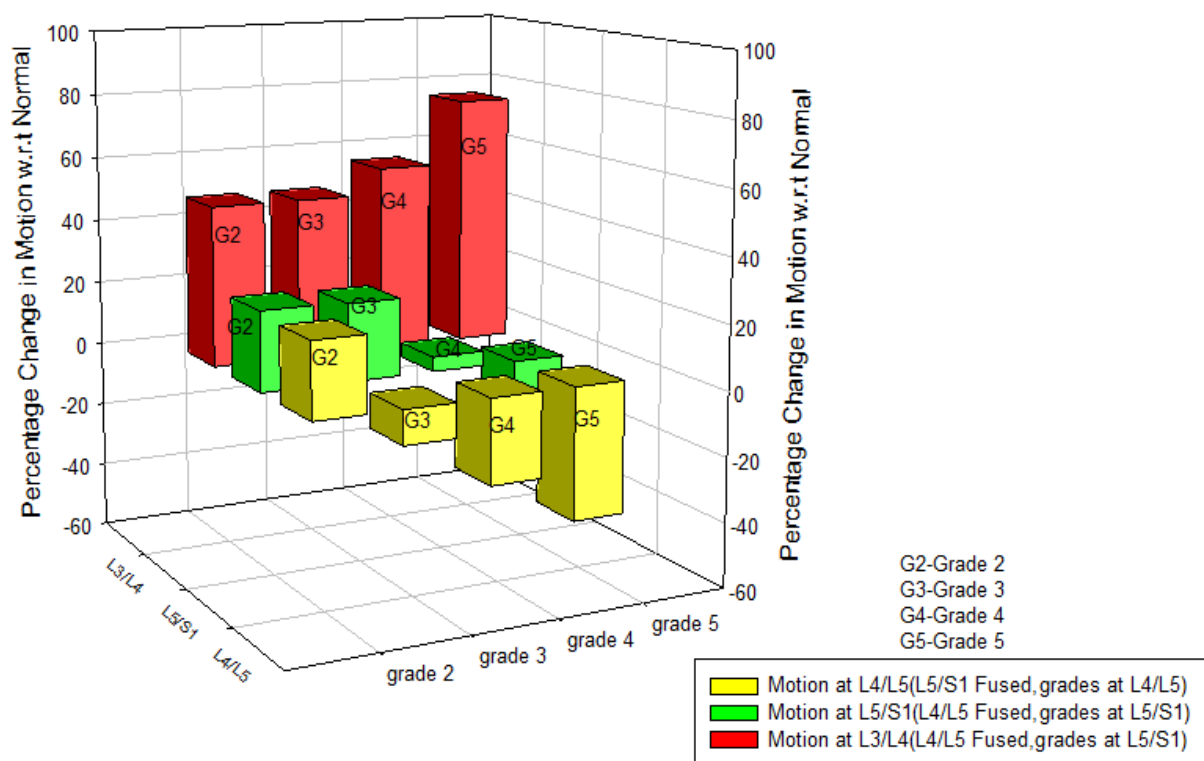
- 1) Comparing motion at L3/L4 and L5/S1, when L4/L5 fused with grades of degeneration at L5/S1. Also, comparing motion at L4/L5 when L5/S1 fused with grades of degeneration at L4/L5 under each moment loads.

Change in motion when L4/L5 fused with grades of degeneration at L5/S1(indicated in Red and Green)
 Change in motion when L5/S1 fused with grades of degeneration at L4/L5(indicated in Yellow)
 Flexion



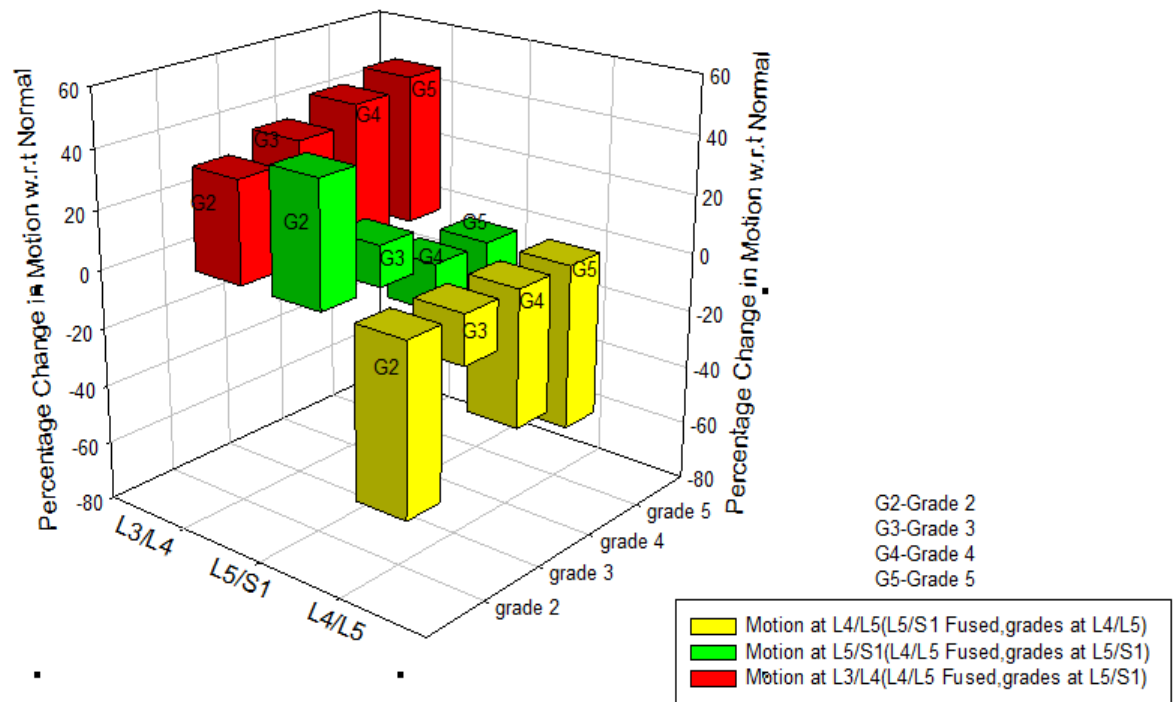
Graph 20: Comparing motion at L3/L4 and L5/S1, when L4/L5 fused with grades of degeneration at L5/S1. Comparing motion at L4/L5 when L5/S1 fused with grades of degeneration at L4/L5 under flexion.

Change in motion when L4/L5 fused with grades of degeneration at L5/S1(indicated in Red and Green)
 Change in motion when L5/S1 fused with grades of degeneration at L4/L5(indicated in Yellow)
 Extension



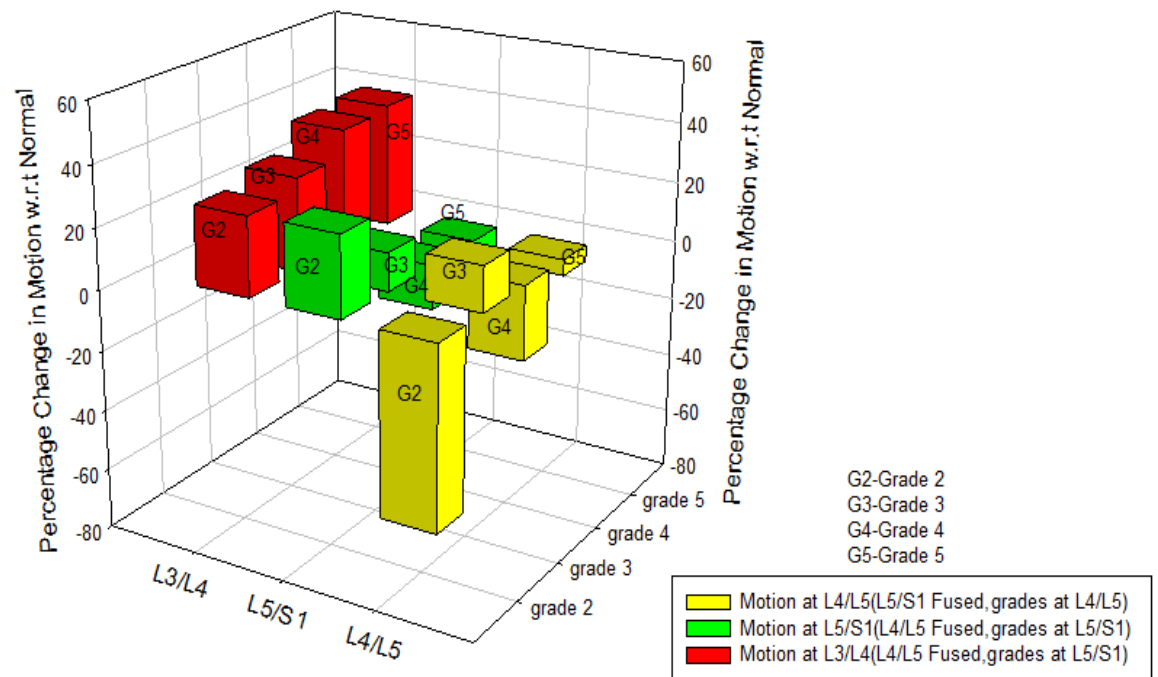
Graph 21: Comparing motion at L3/L4 and L5/S1, when L4/L5 fused with grades of degeneration at L5/S1. Comparing motion at L4/L5 when L5/S1 fused with grades of degeneration at L4/L5 under extension

Change in motion when L4/L5 fused with grades of degeneration at L5/S1(indicated in Red and Green)
 Change in motion when L5/S1 fused with grades of degeneration at L4/L5(indicated in Yellow)
 Lateral bending



Graph 22: Comparing motion at L3/L4 and L5/S1, when L4/L5 fused with grades of degeneration at L5/S1. Comparing motion at L4/L5 when L5/S1 fused with grades of degeneration at L4/L5 under lateral bending

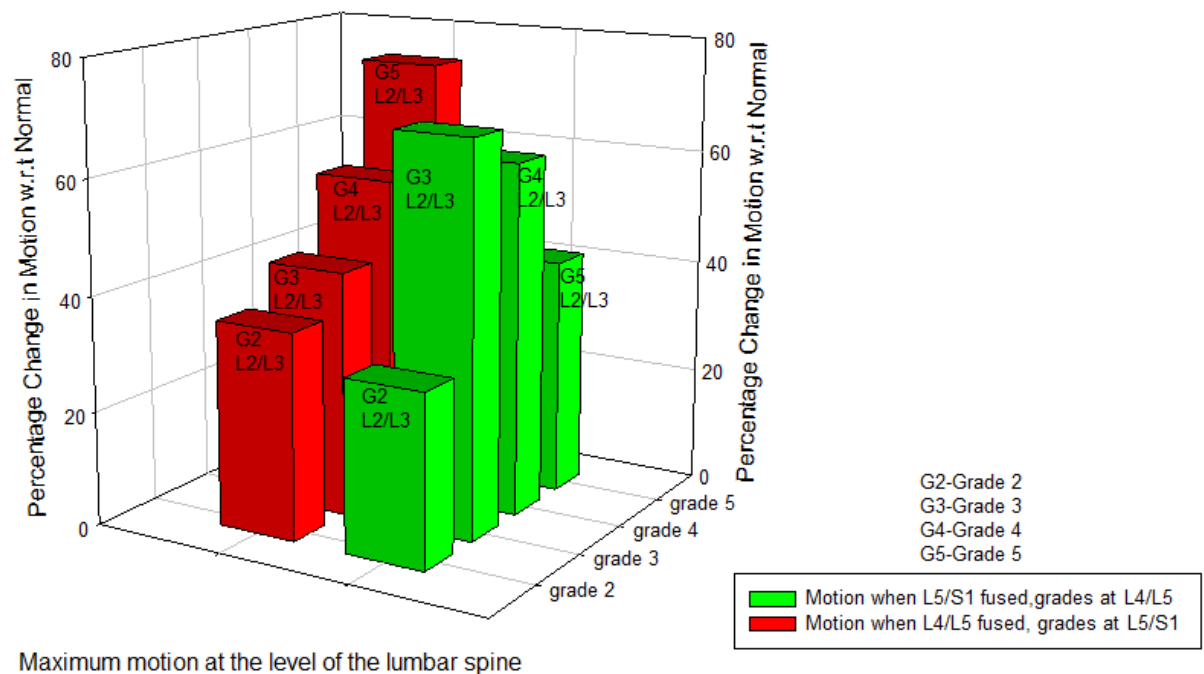
Change in motion when L4/L5 fused with grades of degeneration at L5/S1(indicated in Red and Green)
 Change in motion when L5/S1 fused with grades of degeneration at L4/L5(indicated in Yellow)
 Torsion



Graph 23: Comparing motion at L3/L4 and L5/S1, when L4/L5 fused with grades of degeneration at L5/S1. Comparing motion at L4/L5 when L5/S1 fused with grades of degeneration at L4/L5 under torsion.

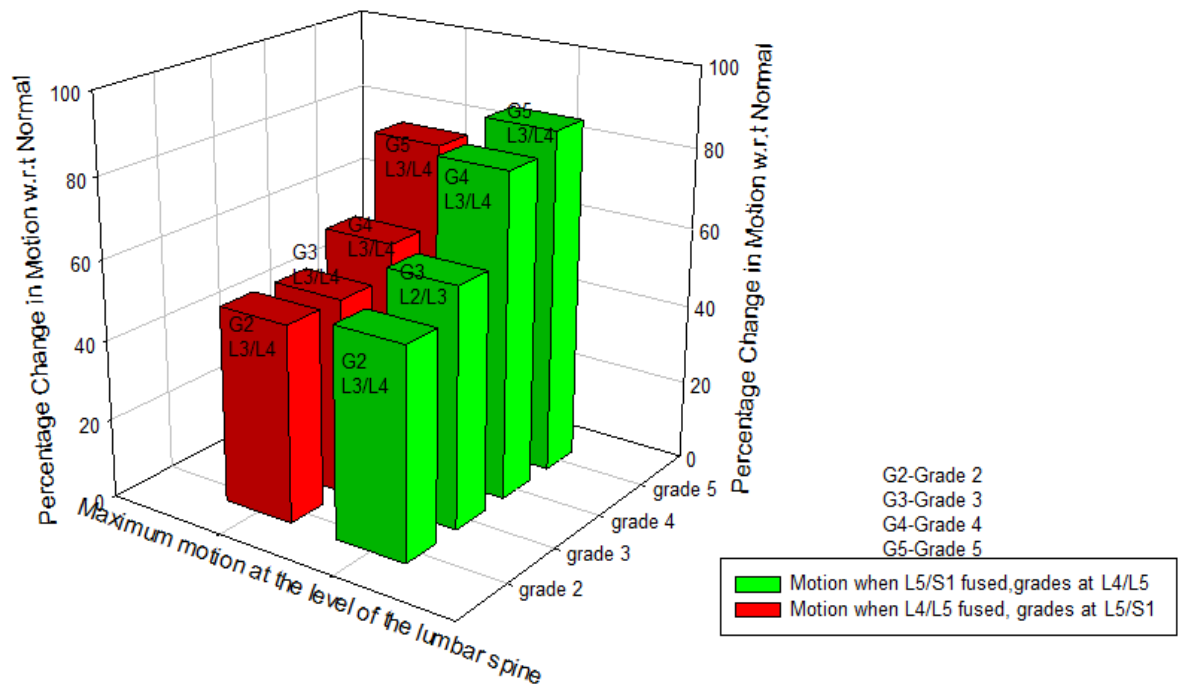
- 2) Maximum increase in motion through the lumbar spine when L4/L5 fused with grades of degeneration at L5/S1 and when L5/S1 fused with grades of degeneration at L4/L5 under each moment load.

Change in motion when L4/L5 fused with grades of degeneration at L5/S1(indicated in Red)
 Change in motion when L5/S1 fused with grades of degeneration at L4/L5(indicated in Green)
 Flexion



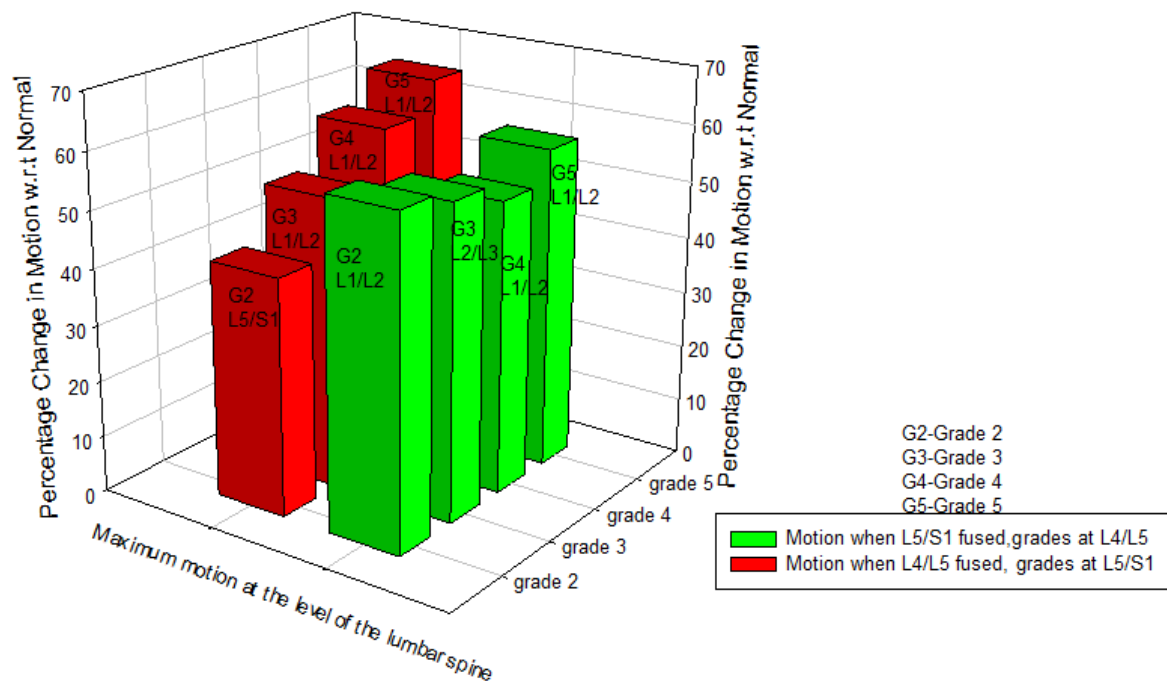
Graph 24: Maximum increase in motion through the lumbar spine when L4/L5 fused with grades of degeneration at L5/S1 and when L5/S1 fused with grades of degeneration at L4/L5 under flexion

Change in motion when L4/L5 fused with grades of degeneration at L5/S1(indicated in Red)
 Change in motion when L5/S1 fused with grades of degeneration at L4/L5(indicated in Green)
 Extension



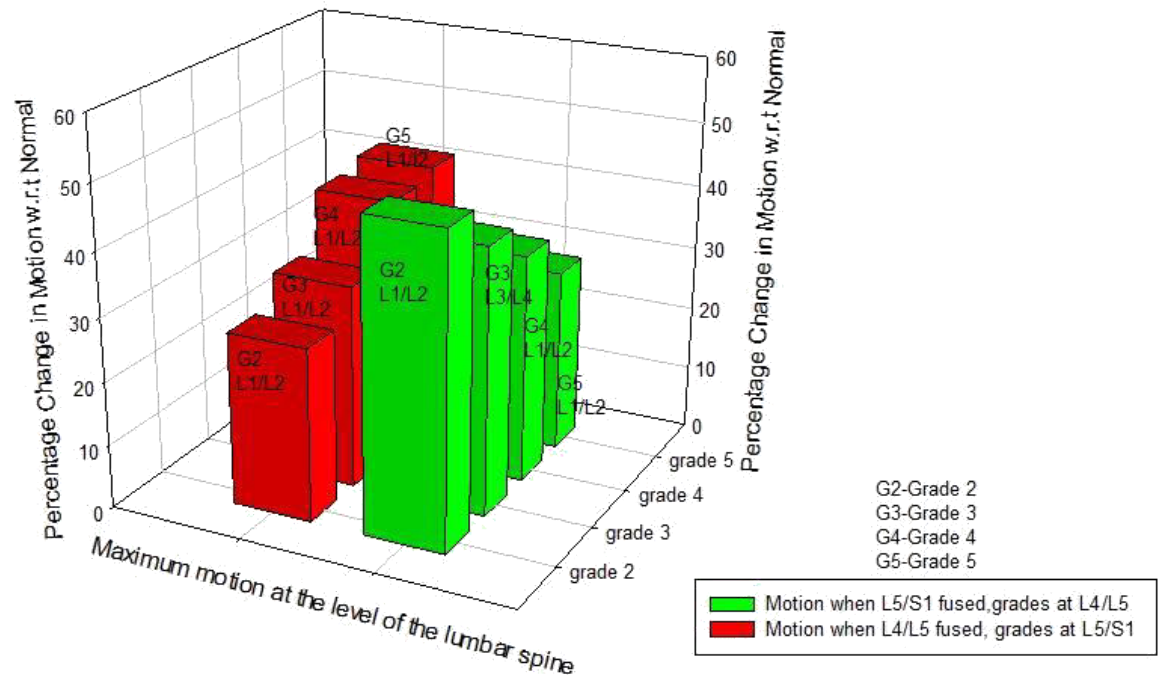
Graph 25: Maximum increase in motion through the lumbar spine when L4/L5 fused with grades of degeneration at L5/S1 and when L5/S1 fused with grades of degeneration at L4/L5 under extension.

Change in motion when L4/L5 fused with grades of degeneration at L5/S1(indicated in Red)
 Change in motion when L5/S1 fused with grades of degeneration at L4/L5(indicated in Green)
 lateral bending



Graph 26: Maximum increase in motion through the lumbar spine when L4/L5 fused with grades of degeneration at L5/S1 and when L5/S1 fused with grades of degeneration at L4/L5 under lateral bending.

Change in motion when L4/L5 fused with grades of degeneration at L5/S1(indicated in Red)
 Change in motion when L5/S1 fused with grades of degeneration at L4/L5(indicated in Green)
 torsion



Graph 27: Maximum increase in motion through the lumbar spine when L4/L5 fused with grades of degeneration at L5/S1 and when L5/S1 fused with grades of degeneration at L4/L5 under torsion

Conclusion

A. Single level Fusion

Model 1 A: L4/L5 fused with degeneration grade II at L5/S1

The model representing a single level fusion at (L4/L5) with normal motion segments at all levels predicted an increase in motion under all types of moment load as compared to motions in an intact spine. The loss of the segmental motion at L4/L5 was compensated by an increase in motion at the segments superior and inferior to the fusion. The larger increase in motion at the segment superior to fusion was seen under the flexion and extension moment load, and the larger increase in motion at the segment inferior to fusion was seen under lateral bending and torsion. The maximum increase in motion was seen under extension at the segment superior to the fusion level and the minimum increase was seen under torsion at the segment inferior to the fusion level, when all the types of moment load were observed. Under torsion moment load, the largest increase in motion was seen at the superior most level of the lumbar spine. Under flexion, the maximum increase in motion was observed at the segment superior (L2/L3) to the superiorly adjacent segment to the fusion level.

Inclusion of ASDD

Model 1 B: L4/L5 fused with degeneration grade III at L5/S1

The model representing a single level fusion at (L4/L5) with normal motion segments at all levels predicted an increase in motion under all types of moment load as compared to motions in an intact spine. The loss of the segmental motion at L4/L5 was compensated by an increase in motion at the segments superior and inferior to the fusion. The larger increase was seen at the adjacent segment superior to the fusion. There was a relatively smaller increase at the adjacent segment inferior to the fusion due to inclusion of grade III degeneration at that segment. The maximum increase in motion was

observed at the adjacent segment superior to the level of fusion under extension moment load. Under lateral bending and torsion moment load, maximum increase was seen at the superior most level of the lumbar spine and under flexion moment load, the maximum increase in motion was seen at the second most superior level of the lumbar spine.

Model 1 C: L4/L5 fused with degeneration grade IV at L5/S1

This model representing a single level fusion predicted an increase in motion at the segments superior to the fusion. However, motions at the level inferior to the fusion (L5/S1) decreased under all types of load except extension. Under extension, larger increase in motion was observed at the level superior to the fusion. Under flexion, larger increase in motion was observed at the level second most superior to the fusion. Under torsion and lateral bending the maximum increase in motion was seen at the superior most segments (L1/L2) of the lumbar spine.

Model 1 D: L4/L5 fused with degeneration grade IV at L5/S1

This model representing a single level fusion predicted an increase in motion at the segments superior to the fusion under all types of moment load. However, motions at the level inferior to the fusion (L5/S1) decreased under all types of load. Under extension, larger increase in motion was observed at the level superior to the fusion. Under flexion, larger increase in motion was observed at the level second most superior to the fusion. Under torsion and lateral bending the maximum increase in motion was seen at the superior most segments (L1/L2) of the lumbar spine. This shows that as the grade of degeneration increase at the segment, the motion at that segment decrease.

Model 2 A: L5/S1 fused with degeneration grade II at L4/L5

The model representing a single level fusion at (L5/S1) with normal motion segments at all levels predicted an increase in motion under all types of moment load as compared to motions in an intact spine. The loss of the segmental motion at L5/S1 was compensated by an increase in motion at the segments superior to the fusion. There was an increase in motion at the adjacent segment superior (L3/L4) to the level of fusion under flexion and extension moment load. However, the larger increase was seen at the second most superior segment of the lumbar spine under flexion and at the segment superior to the superiorly adjacent segment to the fusion under extension. The motion at the adjacent segment superior to the fusion decreased under lateral bending and torsion. But, the motion increased significantly at the superior most level (L1/L2) of the lumbar spine under lateral bending and torsion.

Inclusion of ASDD

Model 2 B: L5/S1 fused with degeneration grade III at L4/L5

This model representing a single level fusion predicted a decrease in motion at the segment superiorly adjacent (L4/L5) to fusion L5/S1 under all types of moment load except torsion. The largest increase in motion was seen at the second most superior level (L2/L3) under flexion, extension and lateral bending. The largest increase in motion under torsion was seen at L3/L4. The grade of degeneration simulated at a segment, decrease the motion at that segment.

Model 2 C: L5/S1 fused with degeneration grade IV at L4/L5

This model representing a single level fusion predicted a decrease in motion at the segment superiorly adjacent (L4/L5) to fusion L5/S1 under all types of moment load. The largest increase in motion was seen at the superior most segments L1/L2 of the lumbar spine except flexion. The largest increase in motion under flexion moment load was seen at L2/L3. The decrease in motion at the segment superiorly adjacent to the fusion is due to the higher grade of degeneration simulated at that segment (L4/L5).

Model 2 D: L5/S1 fused with degeneration grade V at L4/L5

This model representing a single level fusion predicted a decrease in motion at the segment superiorly adjacent (L4/L5) to fusion L5/S1 under all types of moment load. There was an increase in motion at the segments above the fusion, but there was a significant decrease in motion at the segment having grade V at L4/L5 adjacent to the fusion when compared to normal bone under all types of moment load. The largest increase in motion was seen at the superior most segments L1/L2 of the lumbar spine except flexion. The largest increase in motion under flexion moment load was seen at L2/L3.

When considering the overall motion of the lumbar spine, there was decrease in motion at the adjacent segments when adjacent segment degenerated disease was considered. And, there was increase in motion at the segment adjacent to the fusion when ASDD was not simulated.

B. Two level fusion:

Model 3 A: L4/L5/S1 fused with degeneration grade II at L3/L4

This model representing a two level fusion predicted an increase in motion at the segment (L3/L4) superiorly adjacent to the fusion level under all types of moment load. There was an increase in motion at the superior most level (L1/L2) as well as second superior most level (L2/L3) of the lumbar spine under all types of moment load.

Inclusion of ASDD

Model 3 B: L4/L5/S1 fused with degeneration grade III at L3/L4

This model representing a two level fusion predicted an increase in motion at the segment (L3/L4) superiorly adjacent to the fusion level under all types of moment load. There was an increase in motion at the superior most level (L1/L2) as well as second superior most level (L2/L3) of the lumbar spine under all types of moment load.

Model 3 C: L4/L5/S1 fused with degeneration grade IV at L3/L4

This model representing a two level fusion predicted a decrease in motion at the segment (L3/L4) superiorly adjacent to the fusion level under all types of moment load except extension and torsion. The motion at the segment L3/L4 decrease due to simulation of increased grade of degeneration at that particular segment. There was an increase in motion at the superior most level (L1/L2) as well as second superior most level (L2/L3) of the lumbar spine under all types of moment load.

Discussion:

A. One level fusion

It was observed that in a spine with bone graft fusion produced decreased motion at the level of fusion as compared to the motion in normal lumbar spinal motion segment. For all the loading modes considered, segment fused with the graft was found to be stiffer than the normal segment. Similar observation was made in a spine with ASDD. The finding that the fusion makes the motion segment stiffer is consistent with experimental and clinical findings. The graft bone deformed more like a solid along with the adjacent vertebra and thus produces lesser rotational motion due to bending loads. When fusion was modeled using a graft bone either in a spine with normal bone or a spine with ASDD, the reduction in motion due to fusion remained nearly the same. The motion in the segments superior and inferior to the segment fused by the graft in normal bone increased marginally, But when the fusion was modeled with the spine having ASDD, the motion at that adjacent segment decreased with the increasing grades of degeneration. Thus, motions in the segments adjacent to the fusion behaved differently when fusion was achieved in normal bone as compared to the spine with the ASDD.

B. Two level fusion

It was observed that the bone graft fusion in normal bone produced decreased motion at both the levels of fusion as compared to the motion in a normal lumbar spinal motion segments. For all the loading modes considered, segment fused with the graft was found to be stiffer than the normal segment. Similar observation was made in a spine with ASDD. Reduction in motion at L4/L5 level was similar to those observed when single level fusion at L4/L5 was studied. This phenomenon was observed both in normal spine as well as spine with ASDD. . The motion in the segments superior and inferior to the segment fused by the graft in normal bone increased marginally, But when the fusion was modeled with the spine having ASDD, the motion at that adjacent segment decreased with the increasing grades of

degeneration. Thus, motions in the segments adjacent to the fusion behaved differently when fusion was achieved in normal bone as compared to the spine with the ASDD.

C. Comparison between single-level fusion and two-level fusion

The behavior of the fused segments was similar in both single level and two level fusion cases. The percentage reduction in motion was also similar in both single level and two level fusions either with normal spine or the spine having ASDD. The effect of fusion on the motions of adjacent segments was also similar in single level fusion and two level fusions. The motions at the adjacent segment were affected by the grades of degeneration at that particular segment adjacent to the fusions.

The following conclusions are achieved from the current study:

- 1) The fusion with graft in both normal bone and with ASDD produces decrease in motion at the level of fusion when compared to the motion at normal lumbar spinal motion segment. This conclusion was applicable for both single level and two level fusions.
- 2) When the fusion was modeled with the spine having ASDD, the motion at that adjacent segment decreased with the increasing grades of degeneration. This conclusion was applicable for both single level and two level fusions.

Cited Literature:

Axelsson P, Johnsson R, Stromqvist B. The spondylolytic vertebra and its adjacent segment. Mobility measured before and after posterolateral fusion. Spine 1997; 414-417.

Bastian L, Lange U, Knop C., et al., Evaluation of the mobility of the mobility of adjacent segments after posterior thoracolumbar fixation: a biomechanical study. Eur Spine Journal 2001; 10; 295-300.

Chen CS, Cheng Ck, Liu CL., A biomechanical comparison of posterolateral fusion and posterior fusion in the lumbar spine, J, Spinal disorders tech 2002;15;53-63.

Chen CS, Cheng Ck, Liu CL., et al., Stress analysis of the disc adjacent to interbody fusion in lumbar spine. Med EngPhys 2001; 23; 483-491.

Cheh G, Bridwell KH, Lenke LG, et al., Adjacent segment disease following lumbar/thoracolumbar fusion with pedicle screw instrumentation: a minimum 5-year follow-up; Spine 2007; 32; 2253-2257.

Chow DH, Luk KD, Evans JH., et al., Effects of short anterior lumbar interbody fusion on biomechanics of neighboring unfused segments. Spine 1996; 21; 549-555

Dekutoski MB, Schendel MJ, Ogilvie JW, et al. Comparison of in vivo and invitro adjacent segment motion after lumbar fusion. Spine 1994; 19; 1745-1751

Disch AC, Schmoelz W, Matziolis G, et al., Higher risk of adjacent segment degeneration after floating fusions: long term outcome after low lumbar fusions; J. Spinal Disorders Tech 2008;21;79-85.

Ekman P, Miller H, Shalabi A, et al., A prospective randomized study on the long term effect of lumbar fusion on adjacent disc degeneration; Eur Spine J 2009; 18; 1175-1186.

Esses SI, Doherty BJ, Crawford MJ., et al., Kinematics evaluation of lumbar fusion techniques, Spine 1996; 21; 676-684.

Frymoyer JW, Hanley EN, Howe J et al., A comparison of radiographic findings in fusion and nonfusion patients ten or more years following lumbar disc surgery, Spine 1979; 435-440.

Fujiwara A, Lim TH, An HS, et al., The effect of disc degeneration and facet joint osteoarthritis on the segmental flexibility of the lumbar spine. Spine 2000; 25; 3036-3044.

Ghiselli G, Wang JC, Bhatia NN, et al., Adjacent segment degeneration in the lumbar spine; The journal of Bone and joint Surgery 2004;86-A;1497-1503.

Ha KY, Schendel MJ, Lewis JL., et al., Effect of immobilization and configuration on lumbar adjacent segment biomechanics. J. Spinal Disorders 1993;6;99-105.

Kim KH, Lee SH, Shim CS, et al., Adjacent segment disease after interbody fusion and pedicle screw fixations for isolated L4-L5 spondylolisthesis: a minimum five-year follow up; Spine 2010;35;625-634.

Kanayama M, Togawa D, Hashimoto T, et al., Motion-preserving surgery can prevent early breakdown of adjacent segments: comparison of posterior dynamic stabilization with spinal fusion; J, Spinal Disord tech 2009;7;463-467.

Lee CK, Langrana NA, Lumbosacral spinal fusion. A biomechanical study. Spine 1984; 9; 574-581.

Lehmann TR, Spratt KF, Tozzi JE, et al., Long term follow up of lower lumbar fusion patients. Spine 1987; 12; 97-104.

Mimura M, Panjabi MM, Oxland TR, et al., Disc degeneration affects the multidirectional flexibility of the lumbar spine. Spine 1994; 19; 1371-1380.

Nagata H, Schendel MJ, Transfeldt EE., et al., The effects of immobilization of long segments of the spine on the adjacent and distal facet force and lumbosacral motion. Spine 1993; 18; 2471-2479.

Natarajan RN, Williams JR, Andersson GBJ. Biomechanical comparison between two techniques used to modeling annular fibers in a lumbar motion segment, Transactions of 53rd Annual Meeting of Orthopedic Research Society. February 11-14, 2007, Poster 1018.

Renner SM, Natarajan RN, Patwardhan AG, et al.,; Novel model to analyze the effect of a large compressive follower preload on range of motions in a lumbar spine; J. Biomechanics 2007;40;1326-1332.

Ruberte LM, Natarajan RN, Andersson GBJ. Influence of single level lumbar degenerative disc disease on the behavior of the adjacent segments- A finite element model study. J. Biomechanics 2009; 42; 341-348.

Schulte TL, Leistra F, Bullmann V, Osada N. et al., Disc height reduction in adjacent segments and clinical outcome 10 years after lumbar 360 degrees fusion. Eur Spine J 2007; 16; 2152-215.

Shirazi-Adl M. El-Rich¹ D. G. Pop¹ and M. Parnianpour; Spinal muscle forces, internal loads and stability, in standing under various postures and loads-application of kinematics based algorithm.

Suratwala SJ, Pinto MR, Gilbert TJ, et al., Functional and radiological outcomes of 360 degrees fusion of three or more motion levels in the lumbar spine for degenerative disc disease. Spine 2009; 34; 351-358.

Weinhoffer SL, Guyer RD, Herbert M, et al., Intradiscal pressure measurement above an instruments fusion. A cadaveric study. Spine 1995;20;526-531.