The Role of Interleukin-8 in Cyclosporin A-Induced Gingival Overgrowth

BY

CHARLES C. DIFRANCO
B.A., MIAMI UNIVERSITY, OHIO, 2007
D.D.S., UNIVERSITY OF ILLINOIS AT CHICAGO, 2011

THESIS

Submitted as partial fulfillment of the requirements
for the degree of Master of Science in Oral Sciences
in the Graduate College of the
University of Illinois at Chicago, 2014

Chicago, Illinois

Thesis Committee

Thomas C. Hart, D.D.S., Ph.D., Chair and Advisor, Department of Periodontology, College of Dentistry

Joel L. Schwartz, D.M.D., DMedSc, Department of Oral Medicine and Diagnostic Sciences, College of Medicine

Herve Y. Sroussi, D.M.D., Ph.D., Department of Oral Medicine and Diagnostic Sciences, College of Medicine

This thesis is dedicated to my wife, Marissa DiFranco. Without her constant support and unconditional love this could have never been accomplished.

ACKNOWLEDGEMENTS

I would like to thank my thesis committee for all their time and effort put forth to make this all possible. I would also especially like to thank my primary advisor and mentor, Dr. Tom Hart. The countless hours of work spent completing this research project together were memorable and meaningful. I can honestly say that I am a better person because of this work, and the lessons handed down to me both on a personal and professional level.

CCD

TABLE OF CONTENTS

TABLE OF CONTENTS (continued)

TABLE OF CONTENTS (continued)

LIST OF TABLES

LIST OF FIGURES

LIST OF ABBREVIATIONS

BMP	Bone morphogenic protein
CsA	Cyclosporin A
CTGF	Connective tissue growth factor
ECM	Extracellular matrix
ELISA	Enzyme-linked immunosorbent assay
EMT	Epithelial-mesenchymal transition
EndMT	Endothelial-mesenchymal transition
FOXO1	Forkhead box protein O1
GCF	Gingival crevicular fluid
GO	Gingival overgrowth
HGF	Human gingival fibroblast
HLA	Human Leukocyte Antigen
IFMA	Immunofluorometric assay
IIF	Indirect immunofluorescence
ISH	In-situ hybridization
IL-	Interleukin-
LPS	Lipopolysaccharide
MMP	Matrix metalloproteinase
NFAT	Nuclear factor of activated T-cells
PAMPS	Pathogen-associated molecular patterns
PDGF	Platelet derived growth factor
PCR	Polymerase chain reaction
RT-PCR	Reverse transcription polymerase chain reaction
RT-PCR	Real time polymerase chain reaction
RT-qPCR	Quantitative real time polymerase chain reaction
RT-qPCR	Quantitative reverse transcription polymerase chain reaction
SOS-1	Son of sevenless-1
TIMP	Tissue-inhibitor of matrix metalloproteinase

SUMMARY

This study examines the link between Cyclosporin A (CsA)-induced gingival overgrowth and the chemokine interleukin-8 (IL-8), and its high-affinity receptor, CXCR1. Gingival biopsies were taken from 14 adult renal transplant patients treated with CsA and 3 healthy adult control subjects. CsA serum levels were regulated between 80-300ng/ml and the CsA group was dichotomized based on presence (n=11), or absence (n=3) of gingival overgrowth. RNA was extracted from gingival tissues, and gene array experiments were performed. Expression analysis was performed using the Geospiza Genesifter software package (PerkinElmer). Clinical information was collected on all teeth excluding third molars regarding periodontal probing depths, plaque index, bleeding index, hyperplastic index, and radiographic bone loss.

Both groups medicated with CsA had significantly higher expression levels of *IL-8* compared to control tissues. However, only the CsA gingival overgrowth group was observed to have increased expression levels of *CXCR1* compared to control tissues.

CsA drives increased expression levels of *IL-8* in human gingival tissues, and *CXCR1* is upregulated in CsA GO tissues. Increased *IL-8/CXCR1* expression has been reported to drive recruitment and differentiation of pro-fibrotic cells capable of producing an increase in collagen and ECM components in fibrotic diseases of other tissues. This is the first reported data in the dental literature relating these two fields, and may provide an etiologic mechanism that contributes to CsA-GO in susceptible patients.

1. INTRODUCTION

1.1 Gingiva

The gingiva is part of the oral mucosa that encompasses the alveolar process and surrounds the cervical portion of teeth. Anatomically the gingiva is divided into marginal, attached, and interdental areas, while histologically, there is an overlying stratified squamous epithelium and an underlying layer of connective tissue.[1]

The principal cell type of the gingival epithelium is the keratinocyte, while other cellular contents include Langerhans cells, Merkel cells, and melanocytes.[1, 2] The major function of the gingival epithelium is to provide protection to the individual by serving as a physical barrier, as well as participating in a selective cell interchange with the oral environment as part of host defenses. These cells are instrumental to the host defenses in that they participate in responding to microbial invaders, integrate the innate and acquired immune responses, as well as aid in signaling further host responses.[1] Proliferation and differentiation of the keratinocytes are instrumental to these functions, with differentiation involving the process of keratinization.[1] The oral gingival epithelial layer is the portion of the gingival epithelium that is keratinized, while the other two types of gingival epithelium, the sulcular and junctional epithelium, are non-keratinized. Therefore, only the oral gingival epithelium consists of a cornified layer (stratum corneum), while all three types of gingival epithelium contain a basal layer (stratum basale), stratum spinosum, and stratum granulosum.[3]

The principal cell type of the gingival connective tissue is the fibroblast. Fibroblasts synthesize collagen, elastic fibers, glycoproteins, and glycosaminoglycans.

They also regulate the degradation of collagen via phagocytosis and secretion of collagenases.[1] Other functions of gingival fibroblasts that have been described include the ability to express a wide variety of cytokines and chemokines including interleukin-1, 6, and 8 (IL-1, IL-6, IL-8), as well as their receptors.[4, 5] Also, it has been well established that heterogeneity exists among fibroblasts in the periodontium, which can account for differences in response to environmental and chemical stimulation.[6, 7] The major component of the gingival connective tissue is collagen, with blood vessels, nerves, and extracellular matrix (ECM) making up the remainder. Other cells found in the gingival connective tissue include undifferentiated mesenchymal cells, mast cells and macrophages.[3]

In contrast to the epithelium, where cells are generally in close adaptation and there is minimal extracellular space, the underlying connective tissue contains a complex ECM consisting of protein and proteoglycan components.[8] Collagenous proteins make up most of the matrix proteins within the interstitial matrix, with type I collagen predominating in dense bundles of thick fibers, and type III collagen making up less bulk as thinner fibers in a reticular pattern. Non-organic components include proteoglycans, which encompass glycosaminoglycans like dermatan sulfate (60%), chondroitin sulfate (30%), and equal proportions of hyaluronan and heparin sulfate (10%).[8] The ECM also includes the basement membrane, consisting of nonfibrillar type IV collagen and adhesive glycoproteins, which sit between the epithelium and underlying lamina propria.[9] Collectively, these proteins and carbohydrate polymers provide support for the surrounding cells, aid in cell polarity, and actively participate in cellular communication for functions such as growth, wound healing, and fibrosis.[9]

1.2 Gingival Overgrowth and Tissue Fibrosis

Gingival overgrowth (GO) and gingival enlargement are terms that refer to the benign enlargement of the keratinized gingiva in the oral cavity. GO can be caused by a multitude of factors including systemic conditions, genetic mutations, and a number of medications.[10, 11] Other terms that are used to describe drug-induced gingival overgrowth such as “gingival hyperplasia” and “gingival hypertrophy” may be misleading due to their specific descriptions based on cellular biology.[10] Hypertrophy is characterized by an increase in the size of cells through an increase in the synthesis of structural proteins and cell organelles, and consequently an increase in the size of the organ, while hyperplasia refers to an increase in cell number.[12] Hypertrophy and hyperplasia can both result from physiologic or pathologic processes, and often occur together to contribute to an overall increase in organ size.[9] The term gingival overgrowth will be used throughout the remainder of this text so as not to limit the discussion specifically to hyperplasia or hypertrophy.

GO has been described as a type of tissue fibrosis based on its clinical and histologic appearance.[11, 13-15] Tissue fibrosis is characterized as an increase in the accumulation of fibroblasts, collagen, and other extracellular matrix components.[16, 17] Fibrotic conditions can be found in nearly every tissue in the body, and some of these have known etiologies, yet the etiologic mechanism for medication-induced GO has yet to be fully elucidated.[11, 13, 18-20]

The major cellular contributor to fibrosis is the myofibroblast, which upon its activation is the primary collagen-producing cell.[17] Myofibroblast type cells can be generated from different precursor cells through multiple paths including: resident

mesenchymal cells, epithelial and endothelial cells through a process called epithelial-mesenchymal and/or endothelial-mesenchymal transition (EMT/EndMT), contractile pericytes which wrap around endothelial cells of capillaries and venules, and from circulation of fibroblast-like cells called fibrocytes derived from the bone marrow.[17] Activation of myofibroblasts can be initiated by a variety of mechanisms including: macrophages and lymphocytes via paracrine signals, myofibroblasts via autocrine signaling, and pathogen-associated molecular patterns (PAMPS) from pathogenic organisms that can interact with pattern recognition receptors (like TLRs) on fibroblasts.[17]

1.3 **Medication-Induced Gingival Overgrowth**

There are an increasing number of medications associated with GO, and these medications can be broadly divided into three categories: anticonvulsants, calcium channel blockers, and immunosuppressants.[10] The earliest reports of GO associated with a medication were described in 1939 pertaining to prevention of seizure activity in the brain by diphenylhydantoin (phenytoin or Dilantin).[11] Epilepsy is one of the most common chronic neurological disorders in humans, and phenytoin continues to be among the antiepileptic drugs of choice for treatment of partial and secondarily generalized seizures. The specific cause of phenytoin-induced GO remains poorly understood, and thus a topic of continued research and debate.[11, 13, 21] Other anticonvulsants have also been associated with GO, however valproic acid, carbamazepine, phenobarbital and vigabatrin induced GO in adult patients have been rarely reported.[21]

Calcium channel blockers are antihypertensive drugs which are frequently used in patients with mild, moderate or severe hypertension, angina pectoris, and/or peripheral vascular disease.[10, 11] In general, the reported prevalence of GO with calcium channel blockers is around 10%.[7, 22, 23] Nifedipine, a dihydropyridine calcium channel blocker, was associated with GO in the early 1980's, and similar side effects were seen later with the use of verapamil and diltiazem.[10] Less frequently is GO reported in those taking amlodipine and felodipine.[10] The prevalence of GO in those taking nifedipine varies among studies, and ranges from 15-83%.[22, 24-26] A well controlled study of 181 subjects found that 79 (43.6%) of the participants taking nifedipine displayed detectable GO, and a majority of these (53) exhibited mild gingival overgrowth covering up to 1/3 of the crown, while 19 had moderate, and 2 had severe GO covering up to the middle third, and 2/3 of the crown respectively.[27] Also, a community-based study of 911 patients found that of the 442 taking nifedipine, 6.3% were found to have "significant overgrowth" which the authors felt was clinicaly significant, and 23% were identified to have early gingival enlargement of minimal clinical significance.[23] Calcium channel blockers also may be used in combination with immunosuppressants for transplant rejection in order to minimize the toxicity of these drugs. In such cases, the combination can cause, or exacerbate the already present GO,[24, 28, 29] and it has been reported in phenytoin-induced GO that polypharmacy causes a significant increase in the reported severity and prevalance.[11]

1.4 History Of Cyclosporin A

The classic immunosuppressant that is associated with GO is cyclosporin A (CsA). CsA is derived from the fungus Tolypocladium inflatum Gams, and it was first isolated in Switzerland by Dr. Jean Borel in 1970.[13] The development of CsA came at a crucial time for transplant medicine, as surgical techniques were advancing, however even the most skilled surgeons could only achieve a 20% success rate for heart transplants and 50% success rates for renal transplants at 5 years. The popular immunosuppressant used at that time was azathioprine. This drug was quite toxic and often compromised the patient's immune response, leading to secondary infection from many potential sources. Dr. Borel led the research on CsA, and after teaming up with clinicians for successful animal trials, CsA was approved for use on human subjects in the late 1970's. Success came to the tune of 95% for renal transplants after 5 years, and the term "wonder drug" was aptly coined.[11]

1.5 Phamacokinetics of Cyclosporin A

The therapeutic dose of CsA is typically 10-20 mg/kg body weight per day (oral), with serum concentrations ranging from 100-400 ng/ml. CsA is water insoluble and therefore must be absorbed in the presence of bile salts. Once absorbed in the small intestine, peak concentrations are achieved in 3-4 hours.[13, 30] CsA is distributed throughout many tissues due to its high binding affinity for blood cells and plasma components.[31] Metabolization of CsA is carried out by the cytochrome P450 (CYP) isoenzyme CYP3A4, which is expressed in both the liver and small intestine. There are reportedly large variations in the activity of hepatic and intestinal CYP3A4 between

individuals, and this variability is in part responsible for differences in the metabolism of CsA.[32] Multiple metabolites of CsA have been identified, and are associated with much lower immunosuppressant activity and higher nephrotoxicity.[11, 33, 34] The serum half-life of CsA ranges from 17-40 hours, and a majority of excretion is completed via the bile through the feces, with less than 10% unchanged as it is eliminated as CsA through the kidneys.[13, 35]

1.6 Mechanism of the Immunosuppressive Action of Cyclosporin A

Multiple mechanisms of action have been proposed for the main therapeutic function of cyclosporin A, all of which involve the suppression of T-cell function.[11, 36] One of the well-accepted mechanisms is by inhibition of calcineurin in the T-cell cytoplasm by cyclosporin-cyclophilin complex (see figure 1). Normally calcineurin and calmodulin form a complex that allows the dephosphorylation of the molecule nuclear factor of activated T-cells (NFAT). Once in this activated state, NFAT is allowed to translocate to the nucleus and bind to the promoter site of the interleukin-2 (IL-2) gene. This promotes transcription of IL-2, which is known to be important in T-cell proliferation.[37] Therefore, blocking of the calcineurin-calmodulin complex blocks transcription of IL-2, greatly hindering T-cell proliferation. Additionally it has been found that CsA can produce immunosuppression by inhibition of macrophages and preventing the production of IL-1 receptors on the surface of T-helper cells. While CsA seems to be selective for T lymphocytes, T-helper cells appear to be the main target.[13]

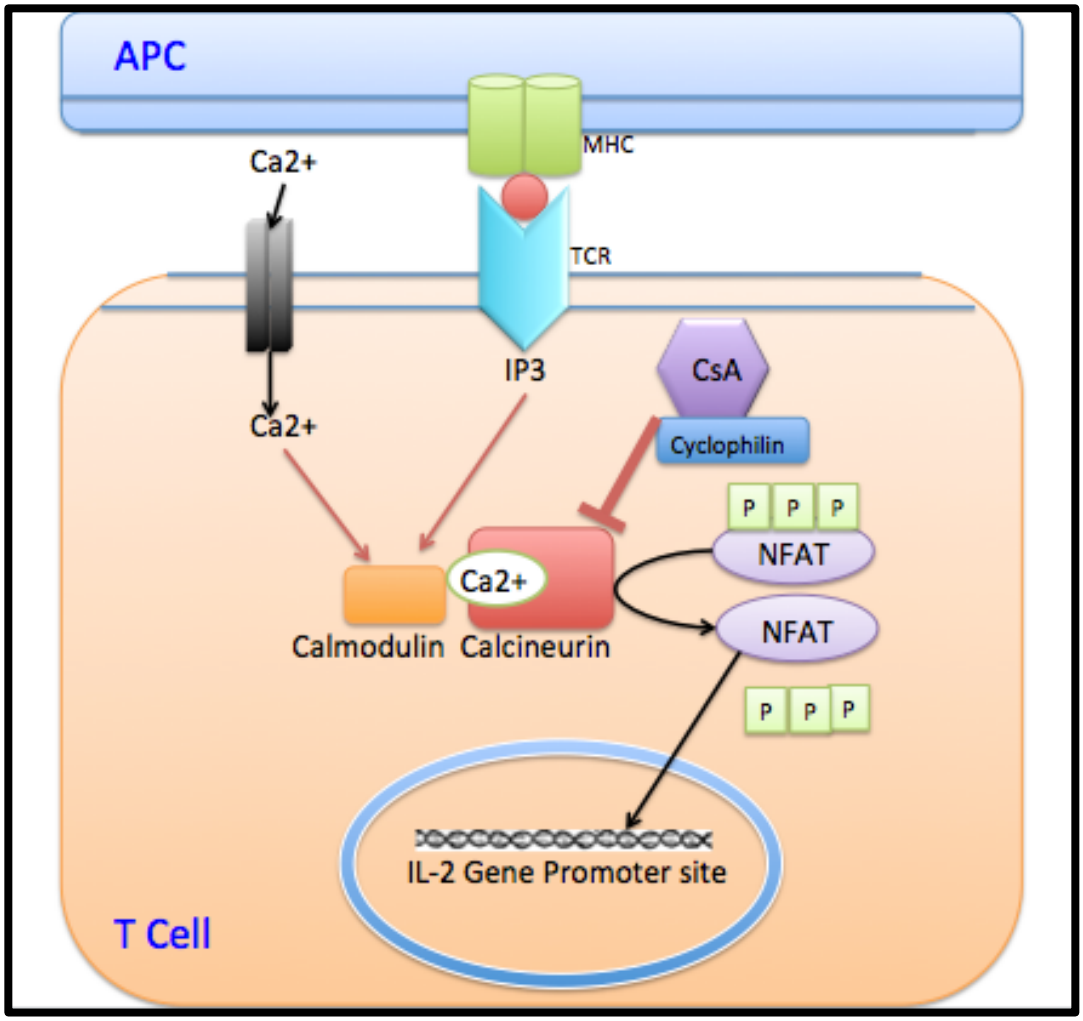

Figure 1: Cyclosporin A Mechanism of Action.

Within the T cell, cyclosporin A binds to cyclophilin, which inhibits the calmodulin-calcineurin complex, which is then unable to dephosphorylate NFAT. This prevents translocation of NFAT to the nucleus and thus production of IL-2. Abbreviations: CsA= cyclosporin A; NFAT=nuclear factor of activated T cells; IL-2=interleukin-2; Ca2+=calcium ion, IP3=inositol triphosphate; MHC=major histocompatibility complex; TCR=T cell receptor, APC= antigen presenting cell.

1.7 Side Effects of Cyclosporin A

The successful use of CsA did not come without its own specific side effects, the more serious of which include nephrotoxicity, hepatoxicity, lymphoma, hypertension, and accumulation of excess connective tissue.[11, 18, 38] Fibrosis of

pulmonary, pericardial, and renal tissues have been reported, and these may be life threatening as loss of tissue function in these organ tissues is potentially fatal.[11] Other reported side effects include gingival overgrowth, diabetes, epilepsy, tremors, lingual fungiform papillae hypertrophy, plasmocytoma, squamous cell carcinoma of the lips, sinusitis, hairy-leukoplakia, biliary calculus disease, neurotoxicity, hirsutism, hypertrichosis, altered bone metabolism, Kaposi's sarcoma, cephalagy, and conjunctivitis.[19]

Chronic nephrotoxicity associated with CsA usage is one of the biggest challenges faced by transplant physicians today. This finding was initially discovered during the first human trials with the drug in the late 1970's.[32] Acute nephrotoxicity can be distinguished from the chronic form since it is rapidly and completely reversible on dose reduction or CsA withdrawal. Chronic CsA renal toxicity is linked with long-term usasge of Cyclosporin A, and has been reported in the treatment of organ transplantation, as well as autoimmune diseases. Also, Chronic CsA-induced nephrotoxicity does not show a marked improvement after reduction of dosage or even removal of the drug.[32]

Chronic CsA-induced nephrotoxicity is characterized histologically by "extensive alterations in the renal architecture that may include arteriolar hyalinosis, glomerular sclerosis and thickening of Bowman's capsule."[32] The disease process of chronic CsA-induced nephrotoxicity has not been fully elucidated, however, certain changes leading to decreaed blood flow, specific toxic effects of CsA, and an upregulation of transforming growth factor-beta (TGF-β) and IL-8 have been implicated as crucial factors.[32, 39]

The most relevant side effect of CsA from a dental practitioner's standpoint is gingival overgrowth. The dental literature first reported this finding and demonstrated a clear relationship between CsA and GO in 1983,[40] with later studies corroborating these findings.[41-43] In those individuals that do develop GO it usually occurs within 6 months, although it may appear as early as 1 month, and usually plateaus around 9-12 months. The overgrowth traditionally disappears, or is significantly minimized with the discontinuation of the drug.[44] Variance in the occurrence of GO ranges from 13-86%, and this is based on multiple factors including plaque control, age, drug serum concentration, length of time on the medication, and how the overgrowth is measured.[7] Lack of a standardized criteria to assess GO is likely the chief reason for the extremes in reported CsA GO prevalence. Based on well-controlled studies, the accepted range is approximately 25-30%.[11, 45] What remains significant is that not all those taking CsA will develop GO, and this has led some to hypothesize that the susceptibility to GO lies with the individual patient as a "responder" or "non-responder" to the drug.[7, 13]

1.8 Clinical Presentation

Cyclosporin A-induced gingival overgrowth has been described previously in that it "commences as a papillary enlargement which is more pronounced on the labial aspects of the gingiva than on the palatal or lingual surfaces."[46] There is variability in the severity of gingival overgrowth among patients, and this can range from very minimal changes in the tissue contour, to enlargement onto the occlusal surface effecting mastication. Tissues have been reported as being soft and fragile, red or

bluish-red, and bled easily upon probing. Compared to phenytoin-induced GO, enlarged tissues have been described as more hyperemic.[13] (see figure 2)

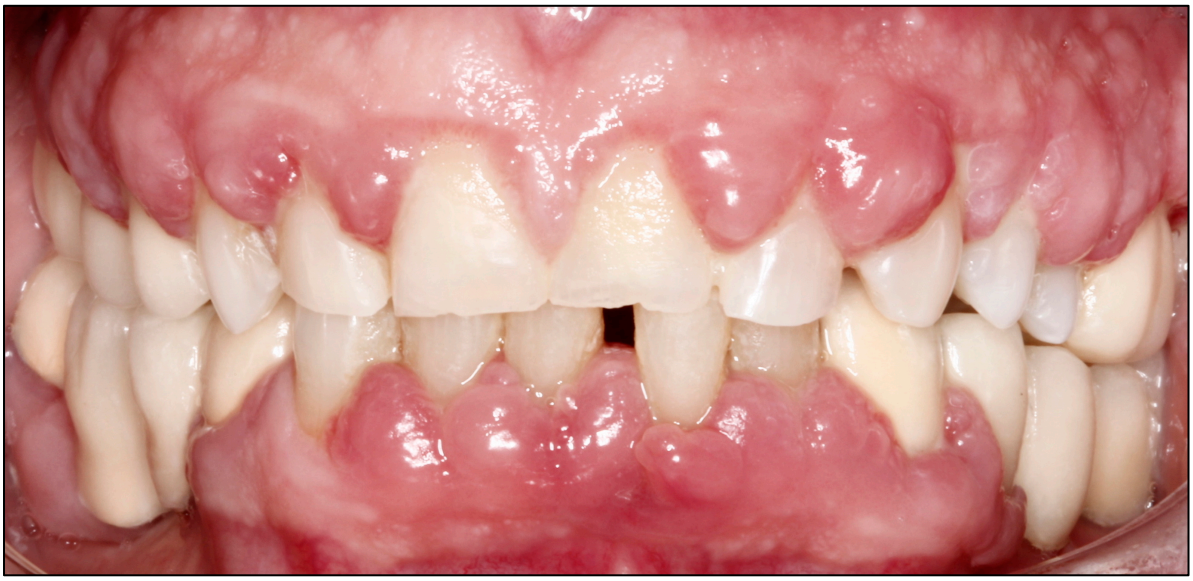

Figure 2: Clinical manifestation of CsA induced GO

Enlargement does not include the alveolar mucosa, however, can influence phonetics, function, esthetics, and occlusion. Notably, CsA induced GO has rarely been reported in edentulous humans subjects, or in edentulous areas in dentate subjects.[40, 47-49]

1.9 Gingival Overgrowth Indices

The first studies to report the use of an index to measure gingival enlargement were by Kimball in 1939 and Harris and Ewalt in 1942.[50] A hyperplastic index that is commonly used to grade GO is that of Angelopoulos and Goaz described in 1972[51] and modified by Pernu et al. in 1992.[44] This index determines the vertical component of overgrowth, with a score of “0” signifying no GO, and three categories are used when GO is present based on severity:

"Score 1 = mild gingival overgrowth; thickening of the marginal gingiva, lobular granulation of the gingival pocket, overgrowth covering the gingival third of the crown or less; Score 2 = moderate gingival overgrowth; overgrowth extending to the middle of the crown; Score 3 = severe gingival overgrowth; overgrowth covering two thirds of the crown or the whole attached gingiva is affected."

This index was modified by Miller and Damm in 1992 to include the horizontal component of GO.[52] The width of the gingiva was measured from the enamel tooth surface to the labial margin of the gingival tissue, and a score of "1" described less that 2mm of increased width, "2" if there was 2-4mm of increased gingival width, and "3" if an increase of >4mm was present.

Other methods to grade GO have included plaster casts used to determine vertical and horizontal enlargement,[53] photographic scoring to analyze GO severity for large-scale usage,[23] 3D laser scanners to accurately detect changes in gingival dimensions,[54, 55] and histopathologic measurements of rete pegs to determine the severity of epithelial tissue enlargement.[26]

1.10 Histology

Histologic assessments of gingival tissues taken from patients exhibiting gingival enlargement induced by CsA were performed shortly after this unwanted side effect was first observed. In general, the histologic features were found to be comparable to that of other drug induced gingival overgrowths. Early case studies

found a surface layer consisting of an irregular multi-layered parakeratinized squamous epithelium, with areas exhibiting attenuated and elongated rete pegs. The connective tissue was noted to be highly vascularized with irregularly arranged collagen fiber bundles (appearing to be in the process of breakdown), and focal accumulations of inflammatory cells.[38, 56]

Mariani et al. 1993 compared gingival specimens from 8 renal transplant subjects on CsA to non-inflamed tissues from control subjects not taking any medications. The renal transplant patients followed a strict oral hygiene regimen, and biopsies were taken only when plaque index was below 0.7. The test subjects exhibited fibroblasts as the predominant cell throughout the connective tissue, as well as an abundance of amorphous ground substance (extracellular matrix that lacks fibrous components such as collagen and elastin[9]) and a marked plasma cell infiltrate. Based on their observations, the increase in gingival mass was determined to be connective tissue in origin, seen as an increase in amorphous ground substance produced by fibroblasts. The authors felt that both the terms “hypertrophy” and “hyperplasia” were incorrect in describing the gingival condition given their histologic analyses, and proposed the term “dimensional increase of gingival tissue.”[57]

A similar experiment was carried out in which gingival biopsies were taken from 13 renal transplant patients, 11 of whom exhibited CsA-induced GO. Control tissues were obtained from seven healthy volunteers. The results indicated that tissues from CsA-induced GO appeared to have “an altered composition characterized by increased thickness of oral epithelium and relatively increased amount of cells,

vessels, non-collagenous matrix, and decreased collagenous matrix in the non-infiltrated connective tissue."[58]

While some studies note an increase in the amount of fibroblasts and collagen,[56] others report the density of fibroblasts and collagenous structures to be similar to that of normal gingiva.[43, 45, 59] Unfortunately, most studies depicting the histologic characteristics of CsA-induced GO are from case reports, and the controlled studies available include very few numbers of patients. Therefore, it seems based on the most well controlled studies, the increase in gingival volume in CsA-induced GO can be explained by the histologic composition of the connective tissues exhibiting an increase in collagen, amorphous ground substance, and infiltrating plasma cells regardless of the presence of plaque biofilm, and without a large change in numbers of fibroblasts.[57, 60] Histologically the epithelial layer appears thickened with an irregular multi-layered parakeratinized squamous epithelium, with areas exhibiting attenuated and elongated rete pegs.[38, 56, 58]

1.11 **Risk Factors for CsA-Induced GO**

Various risk factors for CsA-induced GO have been identified, with some potentially contributing more significantly than others. The only factor that can be modified by an oral healthcare provider is the amount of bacterial plaque biofilm. This is removed through cleaning and debridement, maintained through proper oral hygiene by the patient, and if better access is needed, provided through surgical therapy.[7] Unfortunately, all this must be in concert with the patient's compliance, which is not always an easy task.

1.11.1 **Periodontal Status and Oral Bacteria**

Currently there is conflicting data regarding the effect of dental plaque accumulation and gingival inflammation on CsA GO.[7, 61] Higher concentrations of CsA have been found in dental plaque compared to what is reported for whole blood and other tissues.[62] The potential role of dental plaque as a reservoir for CsA has led some to believe that local concentrations of CsA would be steadily released in a patient with poor oral hygiene and local plaque accumulation. This has been supported by findings in which higher bioavailability of CsA was seen in sites with gingival inflammation versus non-inflamed sites,[63] and plaque index and gingivitis have been recognized as considerable risk factors for gingival overgrowth.[64, 65] Still, other studies have shown dental plaque to have no vital role in the development of CsA GO, and that plaque control had a minimal effect on controlling this process.[49, 66-68] While no consensus remains as to the relative importance of the dental plaque in the development of CsA GO, there does seem to be a general agreement that bacterial plaque biofilm does augment the severity of the GO response, and thus proper oral hygiene measures are essential to improving the condition.[7, 69]

The idea that putative periodontal pathogens have a role in the initiation and progression of CsA GO has been evaluated, however no clear relationship has emerged. Human studies have shown a higher presence of certain bacterial pathogens such as *T. forsythia,T. denticola, P. gingivalis* and *Micromonas micros* in patients taking CsA with GO compared to those on CsA without GO.[70, 71] Similarly, an animal study found an increase in the severity of GO when ligature-induced

periodontitis and an increase in gram negative rods and anaerobic bacteria was present.[72] In contrast, other studies have reported no positive correlation between periodontal pathogens and the development of GO in subjects taking CsA.[73, 74] Therefore, while there may be a consensus that gram negative bacteria and spirochetes are found to predominate the subgingival flora in patients with CsA GO, no clear relationship can be drawn as to the development and progression of GO. Perhaps one of the major difficulties is determining whether the change in microflora is a cause, or a consequence of the GO.

1.11.2 **Pharmacokinetics**

Regarding drug dosage and serum concentration of CsA, there does seem to be a consensus that a threshold concentration may be necessary for GO to occur.[13] Several studies have shown that 400ng/ml may be used as the threshold concentration needed for GO, however, some patients developed GO below this concentration.[75, 76] These studies, as well as others, point to a positive correlation between CsA blood concentration and incidence of GO.[63, 64, 75, 76] Contrasting data exists as well concluding no statistically significant link to serum concentration of CsA and GO.[77] While data seems to point to a correlation between drug serum concentration and development of GO, the specific concentration will most likely vary among individuals.[64, 69]

1.11.3 **Concomitant Medication**

As discussed previously, calcium channel blockers may be used in combination with immunosuppressants for transplant rejection in order to minimize the toxicity of immunosuppressants, as well as combat CsA-associated hypertension. In such cases, the combination can cause, or exacerbate the already present GO, which has been extensively studied.[7, 24, 28, 29, 78] Often times transplant patients are on more than one immunosupressant, and when CsA is used in combination with prednisolone and/or azathioprine, a decreased severity of GO has been observed.[7, 11, 64] The reasons for this have been hypothesized to be associated with a decreased dosage of CsA required to produce the desired effect, and the anti-inflammatory effect of both prednisolone and azathioprine.[54, 79, 80] Therefore it remains important for the oral health care provider and the physician to identify if alternative medication regimens can reduce the GO response.

1.11.4 **Age and Gender**

There have been multiple studies indicating children and adolescents are more at risk for CsA-induced GO.[76, 81-83] While the reason for the increased prevalence of GO has not been elucidated, it may be based on sensitivity of the young gingival fibroblasts to the medication.[46] Children have been found to heal more quickly, and with better regenerative capacity than older individuals, and this difference may accentuate the response to CsA in younger subjects.[84] Regarding gender, some of the available data points to an increase in prevalence and severity of GO in men,[85, 86] however, this finding is not universal, and studies indicate a female prevalence.[44, 64] Therefore, there seems to be a consensus that younger children and adolescents

exhibit greater prevalence of GO induced by CsA, however no clear conclusions can be drawn regarding gender as a major risk factor.

1.11.5 **Genetics**

Perhaps the fastest growing area of research regarding CsA GO is relating to genetic differences in those exhibiting GO versus those without this unwanted side effect. Gingival fibroblast heterogeneity has been well established in the literature,[6] and proposed as an explanation as to why only a subset of patients respond to CsA in this fashion. Theories regarding differences in fibroblastic activity in some individuals that have been proposed relate to: sensitivity to CsA, differences in proliferation rates, and synthesis and/or degradation of collagen and ECM components.[11, 13, 19, 87-89] These will be explored in detail in the following chapter. Also of note are the studies relating the potential role of human leukocyte antigens (HLA) phenotype as a risk factor for CsA GO. While some studies have reported HLA-DR2 may indicate an increased risk for development of CsA-induced GO, and HLA-DR1 can provide a degree of protection, these are very underpowered and therefore such definitive conclusions are questionable.[86, 90, 91] Additionally, no attempt was made to control for the effect of multiple significance testing in two of the three studies[90, 91], and when it was controlled, the relationship was not significant.[86] An increase in the presence of HLA-A19 antigen has also been reported in the literature; however, this too was found to be insignificant after correction for multiple significance testing.[92] The only factor identified as significant after correction for the effect of multiple significance testing is HLA-B37, and those carrying this antigen are more protected from GO.[86]

The fact remains that there is a variable gingival response to CsA in the form of GO or no GO based on the individual as a “responder” or “non-responder” respectively. This is most likely related to a multitude of factors including fibroblast variability/sensitivity to CsA, collagen/ECM degradation and synthesis variability, which may be genetically determined, but the specific genetic basis has not been explicated. Other potential possibilities include variance within the CYP450 genes such that differences in the metabolism of CsA may underlie patient susceptibility.

2. LITERATURE REVIEW

2.1 Proposed Etiologies of Cyclosporin A Gingival Overgrowth

The mechanism by which cyclosporine A causes gingival overgrowth is not yet fully understood, although many studies have been directed at understanding the etiology of CsA GO.[11, 13, 18] Investigators have hypothesized alterations in collagen and ECM metabolism, cytokine and chemokine levels, apoptosis, alterations in growth factors and predisposing genetic factors. To date, none of these has provided a comprehensive explanation. The following is a literature review of proposed or contributing etiologies for CsA induced GO.

2.2 Collagen and ECM Metabolism

Collagens are a group of fibrous structural proteins that are found in various connective tissues and within the extracellular matrix. They are the most abundant protein found in the body, and are composed of three separate peptide chains braided into a triple helix. Collagen synthesis is induced by a number of molecules including growth factors and cytokines that are secreted by fibroblasts and leukocytes.[9] The balance between collagen synthesis and degradation is necessary for proper metabolism and homeostasis, and a disruption in this balance can create conditions favoring increased amounts of collagen.[93]

An early study of collagen metabolism analyzed collagenase activity as measured in 14 different strains of human gingival fibroblasts (HGFs) taken from

healthy non-inflamed gingiva that were exposed to CsA. There was significant variance in the results in that most strains found CsA to decrease collagenase activity, however in some strains the drug caused no change, or significantly increased collagenase activities. The authors concluded that the differences in the collagenolytic response of different HGFs to CsA treatment may explain the susceptibility to gingival overgrowth.[94] These findings may provide insight into the variable results found throughout the literature on this topic as a whole. In essence, the susceptibility of gingival fibroblasts to CsA may be something that is an inherent, genetic trait that determines if the individual is either a “responder” or “non-responder” to CsA, phenotypically characterized by gingival overgrowth.

Studies of the direct effects of CsA on collagenous and non-collagenous extracellular matrix metabolism by gingival fibroblasts have provided variable results in culture, as well as in human and animal models.[45, 93-99] Deliliers et al. 1986 reported an increase in collagen related to four individuals on CsA based on gingival biopsies examined under light and electron microscopy. They proposed that “individual hypersensitivity” to CsA seemed to be the most acceptable explanation for GO.[98] Schincaglia et al. 1992 reported a direct stimulatory action of CsA on collagen synthesis from HGFs cultured from healthy gingival tissues.[97] More recent studies have examined collagen metabolism in HGF cultures as well as in gingival biopsies. Dannewitz et al. 2006 evaluated biopsies from five renal transplant patients displaying GO and five matched controls, and described an increased abundance of type I collagen in the GO tissues based on indirect immunofluorescence (IIF). An increase in type I collagen was also found at the transcriptional level via *in-situ* hybridization (ISH)

and quantitative polymerase chain reaction (qPCR).[60] Dannewitz et al. 2009 reported the effects of CsA on levels of collagen type I in gingival overgrowth-derived fibroblasts established as co-cultures with gingival keratinocytes as well as in matched gingival fibroblast monolayers. Compared with controls, based on quantitative real time polymerase chain reaction (RT-qPCR), collagen type I mRNA expression was increased in gingival fibroblasts, whereas this was not this case in keratinocytes.[88]

Other research has suggested that CsA treatment does not affect collagen synthesis in HGFs, however both of these studies used fibroblasts from healthy control patients not exhibiting GO.[95, 96] Similar results were seen in gingival biopsies taken from four renal transplant patients taking CsA. When these tissues were compared with gingival biopsies from healthy and inflamed tissues of patients not taking CsA, no difference was found in the volume density of fibroblasts or extracellular collagen present.[45]

Newell and Irwin 1997 observed that CsA stimulated glycosaminoglycan (GAG) synthesis in two of three HGF cell lines from overgrown tissue, and one of three cell lines from healthy tissue of subjects not taking any medications. These results were found to be cell-density and cell-strain dependent.[99] A more recent study reported findings related to the non-collagenous ECM, finding increased expression of heparin sulfate proteoglycans in gingival biopsies from CsA GO versus gingival biopsies from patients never exposed to the drug. Specifically, the findings included “a higher transcription of mRNA for syndecan-2, syndecan-4, and betaglycan in the [CsA] group compared with the control group.[100]

Connective tissue growth factor (CTGF) is part of the CCN family of factors that are associated with regulating the proliferation and differentiation of connective tissue cells and ECM accumulation.[101] Early studies relating CTGF to GO hypothesized that transforming growth factor beta-1 ($TGF\beta_1$) stimulated CTGF, which prompted gingival fibroblasts to increase production of ECM. Later *in vitro* studies of cell culture confirmed that CTGF was upregulated by $TGF\beta_1$, and collagen accumulation was increased in HGFs.[102] When comparing the expression levels of CTGF in tissue samples from patients taking phenytoin, CsA, or nifedipine, it was found that significantly higher levels were found in phenytoin samples.[103] This study also reported that CsA samples were not significantly different from control tissues. The samples sizes in this study were small (CsA= 5) however. Similarly, a subsequent paper reported that CsA stimulation of HGFs did not change the levels of CTGF based on reverse transcriptase PCR assay.[104]

While many studies have focused on the proliferative component of cell homeostasis, others have suggested that apoptosis, which serves to counterbalance mitosis, is a substantial player in the pathogenesis of GO.[105] Kantarci et al. 2007 determined that apoptosis was decreased in fibroblasts (in gingival biopsies) of all types of GO based on the presence of the cellular markers for apoptosis. Specifically they found decreased apoptosis based on terminal TdT-mediated dUTP-biotin nick-end labeling (TUNEL), decreased levels of caspase-3 (a molecule identified as a key mediator of apoptosis in mammalian cells) and increased levels of Forkhead box protein O1 (FOXO1) transcription factors (activation of FOXOs by dephosphorylation leads to cell cycle arrest) when compared to control tissues. Decreased apoptosis was

reported to occur in combination with an increase in fibroblast proliferation, and these simultaneous factors were believed to have contributed to the GO as downstream events.[106] Evaluation of gingival tissues from 14 renal transplant patients on CsA, 10 plaque induced gingivitis subjects, and 14 healthy control subjects by Buduneli et al. 2007 investigated the role of cell division rate and apoptosis on CsA GO. This was done by assessing Ki-67 antigen (present in the nuclei of proliferating cells and is a well-recognized nuclear proliferation marker) expression levels via immunohistochemistry, as well as determining the apoptotic cells via incubation with biotin-labeled 16-dUTP. Findings suggested that inhibition of apoptosis might be more crucial to development of CsA GO than increased mitosis.[107] The level of apoptosis was also examined in a paper by Bulut et al. 2005. Levels of p53 (protein well known to induce apoptosis in cells with severe DNA damage) and bcl-2 (know to prevent or markedly reduce cell death) were analyzed in 22 renal transplant patients and 15 healthy control subjects using immunohistochemistry and TUNEL. Although the levels of p53 and bcl-2 were not significantly different between groups, the CsA group showed a lower grade of apoptosis than the control group.[108]

One of the major hypotheses regarding pathogenesis of CsA GO is a disturbance in the homeostatic balance in fibroblasts and extracellular matrix components.[109] Matrix metalloproteinases (MMPs) are a group of enzymes that collectively degrade collagen and other constituents of the extracellular matrix. Their name refers to their functional dependence on zinc metal ions. Perhaps the most crucial role of MMPs in relation to GO is their ability to degrade the ECM.[9] Tissue inhibitors of matrix metalloproteinases (TIMPs) are the major regulators of MMP

activities in the body, and comprise of a family of four endogenous protease inhibitors.[87] As connective tissue homeostasis is maintained in part by the balance between MMP and TIMP activity, a number of studies have evaluated these gene families and their protein products.

A study that assessed the relative expression of MMP-1, MMP-10, and TIMP-1 in gingival tissue sections from CsA GO patients reported that expression of all three genes were elevated compared to healthy controls based on IIF and ISH. Assays using quantitative reverse transcription polymerase chain reaction (RT-qPCR) "indicated a 1.9-fold increase for MMP-1, a 2.3-fold increase for MMP-10, and a 4.8-fold increase for TIMP-1."[87] Another paper analyzed the gingival crevicular fluid (GCF) and serum levels of MMP-8 and TIMP-1 using time-resolved immunofluorometric assay (IFMA) and enzyme-linked immunosorbent assay (ELISA). This study included subjects taking CsA (25 exhibiting GO and 30 displaying no GO), and those not taking CsA (27 with gingivitis, and 40 healthy controls). They found that GCF MMP-8 levels were elevated in those on CsA with GO compared to those without, while TIMP-1 levels were relatively stable between groups. However, the levels of MMP-8 in CsA GO were similar to those with gingivitis, and this led the authors to conclude that inflammation is more responsible for the elevated levels of MMP-8 than CsA.[110]

Findings from *in vitro* studies have reported MMP suppression upon CsA stimulation of fibroblasts. Sonmez et al. examined gingival fibroblast cultures from subjects receiving CsA and exhibiting GO, and a second group taking CsA with no GO. They observed that increased CsA concentration appeared to suppress MMP-1 levels in both groups, leading to a conclusion that decreased MMP-1 expression may

play a minor role in the pathogenesis of CsA GO.[111] Hyland et al. compared groups of cultured fibroblasts from control subjects with no history of periodontal disease or CsA therapy to those on CsA exhibiting GO. Based on reverse transcription PCR (RT-PCR) and ELISA, CsA inhibited MMP-1 at both the mRNA and protein level in a dose and time-dependent manner. Findings for TIMP-1 expression were less clear, with CsA having very little effect on TIMP-1 at any concentration. The authors concluded that accumulation of collagen in CsA GO tissues might be associated with a decrease in collagen breakdown by MMPs.[112] A later study by Sukkar et al. 2007 similarly cultured gingival fibroblasts from healthy subjects and those on CsA with GO. In response to stimulation with IL-1 and oncostatin M (a pleiotropic cytokine belonging to IL-6 group), there was a significant increase in MMP-1, and this was reversed when cyclosporin and nifedipine were added to the cultures. A reduction in the ratio of MMP-1 to TIMP was also found. This led the authors to propose a synergistic relationship between pro-inflammatory cytokines changing the levels of MMP-1, with cylcosporine and nifedipine leading to suppression of MMP-1 levels. This would then lead to a decrease in the removal of collagen, and to the fibrotic state seen in drug-induced GO.[113] In prior studies, Yamada et al. 2000 cultured normal gingival fibroblasts and exposed them phenytoin or CsA. Both drugs were found to suppress the expression of MMP-1, TIMP-1 and cathepsin L (a protease found to be important in degradation of extracellular matrix components). This led to speculation that CsA and phenytoin affect both the gingival fibroblast as well as the homeostasis of the ECM components, through actions of MMPs, TIMPs and other proteases, chiefly lysosomal enzyme.[114]

The association of MMP-1 gene polymorphism with GO in renal transplant patients on CsA was also investigated. Sixty-one subjects on CsA with GO and 121 subjects on CsA without GO were recruited, and whole blood samples were taken. While the authors reported a trend for carriers of at least the -1607 1G allele to have a higher risk of gingival enlargement, it was not statistically significant. Realistically the study did not have power to make such a conclusion, and cannot be interpreted to quantify risk. Therefore, no association was found between the MMP-1 gene polymorphism and gingival enlargement in renal transplant patients on CsA.[109]

A handful of animal studies have examined expression levels of MMPs. Silva et al. 2001 analyzed the effect of CsA on the healing extraction socket of Wistar rats and found that both MMP-2 and 9 were inhibited in early granulation tissue formation.[115] In their experiments, Brook et al. 2005 found that the addition of CsA to male Sprague Dawley rats significantly decreased the expression of MMP-2, while MMP-9 remained unchanged. The decreased expression of MMP-2 was reversed with the addition of pirfenidone, an anti-fibrotic agent analyzed in the study.[116] Another animal study using male tufted capuchin monkeys determined the differential expression of MMP-1 and 2 when exposed to CsA, nifedipine, or phenytoin. Based on the drug given (CsA, nifedipine, or phenytoin), three groups of monkeys were studied to determine the different effects of the oral dosages of medications on the gingival tissues. At 52 days, there was a general trending decrease of MMP-1 expression in the tissues, while at day 120, a trending increase of MMP-1. MMP-2 levels were not significantly different at any time points. The authors suggested that the temporal differences in their findings may account for differences found in literature regarding findings and

extrapolation to propose mechanisms for drug-induced overgrowth, and that based on the stage of development, different biological markers may be expressed at varying degrees.[117] However, as this is an animal study, their results may be species specific as well. A study by Chiu et al. 2009 determined the affect of CsA on rat gingiva, as well as cultured fibroblasts. In this particular study CsA significantly decreased the expression of MMP-1 mRNA and protein, as well as MMP-2 protein, while no affect was seen on TIMP-2. In cultured gingival fibroblasts, CsA induced a decrease in MMP-2 activity in a dose-dependent manner. Taken together, these results led to the conclusion by the authors that CsA reduces the expression of MMP-1.[118]

In general the research evidence points to an increase in the amount of collagen production seen in tissues stimulated by CsA, as well as a decrease in the amount of apoptosis seen in these tissues. Regarding MMPs, there appears to be a general trend that CsA stimulation/administration leads to inhibition of MMPs, however, this may be dependent on the duration of time exposed to the drug, inflammatory status, as well as differences in study design. For example, *in vivo* studies where gingival overgrowth has been present for some time would invariably lead to an anaerobic gingival/periodontal pocket which itself may lead to an increase in bacteria and inflammatory cells secreting MMPs. Contrast that to cultured fibroblasts which are not subject to the oral environment and conflicting results are likely to be found, reflecting differences in experimental design that are not realily apparent. Therefore it seems that CsA itself may be suppressing MMP expression, however, when faced with a clinical scenario, the inflammatory status may have more influence in the expression levels, and so at this time more evidence is required on

this topic. The importance of TIMPs and CTGF seems to be even less clear, and more focused studies are necessary with greater sample sizes.

2.3 Cytokine/Chemokine Involvement in Gingival Overgrowth

Cytokines are proteins known to modulate the functions of other cells, and are most notably produced during immune and inflammatory responses, and also have multiple other well-established functions throughout the body.[5, 17, 101, 119] They act as chemoattractants for many cell types, influence the growth and differentiation of precursor cells, and stimulate chemotaxis. Activated lymphocytes and macrophages are the main producers of cytokines, although multiple other cell types including epithelial and endothelial cells generate cytokines as well.[9] Determining the exact function of cytokines can be complex as it may vary depending on the producing cell, the responding cell type, and potentially the type or phase of immune response.[120]

Secretion of cytokines is typically transient and very tightly regulated, and their effects tend to be pleiotropic, that is one cytokine can affect different cells in two different ways. Cytokines can be redundant as different cytokine proteins may stimulate the same activity.[9] In general, cytokines can be grouped into five classes based on their target cells. These groups include cytokines that: mediate innate immunity, regulate lymphocyte function, activate inflammatory cells, act to stimulate hematopoiesis, and cytokines that are chemokines and act to recruit inflammatory cells to sites of tissue injury. Many growth factors are cytokines, which can induce fibroblast proliferation. Furthermore, cytokines may be chemotactic for fibroblasts and

induce the production of collagen and collagenase, the net result of which tends to be fibrogenic.[9]

Chemokines are small secreted proteins, typically from 60-90 amino acids long, which were traditionally thought to act primarily as activators and chemoattractants for subsets of leukocytes for immune system functioning.[9, 12, 121] The name itself is derived from the combination of the terms “chemotactic” and “cytokine.” More recently, additional functions of these proteins including fibroblast activation and angiogenesis have been discovered in tissue fibrosis of many different organ systems. The etiologic basis of fibrosis of the liver, kidney, skin, and lung have been found in human and animal models to be mediated by chemokines.[119] Chemokines contain four highly conserved cysteine residues, and the pattern of the N-terminal cysteine residue is used to classify them into 4 families (CC, CXC, XC and CX_3C).[121, 122] The CC chemokines are the largest family, and in general are chemoattractive for monocytes and leukocyte subsets. The structural difference between the CC and CXC families are subtle, however, this small difference correlates with rather significant functional roles. Typically, CXC chemokines are chemoattractive for neutrophils, and this family can be further subdivided into ELR+ and ELR- based on the presence of a tripeptide motif Glu-Leu-Arg.[121, 122] The following are examples of cytokines and chemokines reported to be associated with the pathogenesis of CsA-induced GO.

2.3.1 **TGF-β**

Members of the TGF-β superfamily affect many different cell types with a wide range of biological consequences including: cell growth regulation, differentiation,

matrix production, and apoptosis. This family of cytokines is comprised of the TGF-βs, activins, inhibins, bone morphogenic proteins (BMPs), Müllerian-inhibiting substance, decapentaplegin, and Vg-1.[123] TGF-β_1, TGF-β_2, and Smad7 (TGF-β_1 receptor antatgonist) have each been studied to determine their role in the pathogenesis of CsA GO. TGF-β_1 is mainly released by platelets, however other sources include monocytes/macrophages, endothelial cells, and fibroblasts. It has been shown to play a large role in wound healing as an inflammatory mediator with multiple functions including regulating cell proliferation and differentiation,[124] and is strongly linked to fibrosis in a number of diseases.[17] In one study using CsA-stimulated gingival fibroblasts, and another analyzing saliva from patients undergoing CsA treatment after kidney transplants, it was found that CsA regulates the transcription of TGF-β_1.[125, 126] This suggests that TGF-β_1 acts in an autocrine manner to assist in decreasing the proteolytic activity of HGFs in CsA-induced GO.

Chae et al. 2006 examined the amount of TGF-β_1 expressed by gingival fibroblasts after being exposed to CsA, as well as signal transduction of CsA-induced gingival fibroblast proliferation. They found that not only was TGF-β_1 upregulated by CsA, but CsA also induced gingival fibroblast proliferation via the p38 MAPK and PI3K pathways, which were found to be essential for gingival fibroblast proliferation.[5] These findings suggest that CsA can directly affect MAPK signaling. MAPK signal transduction is important in gingival fibroblast proliferation, and is directly involved in hereditary gingival overgrowth syndromes, as found in *SOS1* associated hereditary gingival fibromatosis (HGF1) and Noonans syndrome due to RAS mutations.[14, 127]

A recent *in vitro* study examined CsA stimulation of both normal HGFs and those overexpressing Smad7. While CsA induced production of TGF-β_1 in both cell lines, the Smad7-overexpressing cells produced significantly less TGF-β_1. This was expected, as SMAD7 is the TGF-β_1 receptor antagonist. Also, the effects of CsA on cell proliferation, type-I collagen production, and inhibition of MMP-2 were significantly blocked in the Smad7-overexpressing fibroblasts versus the CsA-stimulated normal fibroblasts. This suggests that Smad7 overexpression is effective at blocking the actions of CsA on cell proliferation and collagen/ECM metabolism.[128] A separate study assessed expression levels of TGF-β RII (an important receptor for TGF- β that is involved in signal transduction) in GO tissues from patients on CsA. The results showed TGF- β RII was expressed similarly in patients with GO and those without GO on CsA therapy, and the authors concluded perhaps it does not have a role in CsA induced GO, however, TGF-beta RI or RIII may mediate the process.[129]

Interestingly, two separate studies have reported that TGF-β_1 levels in GCF of those on CsA exhibiting gingival overgrowth were similar to sites that did not exhibit GO.[124, 130] The Buduneli et al. 2001 paper did note an overall increase in the GCF levels of TGF-β_1 in those taking CsA compared to healthy controls, however, because there was no statistically significant difference between the CsA GO and CsA no GO groups, it was determined that TGF-β_1 may not be involved in the pathogenic mechanism of this side effect.[124] Similar results were found in a study examining levels of TGF-β_1 in GCF which found that patients on CsA without GO had a significant increase in GCF levels of TGF-β_1 compared to gingivitis and healthy control patients.[131] This seems to support the results found in the Buduneli et al. 2001 study in

that they are not excluding TGF-β_1 as a player in the pathogenesis of CsA-induced GO.

Another paper measuring expression of TGF-β_1 did so using the peripheral mononuclear cells of patients taking CsA with and without GO. They reported that TGF-β_1 gene expression was significantly lower in the patients with a greater frequency, higher degree, and larger extent of GO.[132] This study could not point to low TGF-β_1 expression as the primary reason for GO. A previous study by the same author looking at TGF-β_1 polymorphisms attempted to explain patient specificity associated with CsA GO, a theme that has often been suggested throughout the literature. The main observation was an insignificantly higher TGF-β_1 plasma level in patients treated with CsA compared with healthy controls.[133] While these two studies tested the expression of TGF-β_1 in different cell types, it is of note that CsA affected these tissues differently. Additionally, the use of peripheral blood monocytes may not reflect local events in the gingival tissues, and therefore extrapolation of results must be considered carefully.

There have been multiple animal studies showing increased expression of TGF-β_1 in rats receiving CsA.[104, 134-136] The Chen et al. group administered CsA to edentulous Sprague-Dawley rats and observed gingival overgrowth (based on height and width of the edentulous ridge) as well as a higher mRNA expression of TGF-β_1 and VEGF. Spolidorio et al. 2005 showed a significant increase in TGF-β_1 expression in the saliva of Holtzman rats after 60 days of treatment with CsA in which GO was seen in all gingival areas.[135] A study by the same group found an increase in salivary TGF-β_1 in Wistar rats treated with CsA for 60 and 120 days, however, found significant

decreases in TGF-β_1 levels after 180 and 240 days.[136] The results suggested to the author a decrease in TGF-β_1 with prolonged CsA therapy indicated an increase in the proteolytic activity of gingival fibroblasts, which favored normal extracellular matrix production.

Therefore, based on the available evidence it seems that there is no consensus regarding the effect of CsA on levels of TGF-β_1, and findings show temporal variance. In general, it appears that there is a trend toward an overexpression or upregulation of TGF-β_1 resulting from CsA stimulation; however, more research on this cytokine is necessary.

2.3.2 **Interleukins (IL-1a, IL-1b, IL-6, IL-8)**

Interleukins (ILs) are a large group of cytokines that were first discovered to be secreted by leukocytes. As immunomodulatory proteins, they elicit a wide variety of responses in cells and tissues by binding to their high affinity receptors located on cell surfaces. ILs act in an autocrine or paracrine fashion and may modulate cell growth, activation, and differentiation. [120] A few members of the IL family act as chemoattractants for other cells, and IL's can have both inflammatory and anti-inflammatory effects.[120]

In a paper already discussed in which researchers examined the amount of TGF-β_1 expressed by gingival fibroblasts after being exposed to CsA, as well as signal transduction of CsA-induced gingival fibroblast proliferation, IL-6 was also a cytokine of interest. It was found that in addition to inducing increased gingival fibroblast proliferation via the p38 MAPK and PI3K pathways, CsA upregulated both TGF-β_1 and

IL-6.[5] A similarly designed study found that when gingival fibroblasts derived from GO tissue were treated with CsA, they produced significantly more IL-6 than control cells. This study , which also examined levels of IL-1β in CsA treated and in control cells, determined IL-1β expression was not found in measurable quantities in either group.[89] An additional paper examining CsA stimulation on gingival fibroblasts' IL-6 secretion found that CsA enhanced the expression of IL-6, and that in the presence of IL-1β, the effect was compounded.[137]

One interesting study on GCF concentrations of IL-1β and IL-6 found that both were expressed in greater quantities in the presence of inflammation, regardless of GO+ or GO- subjects. Also, IL-1β and IL-6 levels were significantly higher in inflamed CsA GO- sites compared to non-inflamed CsA GO+ sites. These findings led the authors to conclude that CsA does not directly increase levels of IL-6 and IL-1β in the GCF, and that gingival inflammation may play a significant role in the process.[138] Another paper assessing the levels of IL-6 examined its expression in gingival tissues of patients on CsA exhibiting GO, and found significantly greater levels of IL-6 protein and mRNA when compared to control tissues.[139] Also, Suzuki et al. sought to determine whether CsA altered the inflammatory response in HGFs that were cultured from healthy donors not taking any medication. They found that while CsA did not induce evident inflammatory responses, it enhanced IL-6 and IL-8 production and CD54 expression in HGFs stimulated with synthetic TLR ligands.[140]

Two studies examined the association of an *IL-6* 5' regulatory gene polymorphism (rs1800795) with the occurrence of GO in renal transplant patient taking CsA.[141, 142] Both came to the conclusion that there was no association between this *IL-*

6 gene polymorphism and GO in these patients. A study investigating the association of *IL-1A* gene polymorphism reported that "carriage of the polymorphic allele at position -889 of *IL-1A* was found in a significantly higher proportion in GO- patients (64%) than GO+ patients (32%)."[66] This same study noted that IL-8 was detected in the GCF of CsA treated patients, and that it was upregulated, but not significantly associated with GO.[66]

To date, there have only been a few studies measuring the expression of IL-8 in tissue from patients on CsA displaying GO. IL-8 was originally discovered as one of the first chemokines activating neutrophil granulocytes after secretion by lipopolysaccharide (LPS)-stimulated monocytes. Since then, the role of IL-8 has been studied in many physiologic and pathophysiologic processes.[4, 143-145] Extensive research has been done on IL-8 as a biomarker for various types of cancers, as well as in other fields of medicine. Many of these conditions are inflammatory diseases for which IL-8's involvement is based on its action as an inflammatory mediator, while with other conditions the link to inflammation is less clear.[145]

Thus, based on the limited amount of data evaluating the expression levels of interleukins in CsA-induced GO, there does not seem to be a consensus regarding the effect of CsA on these cytokines. While there is a general trend toward increased expression of IL-1β and IL-6, and IL-8, more research is warranted on this topic.

2.3.3 **PDGF**

Platelet-derived growth factor (PDGF) is a protein growth factor that regulates cell growth and division. PDGF functions as a dimeric polypeptide that consists of A

and B chains as a homodimer (AA, BB), or a heterodimer (AB). The B chain is an important mitogen, and major chemoattractant for fibroblasts that induce fibroblast proliferation and synthesis of key components of the extracellular matrix (glycosaminoglycans, proteoglycans, fibronectin, and collagen).[146] One of the ways this is accomplished is via activation of signal transduction pathways by PDGF-B.[147] Its role in CsA GO has been investigated by several studies.

Groups from Baylor College of Dentistry in Dallas, Texas published three papers that evaluated the differential expression of PDGF-B as a result of CsA therapy.[146, 148, 149] Two of these studies reported that the gingival samples of patients taking CsA and presenting with GO had an upregulation of PDGF-B expression produced by macrophages, as compared with normal controls.[148, 149] A study by Iacopino et al. 1997 was done differently in that rat macrophages and human monocytes were cultured and exposed to CsA, then the differential expression of PDGF-B was determined. This study also found that CsA exposure induced an increased expression of PDGF-B in these monocytes and macrophages.[146]

2.4 Epithelial-Mesenchymal Transition

Epithelial-mesenchymal transition (EMT) is a known mechanism for dispersing cells in vertebrate embryos as part of normal development.[16] EMT has also been reported as a mechanism for initiation of metastases in cancerous epithelial cells and a mechanism to induce fibrosis through the generation of fibroblasts after tissue injury in pathologic conditions.[16] In the gingiva, epithelial cells undergoing EMT can gain motile characteristics and are able to invade through the basement membranes. They

trans-differentiate from an epithelial cell to a fibroblast-like cell, and contribute to the production and accumulation of the ECM.[15, 150] Histologically, the appearance of attenuated and deep elongated rete pegs extending into the connective tissue in drug-induced GO[38, 56, 58] led some to speculate the involvement of EMT in these conditions,[150] whereby epithelial cells invade the underlying connective tissue and become fibroblast-like cells, producing components of the connective tissue.

During the process of EMT, the epithelial cells decrease their expression of proteins associated with the epithelial phenotype, and increase expression of proteins associated with mesenchymal origin.[15] One experiment sought to measure the expression levels of these proteins in order to determine if EMT played a role in medication-induced GO. Specifically in CsA GO tissues, results indicated decreased levels of E-cadherin compared to controls, indicating decreased function in maintaining the integrity of cell-cell contacts and cell barrier function which is a consistent feature in EMT. Furthermore, these tissues were found to have an increased level of fibroblast-specific protein-1 and fibronectin, two specific markers for fibroblasts. Levels of αvβ6 integrin, a specific marker known to promote EMT and mediate cell-cell and cell-ECM interactions, did not show any significant differences compared to control tissues. This study also conducted experiments in vitro, and found that cultured primary human gingival epithelial cells treated with TGF-β1 were induced to undergo changes consistent with EMT.[15] These results taken together led the authors to conclude that EMT does play a role in drug-induced GO. Follow-up studies have found that alterations in the basement membrane integrity is found more frequently in drug-induced GO tissues based on gross histologic evaluation, as well as

immunohistochemical staining for type IV collagen (major basement membrane collagen) and laminin 5 (an important adhesive glycoprotein within the basement membrane).[150] These changes were noted regardless of the presence of inflammatory cells in phenytoin and nifedipine-induced GO, however, not for CsA GO. In CsA GO tissues, there was no difference in the number of basement membrane discontinuities when compared to inflamed control specimens.[150]

The evidence available demonstrates that EMT may be important in all forms of drug-induced GO, including CsA GO. Transition of epithelial cells, as well as other cell types, into an "active fibroblast" or myofibroblast which secretes collagen and other ECM components has been reported in other tissues of the body including renal, hepatic, and lung.[151-153] There is cause to believe this process is happening in CsA-induced GO as well, and further research is necessary to confirm some of these initial findings in the dental literature.

2.5 **Signal Transduction Pathways**

Mitogen-activated protein kinases or MAP kinases are serine/threonine-specific protein kinases that are involved in directing cellular responses to many different stimuli such as mitogens, osmotic stress, heat shock, and pro-inflammatory cytokines. By passing signals from the outside of the cell to the nucleus, signal transduction pathways regulate many cell functions, including proliferation, gene expression, differentiation, mitosis, and apoptosis.[9]

Within the MAPK signaling pathway is the Son of sevenless-1 (*SOS-1*) gene, whose genomic structure has been described in detail. Hereditary gingival

fibromatosis (HGF) is a Mendelian form of gingival overgrowth that follows an autosomal dominant pattern of inheritance, of which at least 4 forms have been described based on genetic loci mapped by linkage studies.[154] The genetic locus for HGF1 has been localized to chromosome 2p21-p22, while HGF2 has been localized to chromosome 5q13-q22. Previous research has shown a mutation of the *SOS-1* gene is responsible for HGF1. The insertion mutation causes a frameshift that produces a premature stop codon, truncating the *SOS1* protein and deleting the functionally important proline-rich SH3 binding domains on *SOS-1.* The end result of this mutation is that SOS-1 protein is constitutively active, and this drives the MAPK signaling pathway to increase cell proliferation and differentiation.[14]

As previously reviewed, Chae et al 2006 found that CsA induced gingival fibroblast proliferation via the p38 MAPK and PI3K signal transduction pathways. These MAPK signaling pathways were shown to play an important role in the release of IL-6 and TGF-β_1, and have been shown to be essential for CsA induced proliferation. This signal transduction pathway may serve as a strategic target for regulating the CsA-induced TGFβ -1 and IL-6 production, and the cell proliferation and GO that ensues.[5] Furthermore, it has been shown that CsA increases the binding activity of the transcription factor activator protein-1 (AP-1) in HGFs.[155] This transcription factor been associated with an increase in ERK-1 and ERK-2 MAPK pathways, and is directly linked to IL-8 upregulation by CsA.[144]

2.6 **Tissue Fibrosis**

Tissue fibrosis is a generic term that is used to describe the overgrowth, hardening, and/or scarring of various tissues and is a result of excess deposition of ECM components such as collagen.[17] Both drug-induced and genetic forms of GO have been described as a fibrotic tissue overgrowth based on clinical and histologic characteristics that resemble fibrotic changes in other tissues throughout the body.[11, 13-15] Fibrosis in other tissues has been the subject of extensive research over the years, and the medical literature provides great insight into the potential mechanisms that may be involved in gingival tissues.

In response to tissue wounding or a stimulus of some kind, regeneration of injured tissue by parenchymal cells of the same type takes place, as well as replacement by connective tissue resulting in fibrous tissue. In most cases tissue repair cannot be accomplished with regeneration alone, and the non-regenerated parenchymal cells are replaced with connective tissue. This occurs in a systematic fashion with four components: angiogenesis, migration and proliferation of fibroblasts, deposition of extracellular matrix, and remodeling of the fibrous tissue.[12] These four processes can each be altered, and pathologic fibrosis can ensue. In cases where tissue injury is chronic rather than acute, the balance between ECM production and degradation is skewed towards accumulation of scar tissue.[119]

Many molecules have been proposed as important regulators of fibrosis. These molecules include for example: growth factors, cytokines, chemokines, caspases, peroxisome proliferator-activated receptors, angiogenic factors, acute phase proteins, and components of the renin–angiotensin–aldosterone system. As discussed earlier,

chemokines act not only as stimulants and chemoattractants for subsets of leukocytes for immune system functioning, but also fibroblast activation and angiogenesis.[119, 121] Chemokines also work in concert with profibrotic cytokines in the creation of fibrosis through recruitment of myofibroblasts and their progenitor cells to sites of tissue injury. Many chemokine signaling pathways are involved in the fibrogenesis pathway, and have been associated with important regulatory roles as well.[17]

2.6.1 **Chemokines and Their Involvement in Tissue Fibrosis**

There is an increasing amount of literature analyzing the roles of chemokines in tissue fibrosis of various types. In many cases, tissue fibrosis in these organ systems can have fatal consequences due to the decreasing amount of functional tissue. Liver fibrosis is typically characterized by inflammation, angiogenesis, tissue remodeling, and hepatocellular necrosis, and ultimately may result in hepatocellular carcinoma, or more commonly, cirrhosis. Hepatic resident cells express many chemokines, and these chemokines drive the influx of leukocytes and specific immune cells to the site of injury, leading to hepatic fibrogenesis.[119] Hepatic stellate cells (HSCs) are a major player in hepatic fibrosis due to their ability to secrete large amounts of ECM proteins. HSCs are pericytes, which are known sources for myofibroblasts. They occur naturally as contractile cells which wrap around endothelial cells of capillaries and venules, and respond to stimulation and vessel injury by proliferating and differentiating into collagen-producing cells.[156] These cells are known to express many chemokines which can act as stimulation for differentiation, including the CC chemokines CCL2, CCL3, CCL5, and the CXC chemokines CXCL8, CXCL9, CXCL10 and CXCL12.[119]

Pulmonary fibrosis also involves the deposition of excess ECM proteins, as well as exaggerated angiogenesis, and abnormal inflammatory wound healing. Scarring of the lung is mainly brought on by fibroblasts, myofibroblasts, and fibrocytes, and at later stages is associated with an increase in mortality due to loss of alveolar elasticity. Pulmonary hypertension and respiratory failure are two common end stage conditions that affected patients will battle. Pro-inflammatory cells and alveolar epithelial cells are known to release a number of chemokines, including the CC chemokines CCL2, CCL3, CCL5, CCL11, and the CXC chemokines CXCL2, CXCL5, and CXCL12.[119]

Similarly, renal fibrosis can lead to loss of function due to glomerulosclerosis and destructive interstitial fibrosis. Initiation of the fibrotic process can be traced to fibroblasts, tubular epithelial cells, and vascular endothelial cells, with activated renal fibroblasts leading to increased deposition of ECM. Specific chemokines have been identified in these biologic processes, and include CCL2, CCL5, and CXCL10.[119]

Dermal fibrosis reviewed in the literature deals mostly with scleroderma, or more specifically, systemic sclerosis. Three separate pathologic processes that include autoimmune inflammation, fibrosis, and angiogenesis characterize this condition. The pathogenesis of scleroderma seems to involve leukocytes, endothelial cells, and fibroblasts; chemokines have been recognized as significant mediators of leukocyte trafficking into sclerotic skin. Chemokines shown to play roles in dermal fibrosis include CCL2, CCL3, CCL5, CCL7, CCL17, CCL22, CCL27, CXCL1, CXCL8, and CXCL16.[119]

3. HYPOTHESES AND OBJECTIVE

3.1 Hypotheses

CsA is an immunosuppressant that has been shown to differentially regulate the expression of multiple genes as part of its main therapeutic function.[36, 37] Differential expression of these genes within the gingival tissues has been well established in the literature both *in vitro* and *in vivo*. Based on observations that chemokines play a significant role in fibrosis literature within other organ systems including skin, lung, kidney, and liver, it is reasonable to consider chemokines may act in a similar fashion in the gingiva. Additionally, a mutation in *SOS-1* gene (within the MAPK/ERK pathway) has been shown to be etiologically important in subjects with HGF1, and there is potential for chemokines to drive a similar pathway. We hypothesize that CsA induced differential gene expression in the chemokine ligand-receptor axis, specifically *CXCL8* and *CXCR1*, is etiologically important for CsA induced GO, and the objective of this study is to identify differentially expressed genes in the chemokine ligand-receptor axis that may drive CsA GO.

4. METHODOLOGY

4.1 Patients

For tissue acquisition, informed consent was obtained from the patients according to the Helsinki Declaration, and the protocol was approved by the institutional ethics committee. 14 CsA-treated renal transplant patients (taken from a larger study group n = 125), ages 23-43 years, who attended the Department of Periodontology, School of Dentistry, Ege University, (Izmir, Turkey) were selected for the study. Subjects were medicated with CsA for a minimum of 6 months, and drug serum concentration was controlled between 80-300ng/ml based on level of therapeutic effect for the given individual. While CsA treated patients also received azathioprine and prednisolone, the presence of other drugs known to cause GO were grounds for exclusion from the study. No relevant pre-existing medical or drug histories were cited during the 6 months previous to the study, and the tissue was free from plaque-induced inflammation based on dental cleanings every 2 weeks.

Clinical parameters of this study population have been described in detail previously:

> "Assessment of clinical periodontal parameters was made of the full dentition, excluding third molars. All subjects had a clinical periodontal examination including the measurement of periodontal probing depth using a Williams probe. Dichotomous measurement of supragingival plaque accumulation[157] and bleeding on probing [158] and hyperplastic index scores were also recorded The degree of

gingival overgrowth was classified into four categories based on the criteria of Angelopoulos and Goaz 1972[51] modified by Pernu et al. 1992.[44] The patients were dichotomized into a gingival overgrowth-negative (GO-) group, those with no signs of gingival overgrowth (score 0), and a gingival overgrowth positive (GO+) group, those with signs of overgrowth (scores 1-3) for analysis."[66]

Radiographic examination was performed using panoramic films to detect alveolar bone loss. The patients with no radiographic evidence of bone loss (defined as the distance between the cemento-enamel junction and bone crest at >95% of the proximal tooth sites ≤ 3mm) were included in the study.

4.2 Gene Expression Studies

4.2.1 Tissue Collection

Gingival tissue specimens were taken from the anterior interdental area, where the tissue revealed characteristic signs of GO. Normal gingival tissue was obtained from three healthy patients during crown lengthening surgery in which the excess tissue would have normally been discarded. The tissues were then stored in RNAlater in order to stabilize the RNA for reliable gene expression and gene profiling data.

4.2.2 Isolation of RNA

Total RNA was extracted from gingival biopsies using TRIzol. RNA quality was assessed and verified by the presence of robust 18S and 28S peaks by electrophoresis on the Agilent 2100 Bioanalyzer (Agilent Technologies, Palo Alto, CA).

4.2.3 **Microarray Preparation**

Gene expression was determined using the CodeLink™ Whole Human Genome Gene arrays (Applied Microarrays, Inc. Temple, AZ).

4.2.4 **Data Analysis**

Utilization of the GenePix Series B Scanner (Axon Instruments) allowed for detection of desired probes within the microarray. CodeLink™ Expression Analysis v5.0 was used for probe quantitation. Each array was individually scaled in order to convey intensity, and normalization to the median was completed.

4.2.5 **Gene Ontology and KEGG Pathway Analysis**

GeneSifter software (Geospiza, Seattle, WA, USA) was utilized to observe expression of the normalized values. Upon observation of specific genes or gene products that were significantly upregulated or downregulated, ontological pathways[159] and the Kyoto Encyclopedia of Genes and Genomics (KEGG) pathways[160] were explored in order to provide further biological significance. A pathway was determined to be significantly different if its *z* score was <-2 or >2.[159, 160]

5. RESULTS

5.1 Patients

Gingival tissue samples were obtained from 14 renal transplant subjects and 3 healthy control subjects not taking CsA. Based on the hyperplastic index, 3 of the 14 transplant patients did not exhibit GO, while 11 patients were GO+.

5.2 Microarray Analysis

Codelink™ Human Whole Genome microarrays queried the expression of ~50,000 genes. Median-normalized expression values were analyzed using the GeneSifter (Geospiza, Seattle, WA, USA) software enabling identification of differentially expressed genes. Genes were also analyzed using KEGG to indicate pathways and biologic processes that may demonstrate significantly altered gene expression.

5.3 Identification of Individual Genes that are Differentially Expressed in Cyclosporin A Gingival Overgrowth

Multiple genes of interest were identified based on previous literature regarding CsA-induced GO, as well as mechanisms that have been elucidated for HGF1 (described earlier). It was immediately apparent that CsA caused differential expression of a variety of cytokines and chemokines, some of which have not been described in the literature. For a compiled list, refer to Appendix Q.

5.4 IL-8 and IL8RA

Of particular note was the differential expression of IL-8 (Table I and Figures 3 and 4) and its high-affinity receptor IL-8RA (Table I and Figures 3 and 5). While all patients taking CsA demonstrated significantly upregulated IL-8 by a factor of 40-50 fold regardless of their GO status, only those individuals that were GO+ displayed increased expression of IL-8RA (approximately 5 fold). This pattern was noted in other chemokine ligands and receptors as well. For stratification and detailed evaluation of the data, the CsA GO group was also divided into 3 subgroups. These can be found in Table II and figures 7-10.

Table I
RELATIVE EXPRESSION OF IL-8 AND ITS RECEPTORS

Gene	Control (n=3)	CsA no GO (n=3)	CsA GO (n=11)
IL-8 (CXCL8)	0.16 ± 0.03	6.26 ± 1.71*	8.44 ± 1.88*
IL-8RA (CXCR1)	0.06 ± 0.03	0.07 ± 0.01	0.34 ±0.09*
IL-8RB (CXCR2)	0.28 ± 0.01	0.41 ± 0.09	0.45 ± 0.05

*P<0.05. (CsA no GO= Cyclosporin A without gingival overgrowth, CsA GO= Cyclosporin A with gingival overgrowth, IL-8 (CXCL8= Interleukin-8, IL-8RA (CXCR1)= Interleukin-8 receptor alpha, IL-8RB (CXCR2)= Interleukin-8 receptor beta)

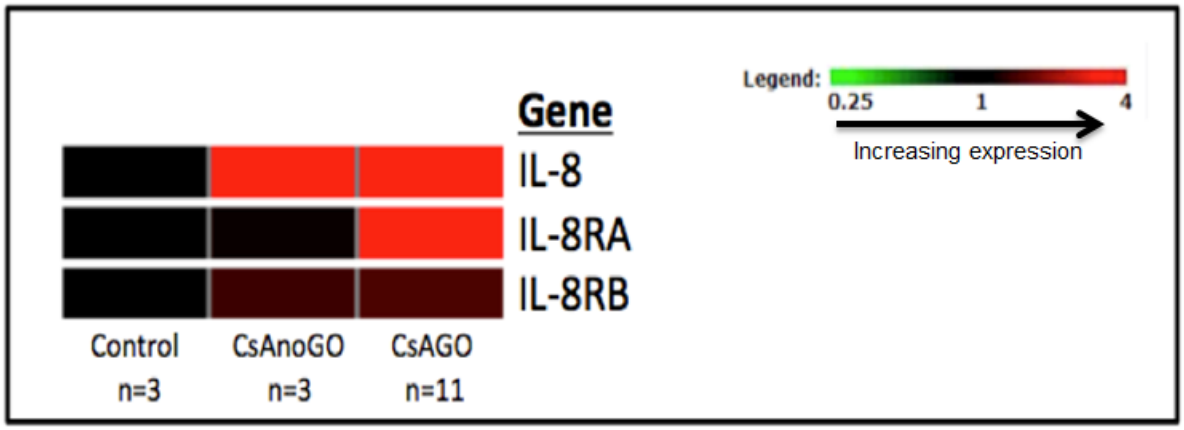

Figure 3. Heat map illustrating expression of IL-8 and its high and low-affinity receptors, IL-8RA and IL-8RB.

IL-8 is significantly upregulated in both CsA groups, while IL-8RA is significantly upregulated in CsA GO group only. (CsAnoGO= Cyclosporin A without gingival overgrowth, CsAGO= Cyclosporin A with gingival overgrowth, IL-8= Interleukin-8, IL-8RA= Interleukin-8 receptor alpha, IL-8RB= Interleukin-8 receptor beta.)

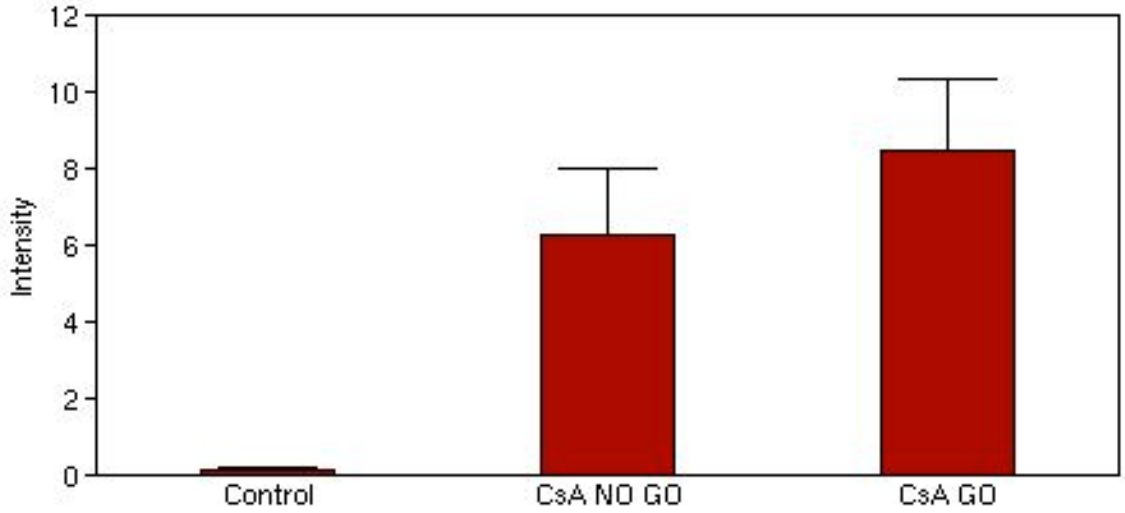

Figure 4. Differential expression of IL-8.

IL-8 is significantly upregulated in both CsA GO and CsA NO GO groups. Intensity= mean-normalized quantitative expression of IL-8. (CsAnoGO= Cyclosporin A without gingival overgrowth, CsAGO= Cyclosporin A with gingival overgrowth.)

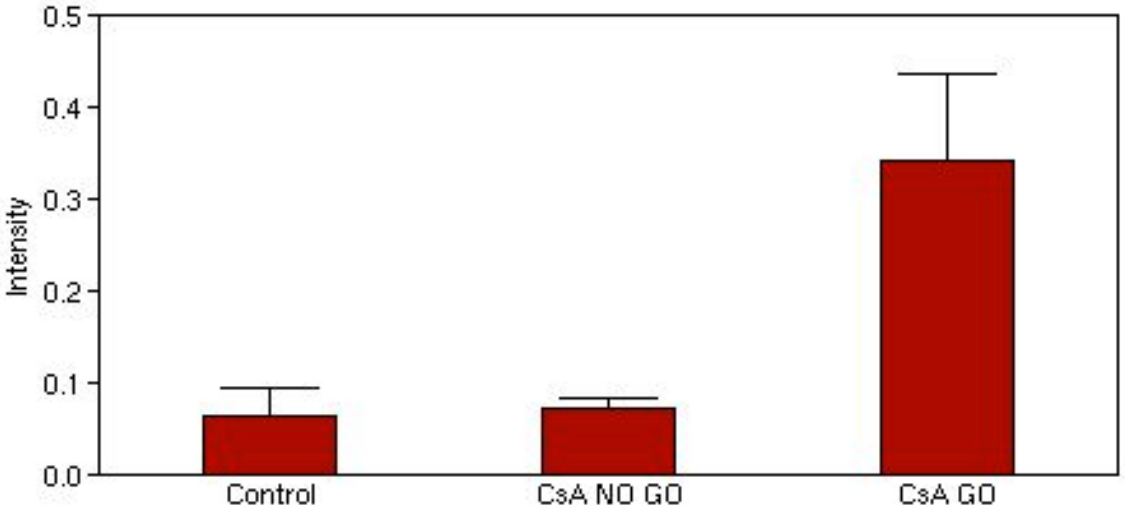

Figure 5. Differential expression of IL-8RA (CXCR1).

IL-8RA is significantly upregulated in CsA GO group only compared to normal controls. Intensity= mean-normalized quantitative expression of IL-8RA. (CsAnoGO= Cyclosporin A without gingival overgrowth, CsAGO= Cyclosporin A with gingival overgrowth.)

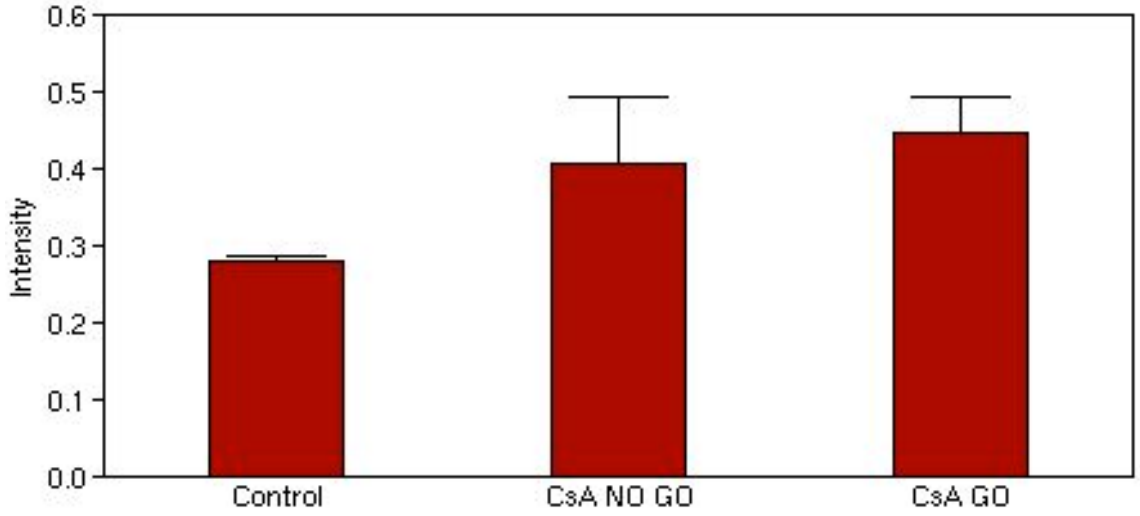

Figure 6. Differential expression of IL-8RB (CXCR2).

Expression of IL-8RB in CsA GO group and CsA NO GO group is not significantly different from control. Intensity= mean-normalized quantitative expression of IL-8RA. (CsAnoGO= Cyclosporin A without gingival overgrowth, CsAGO= Cyclosporin A with gingival overgrowth.)

Table II

RELATIVE EXPRESSION OF IL-8 AND ITS RECEPTORS

Gene	Control (n=3)	CsA no GO (n=3)	CsA GO 1 (n=4)	CsA GO 2 (n=4)	CsA GO 3 (n=3)
IL-8	0.16 ± 0.03	6.26 ± 1.71*	11.14 ± 4.70*	8.39 ± 1.96*	4.92 ± 1.50*
IL-8RA (CXCR1)	0.06 ± 0.03	0.07 ± 0.01	0.38 ± 0.20*	0.42 ± 0.18*	0.19 ± 0.03*
IL-8RB (CXCR2)	0.28 ± 0.01	0.41 ± 0.09	0.45 ± 0.10	0.47 ± 0.10	0.40 ± 0.06

CsA GO group has been divided into 3 subgroups for stratification of data and detailed evaluation. *P<0.05. (CsA no GO= Cyclosporin A without gingival overgrowth, CsA GO= Cyclosporin A with gingival overgrowth, IL-8 (CXCL8= Interleukin-8, IL-8RA (CXCR1)= Interleukin-8 receptor alpha, IL-8RB (CXCR2)= Interleukin-8 receptor beta.)

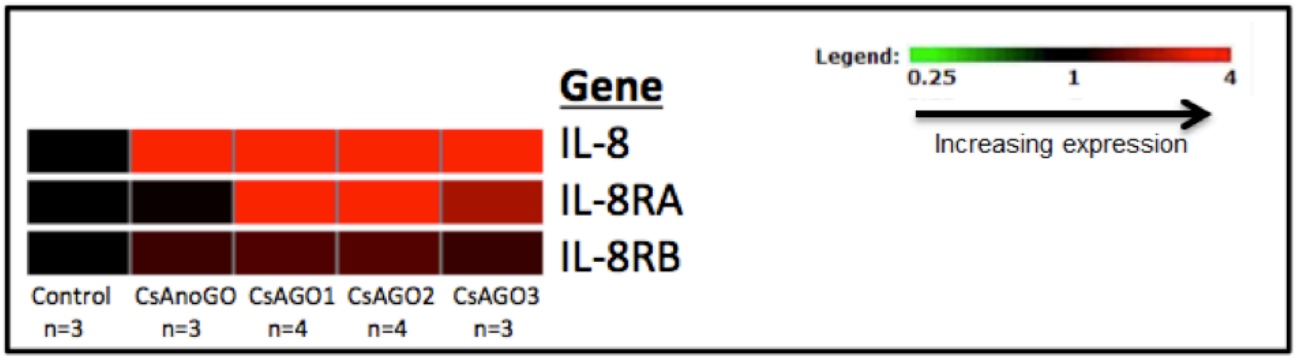

Figure 7. Heat map associated with expression of IL-8 and its high and low-affinity receptors, IL-8RA and IL-8RB.

CsA GO group has been divided into 3 subgroups for stratification of data and detailed evaluation. IL-8 is significantly upregulated in both CsA groups, while IL-RA is significantly upregulated in CsA GO group only.

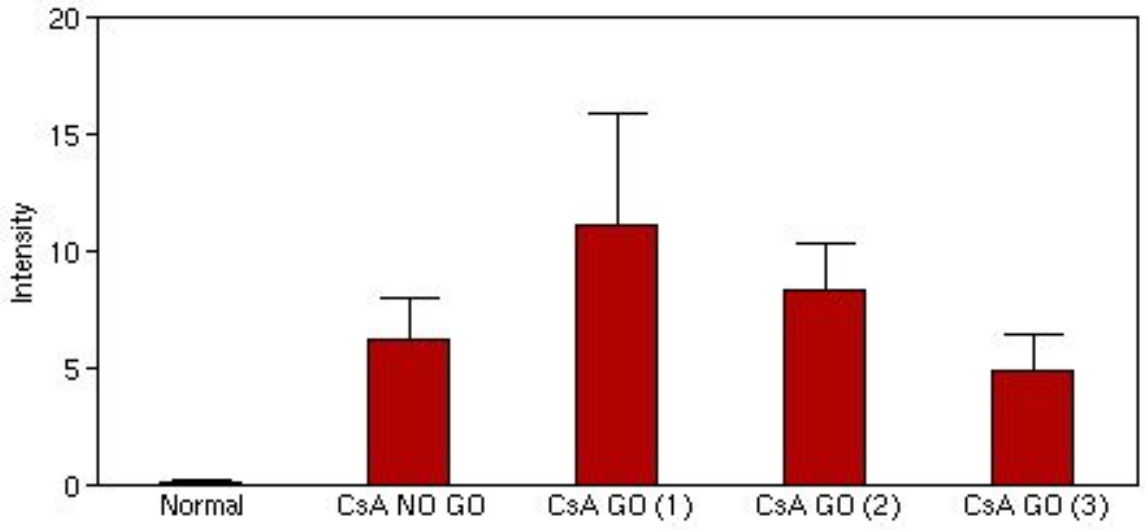

Figure 8. Differential expression of IL-8.

IL-8 is significantly upregulated in all CsA GO groups and CsA NO GO groups. Intensity= mean-normalized quantitative expression of IL-8. (CsAnoGO= Cyclosporin A without gingival overgrowth, CsAGO= Cyclosporin A with gingival overgrowth.)

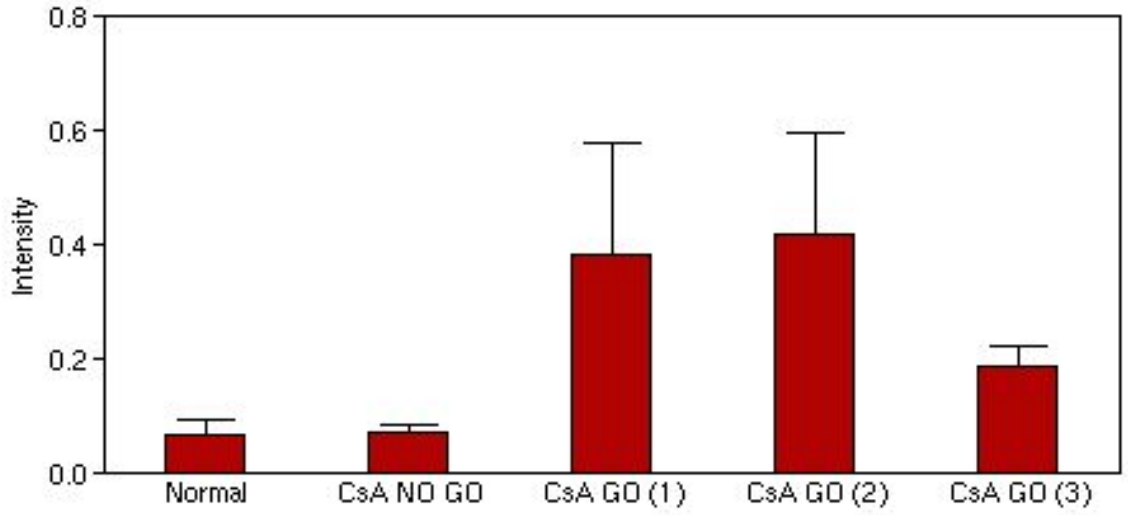

Figure 9. Differential expression of IL-8RA (CXCR1).

IL-8RA is significantly upregulated in all CsA GO groups, and not upregulated in theCsA NO GO group compared to normal controls. Intensity= mean-normalized quantitative expression of IL-8RA. (CsAnoGO= Cyclosporin A without gingival overgrowth, CsAGO= Cyclosporin A with gingival overgrowth.)

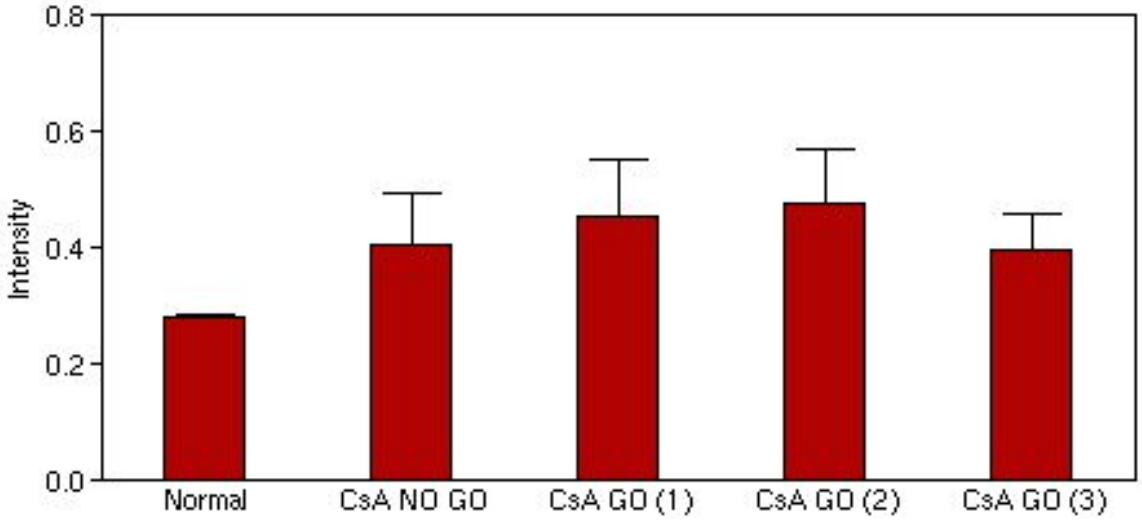

Figure 10. Differential expression of IL-8RB (CXCR2).

Expression of IL-8RB in CsA GO groups and CsA NO GO group is not significantly different from control. Intensity= mean-normalized quantitative expression of IL-8RA. (CsAnoGO= Cyclosporin A without gingival overgrowth, CsAGO= Cyclosporin A with gingival overgrowth.)

6. DISCUSSION

The development of GO and fibrosis is complex and likely to involve interactions among CsA and fibroblasts/myofibroblasts, other resident cells, inflammatory cells, and the alteration in the normal balance of cytokines in the gingival tissue.[101] Our results indicate that CsA influences the expression of a number of cytokines and chemokines, some of which have not been reported in the dental literature associated with GO studies. CsA is known to modulate gene expression in a tissue specific manner,[155] and this is evident when comparing our results with literature describing other tissues. *IL-8* was the primary gene of interest due to the recognition of its significant upregulation in other forms of GO studied in our lab. There is evidence for the direct involvement of *IL-8* and its high-affinity receptor in the development of fibrosis in other organ tissues, and these reports are consistent with our findings and our hypothesis for their role in the development of CsA-induced GO.

6.1 **IL-8**

IL-8 (CXCL8) was found to be significantly (40-50 fold) upregulated by CsA in gingival biopsies in our subjects compared to healthy controls not taking CsA. IL-8 was originally discovered as one of the first chemokines activating neutrophil granulocytes after secretion by lipopolysaccharide-stimulated monocytes. Since then, IL-8 has been demonstrated to participate in many physiologic and pathophysiologic processes.[143] Previous studies on IL-8's involvement in CsA-induced GO reported an insignificant increase of IL-8 expression in the GCF of CsA treated patients,[66] and that

CsA was found to increase IL-8 production in HGFs stimulated with synthetic TLR ligands.[140] We studied a subset of the patients studied by Bostanci et al.[68] They noted a slightly higher level of IL-8 protein in the GCF from CsA treated patients with GO compared to those without GO. While they examined GCF protein levels, and we examined RNA expression from the IL-8 gene in tissue biopsies, are findings for IL-8 expression are consistent.

CsA has been shown to cause gingival overgrowth in 25-30% of patients taking the drug.[11, 45] While all patients in our study taking CsA significantly upregulated IL-8 regardless of GO status, only those that were GO+ displayed significantly increased expression of CXCR1 (IL-8's high affinity receptor). CXCR2 is the low-affinity receptor for IL-8, and our results showed no significant differences between control subjects and those treated with CsA regardless of GO status.

The key to the GO phenotype appears to be dependent upon expression of the high affinity IL-8 receptor gene *CXCR1.* There are at least 2 possibilities for differential CXCR1 expression. Individual susceptibility to CsA may be directly dependent on its ability to induce increased CXCR1 expression in some subjects more so than others. Alternatively, the GO "responders" may innately produce or contain an increased number of these receptors on profibrotic cells, or cells that have the potential to differentiate into profibrotic cells. The contributions of IL-8 and CXCR1 to tissue fibrosis have been explored in chronic liver disease. Results indicated that IL-8 expression was significantly increased in the serum of chronic liver disease patients compared to healthy controls; however, increased progression of fibrosis was paralleled by an increased expression of hepatic CXCR1. The source of the IL-8 and

CXCR1 expression was confirmed to be the liver based on intrahepatic IL-8 gene expression being strongly (approximately 12-fold) induced in chronic liver disease patients compared to control.[161] This indicates that a similar pattern to our findings regarding global upregulation of IL-8 and increased expression of CXCR1 accompanying increased fibrotic changes has been previously demonstrated in hepatic tissues.

Traditionally chemokines were only thought to be activators and chemoattractants for subsets of leukocytes for immune system functioning.[12, 121] More recently, other functions of these proteins including fibroblast activation and angiogenesis have been discovered in tissue fibrosis of many different organ systems. Fibrosis of the liver, kidney, skin, and lung have been found in various human and animal studies to be mediated by chemokines, and are the major etiologic driver in some cases.[119]

One study compared the expression levels of pro-inflammatory cytokines such as IL-8 in normal renal fibroblasts, and fibroblasts derived from interstitial renal fibrosis in culture. It was observed that while both types of fibroblasts spontaneously produced IL-8, 3-4 fold greater expression was noted in the fibrosis-derived fibroblasts.[162] IL-8 expression levels have also been reported in serum and urine of 124 children with acute pyelonephritis or urinary tract infections. Post-infectious renal scaring is a complication of these conditions that might occur in anywhere from 10-65% of cases.[163] This study reported that initial urine and serum IL-8 concentrations were significantly higher in those children with renal scaring than those without, and multivariate analysis found higher initial IL-8 expression in the serum and urine to be

an independent predictor of renal scaring.[163] Therefore, in these studies IL-8 expression in the kidneys is associated with more fibrotic phenotype, and may be seen as a profibrotic chemokine.

In patients with chronic liver disease such as end stage cirrhosis, cholestatic disease, and primary biliary cirrhosis (n=200), the serum expression levels of IL-8 and its receptors, CXCR1 and CXCR2, were measured and compared to healthy control subjects (n=141). IL-8 serum expression was significantly elevated in chronic liver disease patients, and there was a positive correlation with the increased progression of fibrosis/cirrhosis. Furthermore, the increase in IL-8 expression could not be attributed to intrahepatic neutrophil accumulation in all cases, as would be expected of the highly chemotactic molecule for neutrophils. In non-biliary cirrhosis, increased progression of fibrosis was paralleled by an increased expression of hepatic CXCR1.[161] This bears a striking similarity to our results in that significant increases in CXCR1 were associated with increased fibrotic changes in the gingiva. In this model, IL-8 may have been acting as a chemoattractant for profibrotic cells expressing CXCR1. The subjects in our study that were found to have GO, had a significant increase in IL-8 and CXCR1 expression, and perhaps profibrotic cells expressing CXCR1 were attracted by IL-8 upregulation in the gingiva, which led to increased amounts of collagen production and ECM deposition by these cells. Therefore the "responders" to CsA may express more CXCR1 on profibrotic cells than "non-responders," and this may contribute to the etiology of CsA-induced GO.

Idiopathic pulmonary fibrosis is a lung disease of unknown origin characterized by fibrotic changes in the alveolar wall and interstitium. Bronchoalveolar lavage is a

method by which fluid is introduced into the lungs and collected for examination and diagnostic purposes. This fluid has been examined for the expression levels of IL-8 in patients with idiopathic pulmonary fibrosis (n=42), and compared to normal healthy control subjects (n=12). Results reported a significant elevation in IL-8 expression levels in those with idiopathic pulmonary fibrosis.[164] Therefore it seems IL-8 has profibrotic implications in idiopathic pulmonary fibrosis as well.

Hypertrophic scar is a fibroproliferative disorder stemming from some form of tissue trauma, which results in the deposition of excess collagen and ECM components. The pathogenesis for this condition remains unclear, however, gram-negative bacterial contamination and chronic inflammation are considered to play a significant role. Dermal fibroblasts have been cultured from both normal healthy subjects and those with hypertrophic scar formation and analyzed for the expression of different pro-inflammatory cytokines. Expression levels of IL-8 were found to be significantly increased in the hypertrophic scar-derived fibroblasts compared to control fibroblasts based on ELISA.[165] Authors discussed the importance of controlling bacterial contamination as a means to minimize hypertrophic scaring, and this principle is applied to the gingiva and gingival enlargement as well.[7]

A common theme in the literature is that tissue fibrosis emerges from an uncontrolled repair response often triggered by tissue damage.[166] This view reflects the observation that fibrosis often follows injury. However, not all injury repair results in fibrosis, but it does appear to be a mechanism in some forms of tissue fibrosis. Whether GO follows a similar injury related fibrosis model is uncertain, but it is important to remember that the gingiva appears to heal remarkably well, typically

without fibrotic scarring.[167, 168] In general, the gingiva is constantly undergoing catabolic and anabolic changes based on response to “injury,” and the remodeling of tissues follows production and release of chemotactic and inflammatory molecules.[169] Gingival anatomy allows for this as the junctional epithelium is non-keratinized and semi-permeable to allow the passage of immunoregulatory cells in order to provide defense against invading bacterial contaminants.[1] Chemokines and cytokines play an instrumental role in the metabolism of connective tissue and ECM cells. In addition to epithelial cells and endothelial cells, they are secreted by fibroblasts, macrophages, and lymphocytes, and play a significant role in connective tissue metabolism. Furthermore, cytokines and chemokines initiate signaling cascades mediated by certain receptors, which result in the proliferation and differentiation of connective tissue cells and ECM.[169] Signal transduction can be regulated at different levels, by the number of receptors, and by the types of cell specific receptors. A number of studies reviewed earlier in this document have reported elevated levels of many different cytokines and chemokines in GO tissues.[5, 140, 151, 152] This alteration in the normal balance of cytokines and chemokines suggests a potential mechanism for fibrotic changes in the gingiva associated with GO.

The origin of altered IL-8 expression by CsA may be traced to the promoter region of the IL-8 gene, which contains binding sites for the transcription factor AP-1. The binding activity of AP-1 has shown to be substantially increased in CsA-treated human aortic smooth muscle cells[144] and is increased approximately 4.5 fold in HGFs.[155] CsA-induced increase in AP-1 binding activity showed higher activation levels of ERK-1 and ERK-2 MAPK signal transduction pathways, which are known to

mediate cell proliferation and collagenase gene expression.[155] Interestingly, mutations of genes in the MAPK pathways have been etiologically linked to gingival overgrowth.[14] HGF1 is a rare autosomal dominant form of hereditary gingival fibromatosis, and GO in this condition is caused by a frameshift mutation in the *SOS-1* gene. This mutation produces a premature stop codon, truncating the *SOS1* protein and deleting the functionally important proline-rich SH3 binding domains on *SOS-1*. This truncating mutation which deletes the proline-rich region in *SOS1* is associated with enhanced *SOS1* activity, and thus and the production of gingival overgrowth. *SOS1* is found upstream from ERK-2 in the MAPK pathway,[14] and previous studies have suggested that common pathways exist between drug-induced and non-drug induced gingival fibrosis.[170] Therefore, a potential mechanism by which CsA leads to GO is through the upregulation of the chemokine IL-8 via increased binding of AP-1, which leads to higher activation levels of MAPK pathways, and thus increased cell proliferation and differentiation. As we observed all patients taking CsA to show an increase in the expression levels of IL-8 compared to control specimens, conceptually one would expect there to be some difference in the way the subject responds to the increased levels of IL-8. What may separate a “responder” to CsA from a “non-responder” in the form of GO could be differences in the activity of signal transduction pathways stimulated by IL-8, leading to increased cell proliferation and differentiation in those with increased activity of signal transduction pathways.

The myofibroblast has been implicated as a major pro-fibrotic cell, and it can be produced in a variety of ways.[17] Resident myofibroblasts can arise from fibroblasts that already reside in the gingiva, through the process of EMT and/or EndMT, and

through other cells such as pericytes derived from contractile cells around capillaries and venues, and fibroctyes derived from bone marrow stem cells.[17] IL-8 is a highly chemoattractant molecule, which has the potential to regulate each of these cellular processes in coordination with its high-affinity receptor, CXCR1.[17, 119] Resident gingival fibroblasts contain pattern recognition receptors such as toll-like receptors. Ligands for these receptors can stimulate the production of pro-inflammatory cytokines such as IL-8,[165] and promote the differentiation of fibroblasts into myofibroblasts known to produce larger quantities of collagen and ECM components.[17] Individuals expressing more receptors for IL-8 may be more prone to developing GO in response to a stimulus such as CsA.

Angiogenesis is a crucial component of pathologic conditions including fibrosis due to the increased metabolic demands of the tissues.[119] Pericytes around the endothelium of new capillaries are capable of differentiation into myofibroblasts. Histologic evaluation of CsA GO reveals an increased amount of vascularization within the underlying connective tissue, including in the deep elongated rete pegs.[38, 56] IL-8 has been strongly associated with angiogenic changes in different tissue types,[171-173] and its expression is significantly upregulated in our data as a result of CsA administration. What may differentiate a “responder” from a “non-responder” could be the expression levels of CXCR1 by these pericytes. Thus, CsA induced upregulation of IL-8 may also involve changes in angiogenesis, and one could hypothesize that those individuals whom express more CXCR1 in pericytes around blood vessels will display a greater phenotypic change in the form of GO due to the differentiation of pericytes into myofibroblasts that are producing more collagen and ECM.

EMT is involved in tumor cell motility and invasiveness, which leads to metastasis,[174] and has more recently been implicated in contributing to fibrotic phenotypes and drug-induced GO.[15, 150, 178] Studies have found a positive association between IL-8 expression and tumor cells undergoing EMT,[174] as well as enhanced CXCR1 signaling.[175] Furthermore, a feedback loop can be created in which IL-8 and CXCR1 remain upregulated and promote multiple stimuli for EMT.[175] Our results identified significant increases in IL-8 and CXCR1, and it is suggested that an environment favoring EMT and/or EndMT can be created, which involves the trans-differentiation of epithelial cells to profibrotic myofibroblast cells. Moreover, a "responder" may contain more epithelial/endothelial cells expressing CXCR1, which accounts for increased EMT/EndMT leading to increased fibrotic cells, and collagen and ECM deposition.

Fibrocytes are bone marrow derived cells, which are blood borne and produce collagen. Fibrocytes have also been shown to differentiate into fibroblasts and myofibroblasts.[176] Fibrocyte recruitment can be mediated through chemokines and their receptors, and studies have shown human fibrocytes express chemokine receptors including CXCR1.[176, 177] Increased expression of fibrocytes in serum have been described in idiopathic pulmonary fibrosis, nephrogenic systemic fibrosis, and scleroderma lung fibrosis.[178, 179] With a significant increase of IL-8 in the patients taking CsA, recruitment of these fibrocytes may be part of the mechanism by which an increase in collagen and ECM occur in the gingiva. Patients responding to CsA via GO may be expressing more CXCR1 on fibrocytes, leading to increased accumulation in

the gingiva, and the GO phenotype not seen in those individuals with lower CXCR1 levels.

6.2 **Collagen and ECM Metabolism**

The available literature regarding collagen accumulation associated with CsA trends toward an increase in the amount of collagen production. One of the well-designed studies described an increased abundance of type I collagen in GO tissues from renal transplant patients based on indirect immunofluorescence, which was confirmed at the transcriptional level via in-situ hybridization and qPCR.[60] Data from our study supports a slight (though non-significant) increase in the amount of type I collagen, with a significant increase in type IV collagen in those patients displaying GO. Type IV collagen is found primarily in the basal lamina, whereas type I collagen is the most abundant collagen in the body.[180] Type IV collagen is found in the basement membrane of vasculature and epithelium, and IL-8 is known to increase angiogenesis in multiple different tissues, as well as stimulate EMT, a hallmark of which is basement membrane disruption.[150]

The reported decrease in expression of MMPs in the literature may be dependent upon the duration of time individuals are exposed to the drug, their inflammatory status, as well as differences in study design. Most *in vivo* studies evaluating the expression of MMPs in CsA-induced GO found an increase in their expression,[87, 110] while *in vitro* studies supported the opposite.[111-114, 128] These differences may reflect important differences in *in vivo* and *in vitro* models. *In vivo* models include the presence of an anaerobic environment due to a gingival or

periodontal pocket, and therefore a bacterial challenge leading to an increase of inflammatory cells and MMPs. Consequently it seems that CsA itself may be suppressing MMP expression, however, when faced with a clinical scenario, the inflammatory status has more influence on the expression levels. Our results indicate that in those subjects on CsA exhibiting GO, there was a significant increase of MMP-1, MMP-2, and TIMP-1, while those on CsA not displaying GO showed a significant increase in TIMP-1 as well. This is consistent with the other *in vivo* research that has been published regarding this relationship. Thus it seems that the inflammatory status of the patient, even when oral hygiene and plaque accumulation are strictly enforced, may be a more significant factor than the CsA medication regarding expression of MMPs and TIMPs. Furthermore, regarding EMT, MMPs may be important factors in the breakdown of the basement membrane integrity, which is characteristic of epithelial trans-differentiation and migration into the underlying connective tissue.[150] Therefore, the increase in MMPs found in our results would be consistent with the EMT process, and possibly provide an explanation for this increase.

When evaluating fibroblast apoptosis as a result of CsA, the available literature appears to favor a reduction in apoptosis compared to control specimens, potentially explaining cell and cellular secretion accumulation and GO. These conclusions have been based on the presence of certain markers associated with apoptosis such as caspase-3, FOXO-1, p53, and bcl-2.[106, 108] Review of expression of genes encoding these markers in our subjects revealed a significant increase in caspase-3 in both CsA no GO and CsA GO groups, while other markers were insignificantly effected. However, our study was not designed to evaluate this outcome, and more evidence is

needed on this topic before a consensus can be reached regarding the effect of CsA on gingival cell apoptosis.

The process of EMT has been described in drug-induced GO tissues based on expression levels of epithelial and mesenchymal cells, as well as basement membrane proteins.[15, 16, 150] The significance of this cellular transition is the differentiation of an active fibroblast-like cell that is actively producing and secreting ECM including collagen. Based on the current available evidence, it seems that this occurrence is more common in forms of GO known to be very fibrotic, such as phenytoin-induced GO and hereditary forms of gingival fibromatosis,[150, 170] however, EMT may play a significant role in CsA GO as well.

6.3 Other Cytokine/Chemokine Involvement

The interleukins IL-6 and IL-1β were both reported to be increased as a result of CsA administration according to the literature,[137-140] and this was consistent with our findings as well. Similarly, PDGF-B was found to be upregulated in the literature,[146, 148, 149] however, our results did not correlate with these findings. While TGF-β_1 has been found to be mostly upregulated in the literature, studies have also shown no significant changes.[5, 124, 128, 130, 131, 134-136] Our data found increased TGF-β_1 expression, although not significantly.

6.4 **Strengths of The Study**

There are many strengths of this study, some of which were aimed at minimizing the risk factors associated with CsA GO in order to insure a well-controlled study. All of the subjects were adults who received renal transplants and had been taking CsA for at least 6 months. The inflammatory status was very strictly controlled, and none of the patients presented with bone loss of >3mm measured from the CEJ, in >95% of sites. A well-defined gingival hyperplastic index was used, making this variable as objective as possible.

With the relatively recent boom in the field of bioinformatics has come the ability to store, retrieve, organize and analyze large amounts of data. The use of microarray and gene expression software in our study allowed the observation of approximately 50,000 targets in the tissues that were acquired. This afforded us the opportunity to not only compare and contrast our data with previously reported dental and medical literature, but also identify new patterns of differentially expressed genes. The software also provided the opportunity to further explore ontological pathways in genes with significant differences[159] and the Kyoto Encyclopedia of Genes and Genomics (KEGG) pathways.[160] The most beneficial use of the ontological and KEGG pathway analyses is validation of specific genes in a biological and/or biochemical pathways, and thus provide biological and/or biochemical significance. With this information, it was possible to make associations that may not have otherwise been established.

6.5 **Weaknesses of the Study**

The weaknesses present in this study are not unlike many of the weaknesses observed in experiments with similar designs. As with most arrays used for detection of gene expression, oligonucleotide sequences were used for each gene (over 50,000). While there is enhanced sensitivity with this technique, there is the possibility that the oligonucleotide used does not correspond to other isoforms present for a specific gene. Therefore there are bound to be some inaccuracies based on the specific nucleotide sequence used, as well as inappropriate binding to probes.

While the number of individuals used in the study was adequate to detect significant changes in gene expression levels, it was the minimum at which to do so.[181] Ideally, more subjects would have been included in the study. The most difficult group members to recruit are those subjects taking CsA and not displaying GO. These patients may not require dental surgery in which “waste” tissue would be accessible, and therefore the harvesting of tissue would be deemed unethical. Still, it is recommended for future studies of this design to include more subjects in order to validate the results.

While the hyperplastic index used in this study is very common, the GO+ category included those with minimal GO covering one third of the clinical crown or less. It might have been easier to distinguish more significant differences in gene expression had the GO+ group consisted of those with a score of 2 and 3 only, meaning more severe GO. In deed, it is the GO’s with a score of 2 and 3 that are more clinically significant, and would in most cases necessitate surgical intervention for proper gingival contours to be restored. At the very least, for futures studies these

groups can be broken up in the data to possibly distinguish a greater difference in gene expression.

Verification of the data produced from the gene arrays was never done at the protein level. This would have strengthened and validated the results based on protein expression found at the tissue level. Future experiments including immunohistochemistry are recommended as an excellent complement to the data sets.

One of the clinical features now receiving increased attention is that of periodontal biotype, as proposed by Seibert and Lindhe (1989).[182] The clinical appearance of the gingiva largely reflects the underlying structure of the epithelium and lamina propria, and this appearance is rather variable between subjects. Moreover, tooth shape is associated with differences in the clinical features of the gingiva as well.[183] Neither this study, nor any other to our knowledge, has looked at periodontal biotype/phenotype as a risk factor for developing CsA GO, and future experiments may consider accounting for this variable. Conceptually, if two patients who are similar in all aspects aside from one having a thick biotype and the other having a thin biotype, the subject with the thick biotype potentially has a greater volume of tissue and cells present in the gingiva which could account for a comparatively exaggerated response to CsA. Perhaps the greatest difficulty comes in measuring biotype. Traditionally this was done by inserting a periodontal probe into the gingival sulcus to determine if it could be visualized through the tissue, indicating a thin biotype. Should the probe not be visible, the subject was deemed to have a thick biotype.[184] Other methods have used endodontic files or other instruments to measure

the tissue thickness at different points down the length of the tooth, unfortunately this would usually require some form of anesthetic. Another difficulty in adding this to a clinical examination is that it would necessitate measurements prior to the patient going on CsA, which can be more challenging.

7. CONCLUSION

CsA is a potent immunosuppressant that is known to cause GO in 25-30% of subjects.[11, 45] The potential etiologies for CsA-induced GO have been explored for upwards of thirty years, and the cause remains unclear. This condition is multifactorial and includes interactions between many cellular processes at several different levels. The aim of this research was to analyze the expression levels of multiple genes in gingival tissue samples collected from renal transplant patients taking CsA both with and without GO, as well as control subjects on no medication and without displaying GO, in order to gain a better understanding of the potential underlying mechanisms.

IL-8 is a gene of particular interest to us based on previous research in our lab pertaining to both drug-induced and inherited forms of GO in which its expression was significantly upregulated. This study found IL-8 to be significantly upregulated by CsA. While IL-8 has traditionally been linked to immunologic functions associated with activation of neutrophils, evidence has emerged describing other functions of this biomarker, including its role in tissue fibrosis. Fibrotic diseases are often times very difficult to treat based on lack of obvious etiology, and many studies in the medical field have revealed the importance of cytokines/chemokines in the development and progression of such conditions. IL-8 has been indicated in some of these fibrotic diseases of the skin, liver, kidney, and lungs, and we submit that IL-8 and its high-affinity receptor, CXCR1, have a role in fibrotic changes in the gingiva.

Previous work on HGF1 has shown that a mutation in the *SOS-1* gene renders it constitutively active, driving the MAPK signaling pathway to increase cell

proliferation and differentiation. Furthermore, it has been shown that CsA increases the binding activity of AP-1, an *IL-8* transcription factor, in HGFs. AP-1 has been associated with an increase in ERK-1 and ERK-2 MAPK pathways, and is directly linked to IL-8 upregulation by CsA, thus providing another potential mechanism through which IL-8 may contribute to GO.

As reported in other studies, only a percentage of patients taking CsA exhibited GO. While all patients in our study taking CsA demonstrated significantly upregulated IL-8 expression regardless of GO status, only those that were GO+ displayed increased expression of CXCR1, its high-affinity receptor. Individual susceptibility to developing CsA GO may be dependent on a threshold expression of CXCR1 in cells including fibroblasts, fibrocytes, and pericytes, rendering them capable of differentiating into an active fibroblast type cell such as myofibroblasts known to actively produce collagen and ECM. These individuals also may overexpress CXCR1 on certain other cell types such as epithelial/endothelial cells capable of EMT/EndMT, and trans-differentiating into fibroblast-like cells also capable of collagen and ECM production.

Therefore, CsA activation of IL-8, and the observed upregulation of CXCR1 in human gingival tissues may provide a mechanism for driving increased recruitment and differentiation of profibrotic cells capable of producing collagen and ECM components necessary to produce gingival overgrowth. While our data demonstrate a potential etiologic association between IL-8/CXCR1 expression and CsA-induced GO, the direct functional role of IL-8 and CXCR1 in gingival enlargement remains difficult to determine, and therefore better designed studies are necessary.

CITED LITERATURE

1. Michael G. Newman DHHT, DDS, MS. Perry R. Klokkevold, DDS, MS. Fermin A. Carranza, Dr Odont. *Carranza's Clinical Periodontology, 10th edition*. St. Louis, Missouri: Elsevier; 2006.

2. DiFranco CF, Toto PD, Rowden G, Gargiulo AW, Keene JJ, Jr., Connelly E. Identification of Langerhans cells in human gingival epithelium. *Journal of periodontology* 1985;56:48-54.

3. Genco RJ GHCD. *Contemporary Periodontics*: Mosby Publications; 1990.

4. Modeer T, Domeij H, Anduren I, Mustafa M, Brunius G. Effect of phenytoin on the production of interleukin-6 and interleukin-8 in human gingival fibroblasts. *Journal of oral pathology & medicine : official publication of the International Association of Oral Pathologists and the American Academy of Oral Pathology* 2000;29:491-499.

5. Chae HJ, Ha MS, Yun DH, et al. Mechanism of cyclosporine-induced overgrowth in gingiva. *Journal of dental research* 2006;85:515-519.

6. Schor SL, Ellis I, Irwin CR, et al. Subpopulations of fetal-like gingival fibroblasts: characterisation and potential significance for wound healing and the progression of periodontal disease. *Oral diseases* 1996;2:155-166.

7. Seymour RA, Ellis JS, Thomason JM. Risk factors for drug-induced gingival overgrowth. *Journal of clinical periodontology* 2000;27:217-223.

8. Bartold PM, Walsh LJ, Narayanan AS. Molecular and cell biology of the gingiva. *Periodontology 2000* 2000;24:28-55.

9. Vinay Kumar RSC SLR. *Basic Pathology*. Philadelphia, PA: Saunders; 2003.

10. Informational Paper: Drug-Associated Gingival Enlargement. *Journal of periodontology* 2004;75:1424-1431.

11. Hassell TM, Hefti AF. Drug-induced gingival overgrowth: old problem, new problem. *Critical reviews in oral biology and medicine : an official publication of the American Association of Oral Biologists* 1991;2:103-137.

12. Vinay Kumar RSC, Stanley L. Robbins. *Basic Pathology*. Philadelphia, PA: Saunders; 2003.

13. Hallmon WW, Rossmann JA. The role of drugs in the pathogenesis of gingival overgrowth. A collective review of current concepts. *Periodontology 2000* 1999;21:176-196.

14. Hart TC, Zhang Y, Gorry MC, et al. A mutation in the SOS1 gene causes hereditary gingival fibromatosis type 1. *American journal of human genetics* 2002;70:943-954.

15. Sume SS, Kantarci A, Lee A, Hasturk H, Trackman PC. Epithelial to mesenchymal transition in gingival overgrowth. *The American journal of pathology* 2010;177:208-218.

16. Kalluri R, Neilson EG. Epithelial-mesenchymal transition and its implications for fibrosis. *The Journal of clinical investigation* 2003;112:1776-1784.

17. Wynn TA. Cellular and molecular mechanisms of fibrosis. *The Journal of pathology* 2008;214:199-210.

18. Boltchi FE, Rees TD, Iacopino AM. Cyclosporine A-induced gingival overgrowth: a comprehensive review. *Quintessence international* 1999;30:775-783.

19. Ciavarella D, Guiglia R, Campisi G, et al. Update on gingival overgrowth by cyclosporine A in renal transplants. *Medicina oral, patologia oral y cirugia bucal* 2007;12:E19-25.

20. Kataoka M, Kido J, Shinohara Y, Nagata T. Drug-induced gingival overgrowth--a review. *Biological & pharmaceutical bulletin* 2005;28:1817-1821.

21. Correa JD, Queiroz-Junior CM, Costa JE, Teixeira AL, Silva TA. Phenytoin-induced gingival overgrowth: a review of the molecular, immune, and inflammatory features. *ISRN dentistry* 2011;2011:497850.

22. Barclay S, Thomason JM, Idle JR, Seymour RA. The incidence and severity of nifedipine-induced gingival overgrowth. *Journal of clinical periodontology* 1992;19:311-314.

23. Ellis JS, Seymour RA, Steele JG, Robertson P, Butler TJ, Thomason JM. Prevalence of gingival overgrowth induced by calcium channel blockers: a community-based study. *Journal of periodontology* 1999;70:63-67.

24. Slavin J, Taylor J. Cyclosporin, nifedipine, and gingival hyperplasia. *Lancet* 1987;2:739.

25. Fattore L, Stablein M, Bredfeldt G, Semla T, Moran M, Doherty-Greenberg JM. Gingival hyperplasia: a side effect of nifedipine and diltiazem. *Special care in dentistry : official publication of the American Association of Hospital Dentists, the Academy of Dentistry for the Handicapped, and the American Society for Geriatric Dentistry* 1991;11:107-109.

26. Barak S, Engelberg IS, Hiss J. Gingival hyperplasia caused by nifedipine. Histopathologic findings. *Journal of periodontology* 1987;58:639-642.

27. Nery EB, Edson RG, Lee KK, Pruthi VK, Watson J. Prevalence of nifedipine-induced gingival hyperplasia. *Journal of periodontology* 1995;66:572-578.

28. Harper SJ, Moorhouse J, Abrams K, et al. The beneficial effects of oral nifedipine on cyclosporin-treated renal transplant recipients--a randomised prospective study. *Transplant international : official journal of the European Society for Organ Transplantation* 1996;9:115-125.

29. Thomason JM, Seymour RA, Rice N. The prevalence and severity of cyclosporin and nifedipine-induced gingival overgrowth. *Journal of clinical periodontology* 1993;20:37-40.

30. Wright G, Welbury RR, Hosey MT. Cyclosporin-induced gingival overgrowth in children. *International journal of paediatric dentistry / the British Paedodontic Society [and] the International Association of Dentistry for Children* 2005;15:403-411.

31. Mendonza A, Gohh R, Akhlaghi F. Determination of cyclosporine in saliva using liquid chromatography-tandem mass spectrometry. *Therapeutic drug monitoring* 2004;26:569-575.

32. Hesselink DA, Bouamar R, van Gelder T. The pharmacogenetics of calcineurin inhibitor-related nephrotoxicity. *Therapeutic drug monitoring* 2010;32:387-393.

33. Copeland KR, Yatscoff RW, McKenna RM. Immunosuppressive activity of cyclosporine metabolites compared and characterized by mass spectroscopy and nuclear magnetic resonance. *Clinical chemistry* 1990;36:225-229.

34. Wang CP, Hartman NR, Venkataramanan R, et al. Isolation of 10 cyclosporine metabolites from human bile. *Drug metabolism and disposition: the biological fate of chemicals* 1989;17:292-296.

35. Guaguere E, Steffan J, Olivry T. Cyclosporin A: a new drug in the field of canine dermatology. *Veterinary dermatology* 2004;15:61-74.

36. Rezzani R. Cyclosporine A and adverse effects on organs: histochemical studies. *Progress in histochemistry and cytochemistry* 2004;39:85-128.

37. Bentouimou N, Moreau JF, Peyrat MA, Soulillou JP, Hallet MM. The effects of cyclosporine on HILDA/LIF gene expression in human T cells. *Transplantation* 1993;55:163-167.

38. Rateitschak-Pluss EM, Hefti A, Lortscher R, Thiel G. Initial observation that cyclosporin-A induces gingival enlargement in man. *Journal of clinical periodontology* 1983;10:237-246.

39. Chai LY, Netea MG, Tai BC, et al. An elevated pro-inflammatory cytokine response is linked to development of amphotericin B-induced nephrotoxicity. *The Journal of antimicrobial chemotherapy* 2013;68:1655-1659.

40. Rateitschak-Pluss EM, Hefti A, Rateitschak KH. [Gingival hyperplasia from cyclosporin A medication]. *Schweizerische Monatsschrift fur Zahnheilkunde = Revue mensuelle suisse d'odonto-stomatologie / SSO* 1983;93:57-65.

41. Adams D, Davies G. Gingival hyperplasia associated with cyclosporin A. A report of two cases. *British dental journal* 1984;157:89-90.

42. Bennett JA, Christian JM. Cyclosporine-induced gingival hyperplasia: case report and literature review. *Journal of the American Dental Association* 1985;111:272-273.

43. Rostock MH, Fry HR, Turner JE. Severe gingival overgrowth associated with cyclosporine therapy. *Journal of periodontology* 1986;57:294-299.

44. Pernu HE, Pernu LM, Huttunen KR, Nieminen PA, Knuuttila ML. Gingival overgrowth among renal transplant recipients related to immunosuppressive medication and possible local background factors. *Journal of periodontology* 1992;63:548-553.

45. McGaw WT, Porter H. Cyclosporine-induced gingival overgrowth: an ultrastructural stereologic study. *Oral surgery, oral medicine, and oral pathology* 1988;65:186-190.

46. Seymour RA, Jacobs DJ. Cyclosporin and the gingival tissues. *Journal of clinical periodontology* 1992;19:1-11.

47. Somacarrera ML, Hernandez G, Acero J, Moskow BS. Localization of gingival overgrowth in heart transplant patients undergoing cyclosporin therapy. *Journal of periodontology* 1994;65:666-670.

48. Thomason JM, Seymour RA, Soames JV. Severe mucosal hyperplasia of the edentulous maxilla associated with immunosuppressant therapy: a clinical report. *The Journal of prosthetic dentistry* 1994;72:1-3.

49. Friskopp J, Klintmalm G. Gingival enlargement. A comparison between cyclosporine and azathioprine treated renal allograft recipients. *Swedish dental journal* 1986;10:85-92.

50. Miranda J, Brunet L, Roset P, Farre M, Mendieta C. Reliability of two measurement indices for gingival enlargement. *Journal of periodontal research* 2012;47:776-782.

51. Angelopoulos AP, Goaz PW. Incidence of diphenylhydantoin gingival hyperplasia. *Oral surgery, oral medicine, and oral pathology* 1972;34:898-906.

52. Miller CS, Damm DD. Incidence of verapamil-induced gingival hyperplasia in a dental population. *Journal of periodontology* 1992;63:453-456.

53. Seymour RA, Smith DG, Turnbull DN. The effects of phenytoin and sodium valproate on the periodontal health of adult epileptic patients. *Journal of clinical periodontology* 1985;12:413-419.

54. Thomason JM, Ellis JS, Jovanovski V, Corson M, Lynch E, Seymour RA. Analysis of changes in gingival contour from three-dimensional co-ordinate data in subjects with drug-induced gingival overgrowth. *Journal of clinical periodontology* 2005;32:1069-1075.

55. Rosin M, Splieth C, Hessler M, Gartner C, Kordass B, Kocher T. Quantification of gingival edema using a new 3-D laser scanning method. *Journal of clinical periodontology* 2002;29:240-246.

56. Wysocki GP, Gretzinger HA, Laupacis A, Ulan RA, Stiller CR. Fibrous hyperplasia of the gingiva: a side effect of cyclosporin A therapy. *Oral surgery, oral medicine, and oral pathology* 1983;55:274-278.

57. Mariani G, Calastrini C, Carinci F, Marzola R, Calura G. Ultrastructural features of cyclosporine A-induced gingival hyperplasia. *Journal of periodontology* 1993;64:1092-1097.

58. Wondimu B, Reinholt FP, Modeer T. Stereologic study of cyclosporin A-induced gingival overgrowth in renal transplant patients. *European journal of oral sciences* 1995;103:199-206.

59. Bonnaure-Mallet M, Tricot-Doleux S, Godeau GJ. Changes in extracellular matrix macromolecules in human gingiva after treatment with drugs inducing gingival overgrowth. *Archives of oral biology* 1995;40:393-400.

60. Dannewitz B, Edrich C, Tomakidi P, et al. Elevated levels of gene expression for collagen and decorin in human gingival overgrowth. *Journal of clinical periodontology* 2006;33:510-516.

61. Afonso M, Bello Vde O, Shibli JA, Sposto MR. Cyclosporin A-induced gingival overgrowth in renal transplant patients. *Journal of periodontology* 2003;74:51-56.

62. Niimi A, Tohnai I, Kaneda T, Takeuchi M, Nagura H. Immunohistochemical analysis of effects of cyclosporin A on gingival epithelium. *Journal of oral pathology & medicine : official publication of the International Association of Oral Pathologists and the American Academy of Oral Pathology* 1990;19:397-403.

63. Thomas DW, Newcombe RG, Osborne GR. Risk factors in the development of cyclosporine-induced gingival overgrowth. *Transplantation* 2000;69:522-526.

64. Somacarrera ML, Hernandez G, Acero J, Moskow BS. Factors related to the incidence and severity of cyclosporin-induced gingival overgrowth in transplant patients. A longitudinal study. *Journal of periodontology* 1994;65:671-675.

65. Aimetti M, Romano F, Debernardi C. Effectiveness of periodontal therapy on the severity of cyclosporin A-induced gingival overgrowth. *Journal of clinical periodontology* 2005;32:846-850.

66. Bostanci N, Ilgenli T, Pirhan DC, et al. Relationship between IL-1A polymorphisms and gingival overgrowth in renal transplant recipients receiving Cyclosporin A. *Journal of clinical periodontology* 2006;33:771-778.

67. Khoori AH, Einollahi B, Ansari G, Moozeh MB. The effect of cyclosporine with and without nifedipine on gingival overgrowth in renal transplant patients. *Journal* 2003;69:236-241.

68. Klintmalm GB, Iwatsuki S, Starzl TE. Cyclosporin A hepatotoxicity in 66 renal allograft recipients. *Transplantation* 1981;32:488-489.

69. Seymour RA. Effects of medications on the periodontal tissues in health and disease. *Periodontology 2000* 2006;40:120-129.

70. Gong YM, Cao LF, Yang Y, Gu ZY. [Relationship of putative periodontopathogenic bacteria and drug-induced gingival overgrowth]. *Zhonghua kou qiang yi xue za zhi = Zhonghua kouqiang yixue zazhi = Chinese journal of stomatology* 2008;43:347-351.

71. Romito GA, Pustiglioni FE, Saraiva L, Pustiglioni AN, Lotufo RF, Stolf NA. Relationship of subgingival and salivary microbiota to gingival overgrowth in heart transplant patients following cyclosporin A therapy. *Journal of periodontology* 2004;75:918-924.

72. Fischer RG, Edwardsson S, Klinge B, Attstrom R. The effect of cyclosporin-A on the oral microflora at gingival sulcus of the ferret. *Journal of clinical periodontology* 1996;23:853-860.

73. Romito GA, Lotufo RF, Saraiva L, Pustiglioni AN, Pustiglioni FE, Stolf NA. Superinfecting microorganisms in patients under treatment with cyclosporin-A and its correlation to gingival overgrowth. *Pesquisa odontologica brasileira = Brazilian oral research* 2003;17:35-40.

74. Saraiva L, Lotufo RF, Pustiglioni AN, Silva HT, Jr., Imbronito AV. Evaluation of subgingival bacterial plaque changes and effects on periodontal tissues in patients with renal transplants under

immunosuppressive therapy. *Oral surgery, oral medicine, oral pathology, oral radiology, and endodontics* 2006;101:457-462.

75. Fuiano G, Pacchiano G, Lotito MA, Vaia E, Matarasso S, Andreucci VE. [Relations of gingival hypertrophy and blood levels of cyclosporin A in patients with renal transplants]. *Annali italiani di medicina interna : organo ufficiale della Societa italiana di medicina interna* 1989;4:161-166.

76. Hefti AF, Eshenaur AE, Hassell TM, Stone C. Gingival overgrowth in cyclosporine A treated multiple sclerosis patients. *Journal of periodontology* 1994;65:744-749.

77. Buchler M, Leibenguth P, Le Guellec C, et al. Relationship between calcineurin inhibition and plasma endothelin concentrations in cyclosporine-A-treated kidney transplant patients. *European journal of clinical pharmacology* 2004;60:703-708.

78. O'Valle F, Mesa FL, Gomez-Morales M, et al. Immunohistochemical study of 30 cases of cyclosporin A-induced gingival overgrowth. *Journal of periodontology* 1994;65:724-730.

79. de Oliveira Costa F, Diniz Ferreira S, de Miranda Cota LO, da Costa JE, Aguiar MA. Prevalence, severity, and risk variables associated with gingival overgrowth in renal transplant subjects treated under tacrolimus or cyclosporin regimens. *Journal of periodontology* 2006;77:969-975.

80. Oliveira Costa F, Ferreira SD, Lages EJ, Costa JE, Oliveira AM, Cota LO. Demographic, pharmacologic, and periodontal variables for gingival overgrowth in subjects medicated with cyclosporin in the absence of calcium channel blockers. *Journal of periodontology* 2007;78:254-261.

81. Daley TD, Wysocki GP, Day C. Clinical and pharmacologic correlations in cyclosporine-induced gingival hyperplasia. *Oral surgery, oral medicine, and oral pathology* 1986;62:417-421.

82. Schulz A, Lange DE, Hassell TM, Stone CE, Lison AE. [Cyclosporine-induced gingival hyperplasia in renal transplant patients]. *Deutsche zahnarztliche Zeitschrift* 1990;45:414-416.

83. Seymour RA, Heasman PA. Drugs and the periodontium. *Journal of clinical periodontology* 1988;15:1-16.

84. Shyh-Chang N, Zhu H, Yvanka de Soysa T, et al. Lin28 enhances tissue repair by reprogramming cellular metabolism. *Cell* 2013;155:778-792.

85. Thomason JM, Seymour RA, Ellis JS, et al. Iatrogenic gingival overgrowth in cardiac transplantation. *Journal of periodontology* 1995;66:742-746.

86. Thomason JM, Seymour RA, Ellis JS, et al. Determinants of gingival overgrowth severity in organ transplant patients. An examination of the role of HLA phenotype. *Journal of clinical periodontology* 1996;23:628-634.

87. Dannewitz B, Edrich C, Tomakidi P, et al. Elevated gene expression of MMP-1, MMP-10, and TIMP-1 reveal changes of molecules involved in turn-over of extracellular matrix in cyclosporine-induced gingival overgrowth. *Cell and tissue research* 2006;325:513-522.

88. Dannewitz B, Tomakidi P, Syagailo Y, et al. Elevation of collagen type I in fibroblast-keratinocyte cocultures emphasizes the decisive role of fibroblasts in the manifestation of the phenotype of cyclosporin A-induced gingival overgrowth. *Journal of periodontal research* 2009;44:62-72.

89. Myrillas TT, Linden GJ, Marley JJ, Irwin CR. Cyclosporin A regulates interleukin-1beta and interleukin-6 expression in gingiva: implications for gingival overgrowth. *Journal of periodontology* 1999;70:294-300.

90. Pernu HE, Knuuttila ML, Huttunen KR, Tiilikainen AS. Drug-induced gingival overgrowth and class II major histocompatibility antigens. *Transplantation* 1994;57:1811-1813.

91. Cebeci I, Kantarci A, Firatli E, et al. Evaluation of the frequency of HLA determinants in patients with gingival overgrowth induced by cyclosporine-A. *Journal of clinical periodontology* 1996;23:737-742.

92. Margiotta V, Pizzo I, Pizzo G, Barbaro A. Cyclosporin- and nifedipine-induced gingival overgrowth in renal transplant patients: correlations with periodontal and pharmacological parameters, and HLA-antigens. *Journal of oral pathology & medicine : official publication of the International Association of Oral Pathologists and the American Academy of Oral Pathology* 1996;25:128-134.

93. Kataoka M, Shimizu Y, Kunikiyo K, et al. Cyclosporin A decreases the degradation of type I collagen in rat gingival overgrowth. *Journal of cellular physiology* 2000;182:351-358.

94. Tipton DA, Stricklin GP, Dabbous MK. Fibroblast heterogeneity in collagenolytic response to cyclosporine. *Journal of cellular biochemistry* 1991;46:152-165.

95. Willershausen-Zonnchen B, Lemmen C, Schumacher U. Influence of cyclosporine A on growth and extracellular matrix synthesis of human fibroblasts. *Journal of cellular physiology* 1992;152:397-402.

96. James JA, Irwin CR, Linden GJ. The effects of culture environment on the response of human gingival fibroblasts to cyclosporin A. *Journal of periodontology* 1995;66:339-344.

97. Schincaglia GP, Forniti F, Cavallini R, Piva R, Calura G, del Senno L. Cyclosporin-A increases type I procollagen production and mRNA level in human gingival fibroblasts in vitro. *Journal of oral pathology & medicine : official publication of the International Association of Oral Pathologists and the American Academy of Oral Pathology* 1992;21:181-185.

98. Deliliers GL, Santoro F, Polli N, Bruno E, Fumagalli L, Risciotti E. Light and electron microscopic study of cyclosporin A-induced gingival hyperplasia. *Journal of periodontology* 1986;57:771-775.

99. Newell J, Irwin CR. Comparative effects of cyclosporin on glycosaminoglycan synthesis by gingival fibroblasts. *Journal of periodontology* 1997;68:443-447.

100. Gnoatto N, Lotufo RF, Matsuda M, Penna V, Marquezini MV. Expression of cell-surface heparan sulfate proteoglycans in human cyclosporin-induced gingival overgrowth. *Journal of periodontal research* 2007;42:553-558.

101. Trackman PC, Kantarci A. Connective tissue metabolism and gingival overgrowth. *Critical reviews in oral biology and medicine : an official publication of the American Association of Oral Biologists* 2004;15:165-175.

102. Hong HH, Uzel MI, Duan C, Sheff MC, Trackman PC. Regulation of lysyl oxidase, collagen, and connective tissue growth factor by TGF-beta1 and detection in human gingiva. *Laboratory investigation; a journal of technical methods and pathology* 1999;79:1655-1667.

103. Uzel MI, Kantarci A, Hong HH, et al. Connective tissue growth factor in drug-induced gingival overgrowth. *Journal of periodontology* 2001;72:921-931.

104. Sobral LM, Kellermann MG, Graner E, Martelli-Junior H, Coletta RD. Cyclosporin A-induced gingival overgrowth is not associated with myofibroblast transdifferentiation. *Brazilian oral research* 2010;24:182-188.

105. Nishikawa S, Nagata T, Morisaki I, Oka T, Ishida H. Pathogenesis of drug-induced gingival overgrowth. A review of studies in the rat model. *Journal of periodontology* 1996;67:463-471.

106. Kantarci A, Augustin P, Firatli E, et al. Apoptosis in gingival overgrowth tissues. *Journal of dental research* 2007;86:888-892.

107. Buduneli N, Buduneli E, Cinar S, Lappin D, Kinane DF. Immunohistochemical evaluation of Ki-67 expression and apoptosis in cyclosporin A-induced gingival overgrowth. *Journal of periodontology* 2007;78:282-289.

108. Bulut S, Ozdemir BH, Alaaddinoglu EE, Oduncuoglu FB, Bulut OE, Demirhan B. Effect of cyclosporin A on apoptosis and expression of p53 and bcl-2 proteins in the gingiva of renal transplant patients. *Journal of periodontology* 2005;76:691-695.

109. Kurzawski M, Drozdzik A, Dembowska E, Pawlik A, Banach J, Drozdzik M. Matrix metalloproteinase-1 gene polymorphism in renal transplant patients with and without gingival enlargement. *Journal of periodontology* 2006;77:1498-1502.

110. Emingil G, Afacan B, Tervahartiala T, Toz H, Atilla G, Sorsa T. Gingival crevicular fluid and serum matrix metalloproteinase-8 and tissue inhibitor of matrix metalloproteinase-1 levels in renal transplant patients undergoing different immunosuppressive therapy. *Journal of clinical periodontology* 2008;35:221-229.

111. Sonmez S, Cavdar C, Gunduz C, et al. Do MMP-1 levels of gingival fibroblasts have a role in the gingival overgrowth of cyclosporine-treated patients? *Transplantation proceedings* 2008;40:181-183.

112. Hyland PL, Traynor PS, Myrillas TT, et al. The effects of cyclosporin on the collagenolytic activity of gingival fibroblasts. *Journal of periodontology* 2003;74:437-445.

113. Sukkar TZ, Thomason JM, Cawston TE, et al. Gingival fibroblasts grown from cyclosporin-treated patients show a reduced production of matrix metalloproteinase-1 (MMP-1) compared with normal gingival fibroblasts, and cyclosporin down-regulates the production of MMP-1 stimulated by pro-inflammatory cytokines. *Journal of periodontal research* 2007;42:580-588.

114. Yamada H, Nishimura F, Naruishi K, et al. Phenytoin and cyclosporin A suppress the expression of MMP-1, TIMP-1, and cathepsin L, but not cathepsin B in cultured gingival fibroblasts. *Journal of periodontology* 2000;71:955-960.

115. Silva HC, Coletta RD, Jorge J, Bolzani G, de Almeida OP, Graner E. The effect of cyclosporin A on the activity of matrix metalloproteinases during the healing of rat molar extraction wounds. *Archives of oral biology* 2001;46:875-879.

116. Brook NR, Waller JR, Bicknell GR, Nicholson ML. The novel antifibrotic agent pirfenidone attenuates the profibrotic environment generated by calcineurin inhibitors in the rat salt-depletion model. *Transplantation proceedings* 2005;37:130-133.

117. Kanno CM, Oliveira JA, Garcia JF, Castro AL, Crivelini MM. Effects of cyclosporin, phenytoin, and nifedipine on the synthesis and degradation of gingival collagen in tufted capuchin monkeys (Cebus apella): histochemical and MMP-1 and -2 and collagen I gene expression analyses. *Journal of periodontology* 2008;79:114-122.

118. Chiu HC, Lu YT, Chin YT, et al. Cyclosporine A inhibits the expression of membrane type-I matrix metalloproteinase in gingiva. *Journal of periodontal research* 2009;44:338-347.

119. Sahin H, Wasmuth HE. Chemokines in tissue fibrosis. *Biochimica et biophysica acta* 2013;1832:1041-1048.

120. Brocker C, Thompson D, Matsumoto A, Nebert DW, Vasiliou V. Evolutionary divergence and functions of the human interleukin (IL) gene family. *Human genomics* 2010;5:30-55.

121. *Chemokines in Disease*. Totowa, New Jersey: Humana Press Inc; 1999.

122. Dobaczewski M, Frangogiannis NG. Chemokines and cardiac fibrosis. *Frontiers in bioscience* 2009;1:391-405.

123. Heldin CH, Miyazono K, ten Dijke P. TGF-beta signalling from cell membrane to nucleus through SMAD proteins. *Nature* 1997;390:465-471.

124. Buduneli N, Kutukculer N, Aksu G, Atilla G. Evaluation of transforming growth factor-beta 1 level in crevicular fluid of cyclosporin A-treated patients. *Journal of periodontology* 2001;72:526-531.

125. Cotrim P, Martelli-Junior H, Graner E, Sauk JJ, Coletta RD. Cyclosporin A induces proliferation in human gingival fibroblasts via induction of transforming growth factor-beta1. *Journal of periodontology* 2003;74:1625-1633.

126. Ruhl S, Hamberger S, Betz R, et al. Salivary proteins and cytokines in drug-induced gingival overgrowth. *Journal of dental research* 2004;83:322-326.

127. Lepri FR, Scavelli R, Digilio MC, et al. Diagnosis of Noonan syndrome and related disorders using target next generation sequencing. *BMC medical genetics* 2014;15:14.

128. Sobral LM, Aseredo F, Agostini M, et al. Molecular events associated with ciclosporin A-induced gingival overgrowth are attenuated by Smad7 overexpression in fibroblasts. *Journal of periodontal research* 2012;47:149-158.

129. Stefanidou V, Liakopoulos V, Eleftheriadis T, et al. Expression of transforming growth factor-beta receptor II mRNA in cyclosporine-induced gingival overgrowth. *Transplantation proceedings* 2006;38:2905-2908.

130. Wright HJ, Chapple IL, Blair F, Matthews JB. Crevicular fluid levels of TGFbeta1 in drug-induced gingival overgrowth. *Archives of oral biology* 2004;49:421-425.

131. Gurkan A, Afacan B, Emingil G, Toz H, Baskesen A, Atilla G. Gingival crevicular fluid transforming growth factor-beta1 in cyclosporine and tacrolimus treated renal transplant patients without gingival overgrowth. *Archives of oral biology* 2008;53:723-728.

132. Radwan-Oczko M, Boratynska M, Zietek M, Dobosz T. Transforming growth factor-beta1 gene expression and cyclosporine A-induced gingival overgrowth: a pilot study. *Journal of clinical periodontology* 2008;35:371-378.

133. Radwan-Oczko M, Boratynska M, Zietek M, Zoledziewska M, Jonkisz A. The relationship of transforming growth factor-beta1 gene polymorphism, its plasma level, and gingival overgrowth in renal transplant recipients receiving different immunosuppressive regimens. *Journal of periodontology* 2006;77:865-873.

134. Chen YT, Tu HP, Chin YT, et al. Upregulation of transforming growth factor-beta1 and vascular endothelial growth factor gene and protein expression in cyclosporin-induced overgrown edentulous gingiva in rats. *Journal of periodontology* 2005;76:2267-2275.

135. Spolidorio LC, Holzhausen M, Spolidorio DM, Nassar CA, Nassar PO, Muscara MN. Cyclosporin but not tacrolimus significantly increases salivary cytokine contents in rats. *Journal of periodontology* 2005;76:1520-1525.

136. Spolidorio LC, Spolidorio DM, Holzhausen M, Nassar PO, Nassar CA. Effects of long-term cyclosporin therapy on gingiva of rats--analysis by stereological and biochemical estimation. *Brazilian oral research* 2005;19:112-118.

137. Morton RS, Dongari-Bagtzoglou AI. Regulation of gingival fibroblast interleukin-6 secretion by cyclosporine A. *Journal of periodontology* 1999;70:1464-1471.

138. Atilla G, Kutukculer N. Crevicular fluid interleukin-1beta, tumor necrosis factor-alpha, and interleukin-6 levels in renal transplant patients receiving cyclosporine A. *Journal of periodontology* 1998;69:784-790.

139. Williamson MS, Miller EK, Plemons J, Rees T, Iacopino AM. Cyclosporine A upregulates interleukin-6 gene expression in human gingiva: possible mechanism for gingival overgrowth. *Journal of periodontology* 1994;65:895-903.

140. Suzuki AM, Yoshimura A, Ozaki Y, Kaneko T, Hara Y. Cyclosporin A and phenytoin modulate inflammatory responses. *Journal of dental research* 2009;88:1131-1136.

141. Cota LO, Viana MB, Moreira PR, et al. Gingival overgrowth in cyclosporine, tacrolimus, or sirolimus-based immunosuppressive regimens and the single nucleotide IL-6 (-174 G/C) gene polymorphism. *Archives of oral biology* 2010;55:494-501.

142. Drozdzik M, Kurzawski M, Drozdzik A, Kotrych K, Banach J, Pawlik A. Interleukin-6 gene polymorphism in renal transplant patients with and without gingival overgrowth. *Journal of clinical periodontology* 2005;32:955-958.

143. Zeilhofer HU, Schorr W. Role of interleukin-8 in neutrophil signaling. *Current opinion in hematology* 2000;7:178-182.

144. Murakami R, Kambe F, Mitsuyama H, et al. Cyclosporin A enhances interleukin-8 expression by inducing activator protein-1 in human aortic smooth muscle cells. *Arteriosclerosis, thrombosis, and vascular biology* 2003;23:2034-2040.

145. Shahzad A, Knapp M, Lang I, Kohler G. Interleukin 8 (IL-8) - a universal biomarker? *International archives of medicine* 2010;3:11.

146. Iacopino AM, Doxey D, Cutler CW, et al. Phenytoin and cyclosporine A specifically regulate macrophage phenotype and expression of platelet-derived growth factor and interleukin-1 in vitro and in vivo: possible molecular mechanism of drug-induced gingival hyperplasia. *Journal of periodontology* 1997;68:73-83.

147. Blazevic T, Schwaiberger AV, Schreiner CE, et al. 12/15-Lipoxygenase Contributes to Platelet-derived Growth Factor-induced Activation of Signal Transducer and Activator of Transcription 3. *The Journal of biological chemistry* 2013;288:35592-35603.

148. Nares S, Ng MC, Dill RE, Park B, Cutler CW, Iacopino AM. Cyclosporine A upregulates platelet-derived growth factor B chain in hyperplastic human gingiva. *Journal of periodontology* 1996;67:271-278.

149. Plemons JM, Dill RE, Rees TD, Dyer BJ, Ng MC, Iacopino AM. PDGF-B producing cells and PDGF-B gene expression in normal gingival and cyclosporine A-induced gingival overgrowth. *Journal of periodontology* 1996;67:264-270.

150. Kantarci A, Nseir Z, Kim YS, Sume SS, Trackman PC. Loss of basement membrane integrity in human gingival overgrowth. *Journal of dental research* 2011;90:887-893.

151. Carew RM, Wang B, Kantharidis P. The role of EMT in renal fibrosis. *Cell and tissue research* 2012;347:103-116.

152. Choi SS, Diehl AM. Epithelial-to-mesenchymal transitions in the liver. *Hepatology* 2009;50:2007-2013.

153. Lekkerkerker AN, Aarbiou J, van Es T, Janssen RA. Cellular players in lung fibrosis. *Current pharmaceutical design* 2012;18:4093-4102.

154. Hereditary Gingival Fibromatosis. Available at: http://www.omim.org/entry/135300 - contributors-shutter. Accessed: 3/16, 2014.

155. Bostrom A, Bharath H, Saulewicz A, Narayanan AS. Cyclosporin a affects signaling events differentially in human gingival fibroblasts. *Journal of dental research* 2005;84:532-536.

156. Iwaisako K, Brenner DA, Kisseleva T. What's new in liver fibrosis? The origin of myofibroblasts in liver fibrosis. *Journal of gastroenterology and hepatology* 2012;27 Suppl 2:65-68.

157. Quigley GA, Hein JW. Comparative cleansing efficiency of manual and power brushing. *Journal of the American Dental Association* 1962;65:26-29.

158. Muhlemann HR. Psychological and chemical mediators of gingival health. *The Journal of preventive dentistry* 1977;4:6-17.

159. Ashburner M, Ball CA, Blake JA, et al. Gene ontology: tool for the unification of biology. The Gene Ontology Consortium. *Nature genetics* 2000;25:25-29.

160. Kanehisa M, Goto S, Kawashima S, Okuno Y, Hattori M. The KEGG resource for deciphering the genome. *Nucleic acids research* 2004;32:D277-280.

161. Zimmermann HW, Seidler S, Gassler N, et al. Interleukin-8 is activated in patients with chronic liver diseases and associated with hepatic macrophage accumulation in human liver fibrosis. *PloS one* 2011;6:e21381.

162. Lonnemann G, Engler-Blum G, Muller GA, Koch KM, Dinarello CA. Cytokines in human renal interstitial fibrosis. II. Intrinsic interleukin (IL)-1 synthesis and IL-1-dependent production of IL-6 and IL-8 by cultured kidney fibroblasts. *Kidney international* 1995;47:845-854.

163. Sheu JN, Chen SM, Meng MH, Lue KH. The role of serum and urine interleukin-8 on acute pyelonephritis and subsequent renal scarring in children. *The Pediatric infectious disease journal* 2009;28:885-890.

164. Ziegenhagen MW, Zabel P, Zissel G, Schlaak M, Muller-Quernheim J. Serum level of interleukin 8 is elevated in idiopathic pulmonary fibrosis and indicates disease activity. *American journal of respiratory and critical care medicine* 1998;157:762-768.

165. Wang J, Hori K, Ding J, et al. Toll-like receptors expressed by dermal fibroblasts contribute to hypertrophic scarring. *Journal of cellular physiology* 2011;226:1265-1273.

166. Gardet A, Zheng TS, Viney JL. Genetic architecture of human fibrotic diseases: disease risk and disease progression. *Frontiers in pharmacology* 2013;4:159.

167. Szpaderska AM, Zuckerman JD, DiPietro LA. Differential injury responses in oral mucosal and cutaneous wounds. *Journal of dental research* 2003;82:621-626.

168. Eslami A, Gallant-Behm CL, Hart DA, et al. Expression of integrin alphavbeta6 and TGF-beta in scarless vs scar-forming wound healing. *The journal of histochemistry and cytochemistry : official journal of the Histochemistry Society* 2009;57:543-557.

169. Clark RAF. The molecular and cellular biology of wound repair. In. New York: Plenum Press, 1998.

170. Kantarci A, Black SA, Xydas CE, et al. Epithelial and connective tissue cell CTGF/CCN2 expression in gingival fibrosis. *The Journal of pathology* 2006;210:59-66.

171. Keane MP, Arenberg DA, Lynch JP, 3rd, et al. The CXC chemokines, IL-8 and IP-10, regulate angiogenic activity in idiopathic pulmonary fibrosis. *Journal of immunology* 1997;159:1437-1443.

172. Li A, Dubey S, Varney ML, Dave BJ, Singh RK. IL-8 directly enhanced endothelial cell survival, proliferation, and matrix metalloproteinases production and regulated angiogenesis. *Journal of immunology* 2003;170:3369-3376.

173. Heidemann J, Ogawa H, Dwinell MB, et al. Angiogenic effects of interleukin 8 (CXCL8) in human intestinal microvascular endothelial cells are mediated by CXCR2. *The Journal of biological chemistry* 2003;278:8508-8515.

174. Fernando RI, Castillo MD, Litzinger M, Hamilton DH, Palena C. IL-8 signaling plays a critical role in the epithelial-mesenchymal transition of human carcinoma cells. *Cancer research* 2011;71:5296-5306.

175. Palena C, Hamilton DH, Fernando RI. Influence of IL-8 on the epithelial-mesenchymal transition and the tumor microenvironment. *Future oncology* 2012;8:713-722.

176. Moore BB, Murray L, Das A, Wilke CA, Herrygers AB, Toews GB. The role of CCL12 in the recruitment of fibrocytes and lung fibrosis. *American journal of respiratory cell and molecular biology* 2006;35:175-181.

177. Peng H, Herzog EL. Fibrocytes: emerging effector cells in chronic inflammation. *Current opinion in pharmacology* 2012;12:491-496.

178. Vakil V, Sung JJ, Piecychna M, et al. Gadolinium-containing magnetic resonance image contrast agent promotes fibrocyte differentiation. *Journal of magnetic resonance imaging : JMRI* 2009;30:1284-1288.

179. Mehrad B, Burdick MD, Zisman DA, Keane MP, Belperio JA, Strieter RM. Circulating peripheral blood fibrocytes in human fibrotic interstitial lung disease. *Biochemical and biophysical research communications* 2007;353:104-108.

180. Khoshnoodi J, Pedchenko V, Hudson BG. Mammalian collagen IV. *Microscopy research and technique* 2008;71:357-370.

181. Green SJ. Personal Communication. In. Chicago, IL, 2013.

182. Seibert JL, J. . *Esthetics and periodontal therapy. In: Textbook of clinical periodontology*. Copenhagen: Munksgaard; 1989.

183. Muller HP, Eger T. Gingival phenotypes in young male adults. *Journal of clinical periodontology* 1997;24:65-71.

184. De Rouck T, Eghbali R, Collys K, De Bruyn H, Cosyn J. The gingival biotype revisited: transparency of the periodontal probe through the gingival margin as a method to discriminate thin from thick gingiva. *Journal of clinical periodontology* 2009;36:428-433.

APPENDICIES

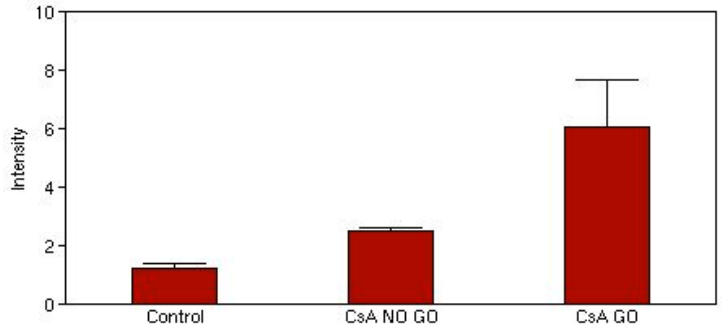

Appendix A. Differential expression of IL-1β

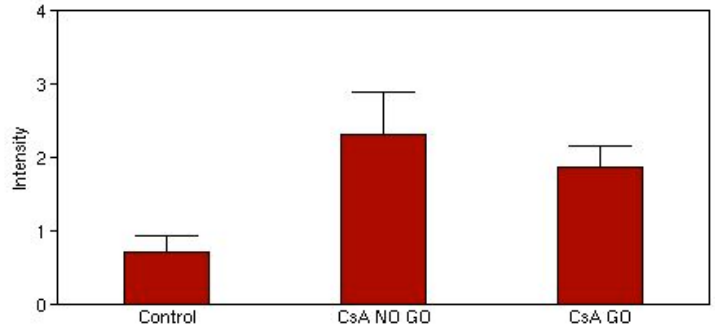

Appendix B. Differential expression of IL-1α

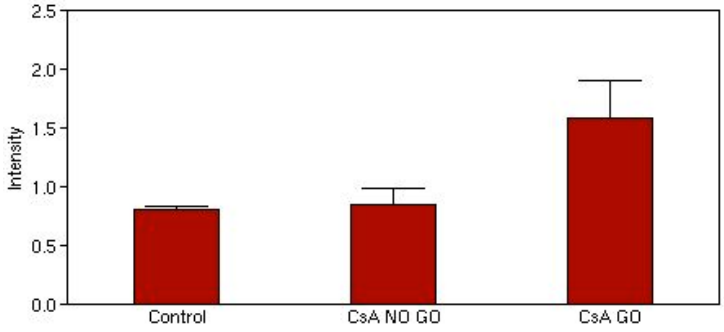

Appendix C. Differential expression of IL-6

APPENDICIES (continued)

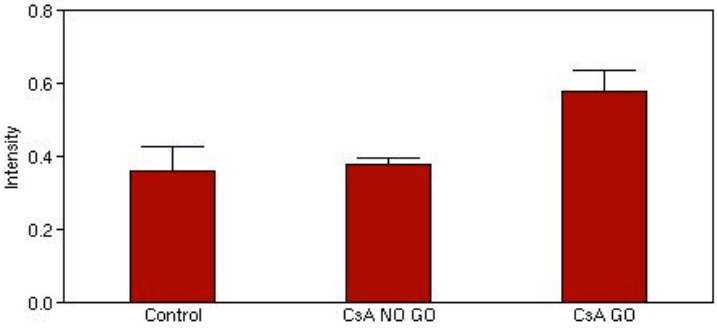

Appendix D. Differential expression of TGF- β1

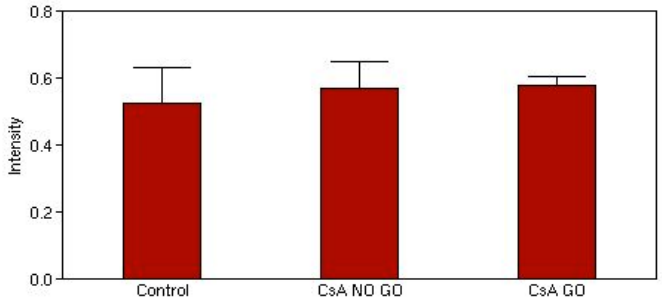

Appendix E. Differential expression of PDGF-B

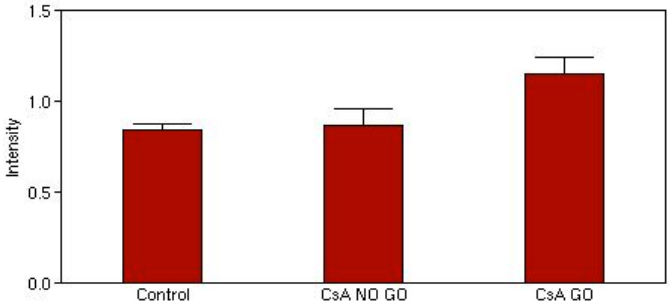

Appendix F. Differential expression of Collagen Type I

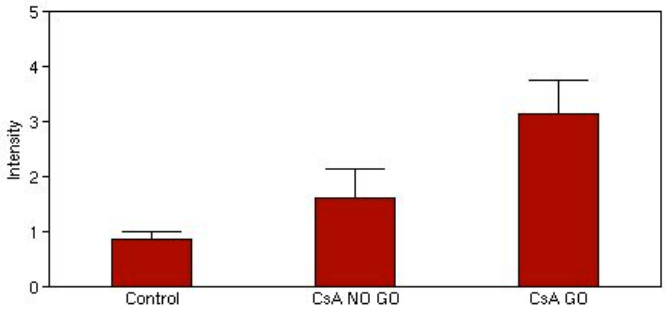

Appendix G. Differential expression of Collagen Type IV

APPENDICES (continued)

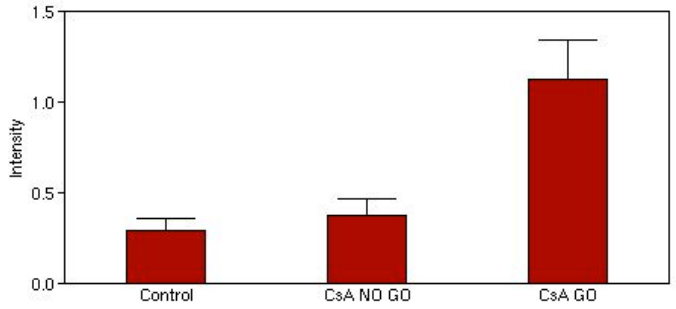

Appendix H. Differential Expression of MMP-1

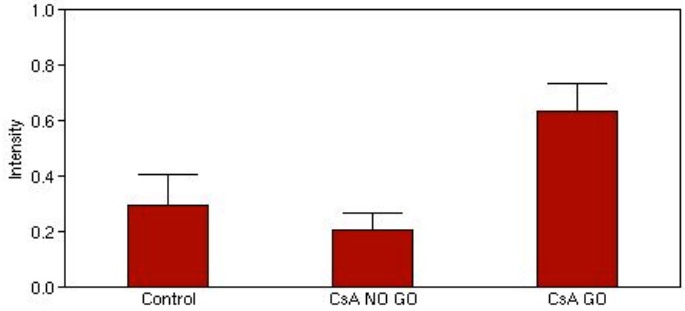

Appendix I. Differential expression of MMP-2

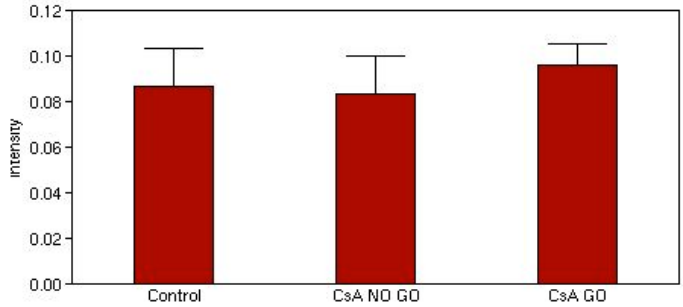

Appendix J. Differential expression of MMP-8

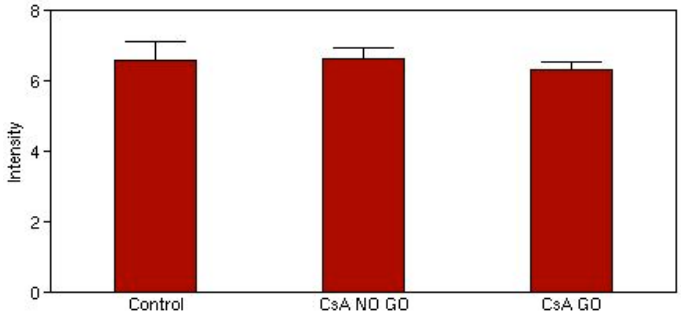

Appendix K. Differential expression of MMP-10

APPENDICES (continued)

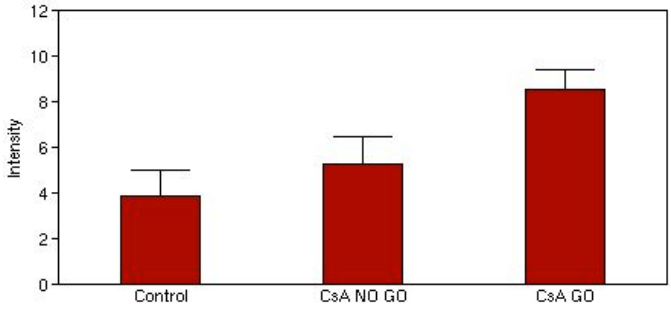

Appendix L. Differential expression of TIMP-1

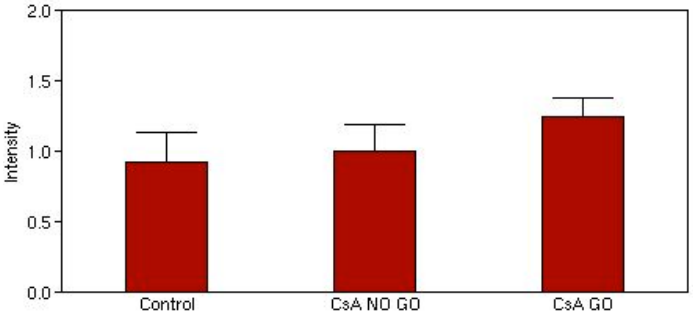

Appendix M. Differential expression of TIMP-2

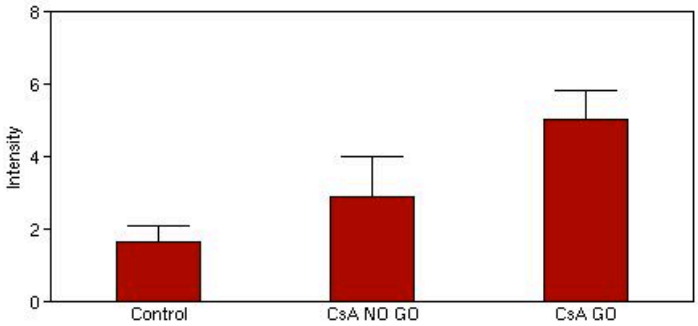

Appendix N. Differential expression of CTGF

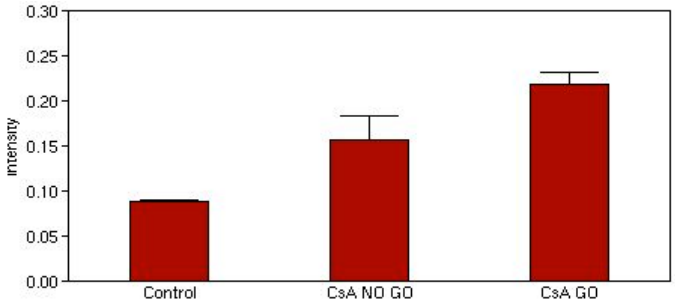

Appendix O. Differential expression of Caspase-3

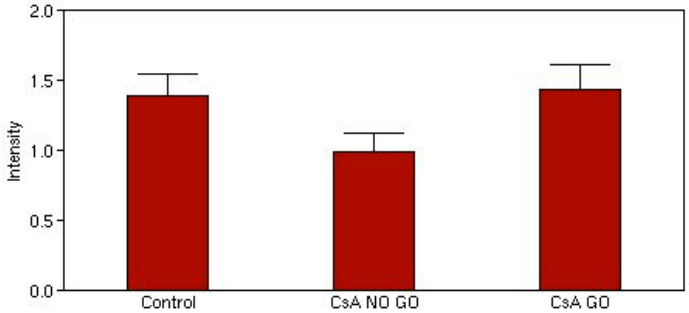

Appendix P. Differential expression of FOXO-1

APPENDICES (continued)

Appendix Q
RELATIVE EXPRESSION OF GENES ASSOCIATED WITH CSA-INDUCED GO

Gene	Control	CsA no GO	CsA GO
IL-1β	1.25 ± 0.15	2.50 ± 0.13	6.06 ± 1.63
IL-1α	0.71 ± 0.21	2.31 ± 0.58	1.86 ± 0.30
IL-6	0.81 ± 0.03	0.85 ± 0.13	1.58 ± 0.33
TGF-β1	0.36 ± 0.07	0.38 ± 0.02	0.58 ±0.06
PDGF-B	0.53 ± 0.11	0.57 ± 0.08	0.58 ± 0.02
Collagen Type I	0.84 ± 0.03	0.87 ± 0.09	1.15 ± 0.09
Collagen Type IV	0.87 ± 0.14	1.602 ± 0.55	3.13 ± 0.64
MMP-1	0.29 ± 0.07	0.38 ± 0.10	1.12 ± 0.22
MMP-2	0.30 ± 0.11	0.21 ± 0.06	0.64 ± 0.10
MMP-8	0.09 ± 0.02	0.08 ± 0.02	0.10 ± 0.01
MMP-10	6.56 ± 0.56	6.63 ± 0.31	6.31 ± 0.21
TIMP-1	3.84 ± 1.13	5.24 ± 1.24	8.55 ± 0.85
TIMP-2	0.92 ± 0.21	1.00 ± 0.20	1.24 ± 0.14
CTGF	1.64 ± 0.43	2.90 ± 1.08	5.03 ± 0.77
Caspase-3	0.09 ± 0.00	0.16 ± 0.03	0.22 ± 0.01
FOXO-1	1.39 ± 0.15	0.99 ± 0.13	1.43 ± 0.18

APPENDICES (continued)

Appendix R

Leave box empty - For office use only

STARTS APPROVAL EXPIRES

JAN 08 2013 TO JAN 09 2014

UNIVERSITY OF ILLINOIS AT CHICAGO
INSTITUTIONAL REVIEW BOARD

University of Illinois at Chicago
Research Information and Consent for Participation in Biomedical Research
Gene and Protein Expression in Gingival Tissue

You are being asked to participate in a research study. Researchers are required to provide a consent form such as this one to tell you about the research, to explain that taking part is voluntary, to describe the risks and benefits of participation, and to help you to make an informed decision. You should feel free to ask the researchers any questions you may have.

Principal Investigator Name and Title: Thomas Hart, DDS, PhD
Department: Periodontics M/C 859
Address and Contact Information: 801 S. Paulina St. Chicago, Illinois, 60612
Emergency Contact Name and Information: Dr. Thomas Hart, 312-413-4467

Why am I being asked?

You are being asked to be a subject in a research study of gum disease. We will be looking for differences in the gum tissues of patients that have gum disease and those that do not. The study will utilize small pieces of gum tissue that are usually discarded during gum/oral surgery. We will study gene and protein expression in gum tissues from patients with and without gum disease.

You have been asked to participate in the research because your dental care includes surgical treatment where small pieces of gum tissue are normally discarded as part of the procedure.

Your participation in this research is voluntary. Your decision whether or not to participate will not affect your current or future dealings with the University of Illinois at Chicago. **If you decide to participate, you are free to withdraw at any time without affecting that relationship.**

Approximately 100 subjects may be involved in this research at UIC.

Appendix R

What other options are there?

You have the option not to participate in this study.

What about privacy and confidentiality?

The people who will know that you are a research subject are members of the research team, and if appropriate, your periodontist and dental assistant. No information about you, or provided by you, during the research, will be disclosed to others without your written permission, except if necessary to protect your rights or welfare (for example, if you are injured and need emergency care or when the UIC Office for the Protection of Research Subjects monitors the research or consent process) or if required by law.

The consent form signed by you will be looked at and/or copied for examining the research by: Dr. Thomas Hart.

A possible risk of the research is that your participation in the research or information about you and your health might become known to individuals outside the research. This is unlikely as once the tissue is collected the only information that will be associated with it will be an arbitrary number and your diagnosis [i.e. periodontitis (gum disease) or periodontally healthy (healthy gums)]. No information about you that identifies you will be associated with the tissue sample. The only reference to your personal information will be the consent form and a note in your dental chart that you agreed to participate in the study.

When the results of the research are published or discussed in conferences, no information will be included that would reveal your identity.

What if I am injured as a result of my participation?

Injury is not anticipated as part of this study as you are only being asked to allow us to study small pieces of gum tissue removed during your gum surgery that would otherwise be discarded.

What are the costs for participating in this research?

There are no costs to you for participating in this research.

Will I be reimbursed for any of my expenses or paid for my participation in this research?

You will not be offered payment for being in this study.

Will my cells, tissues, blood, or other biological materials be used to develop commercial products?

Your gum tissue will not be used to develop commercial products.

APPENDICES (continued)

Appendix R

Your participation in this research is voluntary. Your decision whether or not to participate will not affect your current or future relations with the University. If you decide to participate, you are free to withdraw at any time without affecting that relationship.

Signature of Subject or Legally Authorized Representative

I have read (or someone has read to me) the above information. I have been given an opportunity to ask questions and my questions have been answered to my satisfaction. I agree to participate in this research. I will be given a copy of this signed and dated form.

_____ _____
Signature Date

_____
Printed Name

_____ _____
Signature of Person Obtaining Consent Date (must be same as subject's)

_____
Printed Name of Person Obtaining Consent

VITA

NAME:	Charles Collins DiFranco
EDUCATION:	B.A., Zoology, Miami University, Oxford, Ohio 2007
	D.D.S., University of Illinois at Chicago, College of Dentistry, 2011
	Certificate, Postgraduate Periodontics, University of Illinois at Chicago, College of Dentistry, 2014
TEACHING:	Department of Periodontology, University of Illinois at Chicago EXPERIENCE: Clinical instructor for pre-doctoral students
HONORS:	Volpe Research Prize Finalist, 2013
PROFESSIONAL MEMBERSHIP:	American Academy of Periodontology Illinois Society of Periodontists Midwest Society of Periodontology Chicago Dental Society Delta Sigma Delta Fraternity