Risk Factors for the Development of Ocular Complications

in Herpes Zoster Ophthalmicus

BY

ANN-MARIE LOBO-CHAN
B.A., Rice University, 2001
M.D., Louisiana State Health Sciences Center, New Orleans, 2005

THESIS

Submitted as partial fulfillment of the requirements
for the degree of Masters of Science in Public Health Sciences (Epidemiology)
in the Graduate College of the
University of Illinois at Chicago, 2020

Chicago, Illinois

Defense Committee:

Supriya Mehta, Chair and Advisor
Sreenivas Konda, Biostatistics
Deepak Shukla, Microbiology and Immunology

This thesis is dedicated to my husband for his unfailing support and to my daughter for inspiring me with her curiosity.

ACKNOWLEDGMENTS

I would like to acknowledge my thesis committee for their guidance and support in writing this thesis. I would especially like to acknowledge my advisor, Supriya Mehta, PhD, for her time and effort in helping me to understand and appreciate the field of epidemiology. I would also like to acknowledge my advisor, Deepak Shukla, PhD, for his support and encouragement in my ventures in the field of translational research and herpetic eye disease.

I would like to acknowledge Joelle Hallak, PhD, and Rawan Rupnow, MS, for their assistance with statistical support. I would like to thank Ms. Margaret Chervinko, MLS, for her assistance with literature searches and journal article retrieval.

TABLE OF CONTENTS

CHAPTER			PAGE
I.	INTRODUCTION		1
	A.	Background: Herpes Zoster	1
		1. Pathogenesis and Immune Response in VZV	2
	B.	Background: Herpes Zoster Ophthalmicus	3
		1. Ocular complications from HZO	4
		2. Other complications in HZO	5
	C.	Epidemiology of HZ and HZO	5
	D.	Risk Factors for HZ and HZO	7
		1. Risk factors for ocular complications in HZO	9
	E.	Vaccination for HZ	10
	F.	HZ and HZO: a Public Health Problem	12
	G.	Purpose of the Study	13
		1. Specific aim A	13
		2. Specific aim B	13
		3. Specific aim C	14
	H.	Significance of the Study	14
II.	METHODS AND CONCEPTUAL MODEL		15
	A.	Study Design	15
	B.	Data Source, Data Collected and Associated Variables	15
	C.	Definition of Outcome and Inclusion/Exclusion Criteria	15
	D.	Conceptual Model	16
	E.	Statistical Analysis	18
		1. Specific aim A	18
		2. Specific aim B	18
		3. Specific aim C	19
III.	RESULTS		20
	A.	Specific Aim A: HZ and HZO Incidence	20
	B.	Specific Aim B: Ocular Complications and Risk Factors for Ocular Complications	20
	C.	Specific Aim C: Vaccination Data	26
IV.	DISCUSSION		27
	A.	Gender in HZ/HZO	27
	B.	Initial Eye Findings as Risk Factors for Complications in HZO	28
	C.	Vaccination	31
	D.	Limitations	32
V.	CONCLUSIONS AND FUTURE DIRECTIONS		35

TABLE OF CONTENTS (continued)

CHAPTER	PAGE
CITED LITERATURE……	36
VITA……	40

LIST OF TABLES

TABLE PAGE

I. SUMMARY OF PATIENTS WITH HERPES ZOSTER DIAGNOSIS AT UIH….. 22

II. SUMMARY OF HZO PATIENT CHARACTERISTICS OVERALL AND BY COMPLICATION …….. 23

III. SUMMARY OF OCULAR COMPLICATIONS AT 6 MONTHS AND 1 YEAR….. 25

IV. RISK OF DEVELOPMENT OF OCULAR COMPLICATIONS IN HZO……. 25

LIST OF FIGURES

FIGURE		PAGE
1.	Conceptual model of the risk factors associated with development of ocular complications in HZO……	17
2.	Time course for patients with HZ and shingles vaccination.....	26

LIST OF ABBREVIATIONS

HZ	Herpes zoster
HZO	Herpes zoster ophthalmicus
ICD-9	International Classification of Diseases, 9th revision
PHN	Post-herpetic neuralgia
RZV	Recombinant zoster vaccine
VA	Visual acuity
VZV	Varicella zoster virus
ZVL	Zoster Live Vaccine

SUMMARY

Herpes zoster (HZ), also known as shingles, is the reactivation of the varicella zoster virus (VZV) characterized by a painful vesicular rash in a dermatomal distribution. When HZ affects the first branch of the trigeminal nerve, it causes herpes zoster ophthalmicus (HZO). Both HZ and HZO are more frequently seen in older populations, although in recent years, the mean age of HZ has been declining. HZ and HZO can be associated with significant complications, including cardiovascular events and ocular complications that can result in vision loss. Antiviral therapy is used once HZ/HZO has developed, but there are now 2 vaccines available for prevention of shingles. The purpose of this study is to report the incidence rates of HZ and HZO in a large, urban hospital system and to determine risk factors that are associated with the development of ocular complications in HZO. A secondary objective is to report the frequency of shingles vaccination and any episodes of HZ reactivation following shingles vaccination in this patient population.

A retrospective cohort study was performed on patients seen at the University of Illinois Hospital system between 2010-2015 diagnosed with HZ or HZO as identified by International Classification of Diseases, 9th revision code. Medical chart review of HZO patients seen within 1 year of diagnosis of disease was performed.

During the study time period, 1365 patients with HZ and 269 patients with HZO were identified by diagnosis code. There were 93 patients with HZO with

ocular involvement analyzed. The mean age was 57.8 years, and patients were predominantly female (55.9%), non-Hispanic Caucasian (39.8%), and immunocompetent (79.1%). Ocular complications, including corneal scarring, reduced corneal sensation, and keratitis were seen in 25 (27%) patients. Complications were more frequently observed in female Caucasian patients originally seen in the eye clinics with stromal keratitis on initial presentation. Using multivariable logistic regression models, female gender and stromal keratitis were significantly associated with higher odds of development of ocular complications.

Shingles vaccination rates were low in this patient population (0.4%); fortunately, reactivation of HZ associated with shingles vaccination was also low. There were only 4 cases of reactivation of HZ following 687 patients with recorded shingles vaccination; 2 cases were of HZO in patients with underlying systemic immunosuppression developing 2 years following vaccination.

HZ and HZO represent a major public health concern. Characterizing the epidemiology of cases and risk factors for development of complications will help to strategize treatment and vaccine prevention programs.

I. INTRODUCTION

A. Background: Herpes Zoster

Herpes zoster (HZ) or shingles occurs with reactivation of the varicella zoster virus (VZV), also known as the chicken pox virus. The virus reactivates along sensory nerves in a dermatomal distribution in individuals who have previously had VZV or have been vaccinated against VZV. Up to 20% of cases of shingles occur along the ophthalmic division of the trigeminal nerve (V1), also known as herpes zoster ophthalmicus (HZO).[1] It is estimated that 1 in 3 individuals will develop shingles during their lifetime.[2] The hallmark clinical presentation of shingles is a painful, vesicular rash in a dermatomal distribution, which can last for several weeks. Oral antiviral therapy is initiated within 72 hours of the appearance of the vesicular lesions to decrease the duration of the attack, the amount of viral shedding and the severity of acute pain. Antiviral therapy has also been shown to help prevent or lessen the severity of subsequent complications, including pain associated with post-herpetic neuralgia.[3]

In addition to the morbidity associated with the painful, vesicular rash, shingles has also been linked to increased risk for vascular events, including cerebrovascular accidents or myocardial infarction. Risk for stroke is even higher in cases of HZO with reports of a 2 to 4 times increased odds of cerebrovascular accident within 1 year following HZO, but returns to baseline after 12 months.[4,5] The

trigeminal ganglion is in close anatomical location to the cerebral arteries, which may be why HZO poses an even greater risk for stroke.

1. Pathogenesis and Immune Response in VZV

Varicella zoster virus is a member of the alpha herpesvirus family that infects humans. Similar to the herpes simplex virus, VZV is composed of a linear double-stranded DNA genome contained within an icosahedral nucleocapsid core surrounded by a lipid envelope with glycoproteins that help the virus bind to other cells. Primary VZV infection is transmitted through respiratory secretions, including aerosolized transmission from skin lesions; viral particles replicate in epithelial cells in the respiratory mucosal tissue with subsequent spread to lymphoid tissues and hematogenous spread to the skin leading to a disseminated rash.[6] Latent infection is established in sensory ganglia, including the trigeminal and dorsal root ganglia. With reactivation of VZV, viral particles begin to replicate and travel down the peripheral nerve from the ganglion until reaching the skin and manifesting as HZ.

Both innate and adaptive immune responses play an important role in the human host's response to VZV. As part of the innate immune system, cell surface receptors detect VZV particles, activating transcription factors such as nuclear factor kappa enhancer of B cells (NF-κB) with expression of type I interferons and pro-inflammatory cytokines that recruit other inflammatory cells.[7] Innate immune cells, including natural killer cells, inhibit viral replication. These innate immune responses can occur in both the skin and in sensory ganglia.

Humoral and T cell-mediated adaptive immune responses are also important mediators in control of VZV infection and reactivation. Antibodies to VZV

(immunoglobulin) are protective against primary infection and reactivation of VZV. Immunoglobulins bind to VZV protein regions, including glycoprotein E, which is the target antigen in the new recombinant HZ vaccine. Deficiency of CD4 and CD8 T cells leads to more severe VZV infection; after infection, CD4 T cell memory is detectable for many years after infection.[7] These CD4 T memory cells may be increased with repeat exposure or subclinical infection. Both adaptive and innate immune responses can decline with age, making individuals more susceptible to reactivation of latent VZV infection in the form of HZ.

B. Background: Herpes Zoster Ophthalmicus

Herpes zoster ophthalmicus can be classified as HZO with eye involvement or without eye involvement. HZO with eye involvement, which occurred in more than 50% of cases in the era before antiviral therapy, is associated with significant ocular morbidity, including eye pain and vision loss. Herpes zoster ophthalmicus has been associated with the development of significant ocular complications in 50-71% of cases, including keratitis and uveitis, beyond the acute phase of the vesicular rash.[8,9] Even in the post-antiviral era, up to 30-65% of cases of HZO can develop eye involvement.[9,10] During the acute phase of HZO, patients may have clinical signs of eyelid vesicles, conjunctivitis, corneal inflammation or keratitis and/or intraocular inflammation (uveitis). Keratitis can involve the corneal epithelium with pseudodendritic lesions containing live virus similar to a skin vesicle; other types of corneal inflammation include stromal keratitis and endothelial keratitis with resultant corneal edema which can lead to visual compromise. Cranial nerve palsies affecting the extraocular muscles and less commonly posterior segment

inflammation, including retinitis, optic neuritis or vasculitis may occur. Up to 20% of patients can develop chronic or recurrent HZO with episodes of keratitis or uveitis.[10] Recurrent episodes of keratitis can lead to corneal scarring and vision loss. In both acute and chronic phases of infection, viral infiltration as well as the subsequent inflammatory cascade, vasculitis, and neuropathy can lead to the development of significant complications and ocular morbidity.

1. Ocular Complications from HZO

From the initial presentation of HZO, various ocular complications can develop. The vesicular skin rash can lead to scarring of the eyelids with resultant inadequate eyelid closure or lagophthalmos. This lagophthalmos can lead to problems with exposure of the corneal surface or exposure keratopathy. Conjunctivitis can also lead to cicatricial or scarring changes along the ocular surface, although this is rare.

The cornea is the most common site of development of ocular complications related to HZO; these complications can occur during or soon after the acute episode of HZO or months to years later.[11] Herpes zoster ophthalmicus has been characterized by an 1) acute phase with active disease within the first 90 days after the initial rash followed by disease quiescence and 2) chronic HZO which includes active disease requiring antiviral or anti-inflammatory therapy for more than 90 days after the initial rash.[10] Recurrences of inflammation in HZO are more common within the first 2 years following initial presentation and in one study, 30% of patients treated with antivirals for acute HZO developed ocular complications within 6 months.[12,13] Herpes zoster ophthalmicus can lead to damage to corneal

nerves with reduced corneal sensation and subsequent neurotrophic keratitis. Reduced corneal sensation can make HZO patients susceptible to infectious keratitis, corneal epithelial breakdown, corneal scarring, and even corneal perforation, which can all result in vision loss. HZO patients may also develop recurrent stromal keratitis which is associated with corneal edema and progressive opacification of the cornea. Neovascularization or the development of abnormal blood vessels in the otherwise clear cornea can also develop with recurrent corneal inflammation. Other complications associated with HZO that may lead to vision loss include glaucoma and uveitis.

2. Other complications in HZO

In addition to ocular morbidity related to HZO and increased risk of stroke, there have also been studies on increased risk of cancer in patients with HZO. In one population-based study, there was a 9 times increased risk for cancer in patients with HZO compared to a comparison cohort, with female patients being at even higher risk than male patients.[14] This increased risk of malignancy may be related to a decline in host immunity that may make patients more susceptible to reactivation of VZV as well as development of cancer.

C. Epidemiology of HZ and HZO

Shingles is not a reportable infectious disease; therefore, the majority of studies on the epidemiology of HZ and HZO are based on population-based studies from health systems databases, including insurance and hospital databases. These studies may underestimate the incidence and prevalence of disease as individuals

may choose not to seek care or may have an incorrect diagnosis code reported. This can be particularly true for cases of HZO as HZO may sometimes be miscoded as herpes simplex keratitis. However, one study using a Kaiser Permanente Hawaii health database reported a 91% positive predictive value for the use of an ICD-9 diagnosis code to correctly identify cases of HZO, with 138 of 152 cases identified by ICD-9 code confirmed by medical record review.[15]

The incidence of HZ in the general population has been increasing since the early 1990s.[16] Population-based studies have examined the incidence of HZO, with overall incidence rates of 30.9 per 100,000; however, incidence increases to 104.6 per 100,000 for populations older than 65 years of age.[17] A recent insurance claims based study demonstrated an annual 3.6% increased incidence of HZO since 1994 in the United States; during this time, rates of HZO declined in younger (<21 years) and older (>60 years) age groups, but increased in middle aged individuals. [18] In global surveys of HZ, there has also been an increase in the incidence of HZ, primarily in individuals older than age 40, with the highest incidence of cases still occurring in those over age 60.[19] Although there have been many postulated explanations for this increase in the incidence of HZ, including the use of varicella vaccination in children, the increased prevalence of immunocompromised patients and patients with chronic disease, and changes in health seeking behavior, there have been no studies confirming these hypotheses.

A study examining differences in the age at presentation of HZO in the era before and after varicella vaccination demonstrated that there was a younger age of onset in the time period from 2006-2012 (after vaccination) compared to 1996-

2004.[20] Almost 30% of patients were younger than 50 years of age in the later time period compared to 16% before 2005. The mean age at presentation of acute HZO was noted to decline from 61.2 in 2007 to 55.8 in 2013 in a retrospective study from a tertiary eye hospital in Boston.[21] Both of these studies postulated that there was a relationship between varicella vaccination and declining age of presentation of HZO.

The epidemiology of ocular complications associated with HZO varies widely by the type of study. One population-based study in Olmstead County, Minnesota examining 7370 patients with any HZ diagnosis demonstrated an eye complication rate of 2.5%.[8] Another study focused on patients with HZO diagnosed at a tertiary care ophthalmic hospital and a large general hospital in Hong Kong demonstrated ocular involvement in 65% of cases.[8,9] Studies from tertiary care eye centers introduce referral bias since more severe cases are likely to be referred here as opposed to population-based studies; however, population-based studies may miss cases not included in the catchment area.

D. Risk Factors for HZ and HZO

The development and severity of HZ is related to a combination of viral and host factors, including virulence of VZV and the host immune response to the virus. Cell-mediated immunity to VZV has been postulated as a major reason for the development of HZ; if T-cell mediated responses to VZV decline, there is risk of reactivation in the form of HZ.[22] Exposure to VZV may increase T-cell mediated immunity; the advent of varicella vaccination and decreased likelihood of exposure to VZV in the population has been implicated as a possible reason for the increased incidence of HZ.

Advanced age has traditionally been a major risk factor for the development and severity of HZ, with an overall increased incidence of cases over age 50 and the mean age of onset of HZ in adults at 59.4 years.[23] The incidence rate of cases of HZO in patients older than age 65 is 5 times the rate of the general population.[17] In spite of declines in the incidence rate in older populations in recent years, older age is still the most significant risk factor for the development of HZ. In one study, smoking was associated with younger age of development of HZO.[20]

Immunosuppressed individuals, including individuals status post organ transplantation, iatrogenically immunosuppressed, or with HIV/AIDs, are also at higher risk of HZ, including more severe or disseminated disease. Immunocompromised patients have a two-fold greater incidence in HZ compared to immunocompetent patients.[24] More severe immunosuppression has been associated with higher incidence of HZ and HZ associated complications. Younger age of onset of HZO may also be associated with concomitant immunosuppressed state.[20]

In some studies, female gender has been associated with higher rates of HZ and HZO,[8,17,18,25] while other studies do not report differences in gender distribution in HZ.[9,12] Age-adjusted rates of HZ are reported to be higher in women.[23] It is unclear why gender may be a risk factor for HZ, but it is likely multifactorial, including gender differences in health-seeking behavior and in immune responses to viral infections. Sex hormones, including estrogens and progesterones, have been shown to decrease VZV-specific lymphocyte proliferation; in a study of HIV infected and non-infected women, there was an increase in T regulatory cells and a decrease in VZV cell-mediated immunity during phases of the menstrual cycle where estrogen

and progesterone were increased.[26] Sex steroid hormones, including estradiol and progesterone have an effect on immune cell function; with menopause, there is a sudden drop in these hormones (compared to men who have a more gradual decrease in testosterone) with subsequent decrease in B and T cells and elevated levels of proinflammatory cytokines.[27] These hormonal changes may play a role in biological mechanisms that may make women more susceptible to reactivation of VZV.

1. Risk factors for ocular complications in HZO

Other risk factors associated with the severity of HZ and development of complications have been studied. One study reported that worsening skin eruption based on the number of vesicular lesions along the distribution of the ophthalmic branch of the trigeminal nerve and the presence of Hutchinson's sign (vesicular lesion on the tip of the nose) were more likely to be associated with ocular involvement and with vision loss in HZO.[28] The type of initial ocular manifestation has been associated with the development of ocular complications and vision loss. Uveitis has been reported to be a risk factor for vision loss and recurrent or chronic disease in HZO. [10,29] In other studies, epithelial keratitis and stromal keratitis were noted to be risk factors for vision loss.[9] Age of onset of HZO may also play a role in the type of clinical presentation, with younger patients more likely to have delayed presentation of epithelial keratitis or pseudodendrites compared to patients older than age 60 who are more likely to have reduced corneal sensation and neutrophic keratopathy.[12]

Antiviral therapy for HZO reduces the likelihood of ocular complications and severe vision loss by 20%.[13] In patients receiving antiviral therapy, time to initiation of therapy was an important factor in reducing likelihood of complications; specifically, a delay in initiation of antiviral therapy (4.8 days compared to 3.8 days) was associated with higher risk of development of more severe ocular complications.[30]

E. Vaccination for HZ

Antiviral therapy may reduce the duration of the acute episode of HZ/HZO, but it does not prevent disease occurrence. In 2006, the first vaccine for HZ, Zostavax ((Zoster Vaccine Live), Merck&Co) (ZVL) was approved by the Food and Drug Administration (FDA) for immunocompetent individuals age 60 and older after demonstrating a 51.3% decrease in the incidence of HZ and a reduction in the burden of disease and incidence of PHN.[31] Zostavax is a live virus vaccine and has been shown to have decreasing efficacy in older individuals with only 37% efficacy in those older than age 70; efficacy was also reported to wane over time to only 30% after 5 years.[32]

It is unclear if ZVL has affected the overall incidence of HZ in older populations since utilization of the ZVL has been low, with reports of only 30.6% coverage in 2015 in the United States.[33] Some contributing factors include need for frozen storage, high cost, and lower awareness or recommendations by primary care providers compared to pneumococcal or influenza vaccines in the elderly. It is contraindicated in immunosuppressed individuals since it is a live vaccine, although it has been used and is reported to be safe in patients on chronic, low-dose

immunosuppressive therapy for autoimmune disease. During post-marketing surveillance, there have been reports of 8.6% of all adverse events involving development of HZ rash, usually within 4 weeks after vaccination; 0.3% of all adverse events involved HZO. [34] Disseminated HZ was rare and mainly seen in immunocompromised patients. Zostavax has also been associated with rare cases of reactivation of VZV involving the posterior segment of the eye as acute retinal necrosis/necrotizing viral retinitis in elderly immunosuppressed patients; 1 patient with diabetes and rheumatoid arthritis, 1 patient with diabetes and endstage renal disease, 1 patient with history of renal transplantation, and 1 patient with diabetes and chronic lymphocytic leukemia.[35-37] Patients had both wild-type and Oka vaccine strain virus detected by polymerase chain reaction testing and all patients had some type of immunosuppression which put them at higher risk given the live virus vaccine.

Shingrix is a recombinant zoster vaccine (RZV) that was approved by the FDA in 2017 after demonstrating efficacy in decreasing the incidence of HZ in all age groups, with overall vaccine efficacy of 97.2%.[38] A second phase 3 study conducted on adults age 70 years and older confirmed efficacy of over 90% with the RZV.[39] The RZV contains the antigen VZV glycoprotein E, which is a primary target of VZV-specific immune responses as well as viral replication and spread. The vaccine is administered over 2 doses 2 months apart; 17% of participants in the phase 3 clinical trials (66% of those receiving RZV compared to placebo) reported side effects, including myalgias and injection site reactions. In safety evaluations in the first 8 months following licensing by the FDA, 3.2 million vaccines were

administered, with reported adverse effects (fever, injection site pain and redness) in up to 23% of individuals.[40]

The RZV has also been studied in immunocompromised populations, including patients who had undergone autologous stem cell transplantation, with decrease in the incidence of HZ in this high risk group.[41] The RZV is also being studied as a promising vaccine to prevent HZ in other high risk groups, including patients with solid organ tumors and patients status post renal transplant.

The age at presentation of HZ and HZO has been studied more recently in the setting of the availability of vaccines to prevent HZ.

F. HZ and HZO: a Public Health Problem

Evidence suggests that there is a rising incidence of HZ and HZO cases. Antiviral therapy does not necessarily prevent the development of complications associated with HZ and HZO, including postherpetic neuralgia and ocular complications. Evidence is still lacking about which patients may be at higher risk for the development of complications related to HZ and HZO and which groups should be targeted for vaccination. Current and past guidelines for shingles vaccination are geared towards individuals older than age 60, even though recent evidence suggests that younger age groups may be at increased risk.

In patients who have developed HZO, it is unclear which presenting clinical signs or other factors may be associated with the development of subsequent ocular complications and morbidity. Knowledge of such risk factors may be helpful in identifying which patients with HZO should be followed more closely or who may benefit from chronic antiviral therapy to prevent further ocular complications.

G. Purpose of the Study

The purpose of this study is to determine the incidence of HZ and HZO in a major urban hospital system and more specifically to determine the risk factors for the development of ocular complications in HZO. A secondary objective is to determine the rate of shingles vaccination and cases of reactivation of shingles following vaccination. These objectives will be completed through the following specific aims.

1. Specific aim A

Specific aim A is to determine the frequency of cases of HZ seen at a large urban hospital system during the study time period and to determine the incidence of HZ and HZO.

2. Specific aim B

Specific aim B is to describe the distribution of cases of HZO seen, including demographic variables and initial ocular exam findings and the type and distribution of ocular complications at 6 month and 1 year time points. Bivariate analysis will be used to compare characteristics of patients with any ocular complication compared to those without complications. Factors that reach statistical significance ($p<0.20$) in the bivariate analysis will be entered in multivariable logistic regression analysis to determine factors associated with the development of ocular complications.

3. Specific aim C

Specific aim C is to report the frequency of shingles vaccinations during the study period and to describe cases of recurrence of HZ or HZO associated with shingles vaccination.

H. Significance of the Study

HZ is a growing public health problem given the increased incidence of disease and significant morbidity and even mortality that may be associated with this condition. This study will characterize the epidemiology of HZ and HZO as well as shingles vaccination rates in a large, urban hospital system. With the advent of newer recombinant shingles vaccination, knowledge of the epidemiology may help to identify target populations for vaccination. Analysis of risk factors for the development of ocular complications in HZO may help to identify patients who need closer monitoring and aggressive therapy for this disease.

II. METHODS AND CONCEPTUAL MODEL

A. Study Design

This study is a retrospective cohort study of patients with herpes zoster seen at University of Illinois Hospitals in Chicago from 2010-2015. Approval for this study was obtained from the Institutional Review Board at the University of Illinois at Chicago (Chicago, IL, USA), and the study was performed in a manner compliant with the Healthcare Insurance Portability and Accountability Act and the tenets put forth in the Declaration of Helsinki.

B. Data Source, Data Collected and Associated Variables

The University of Illinois Clinical Research Data Warehouse (CRDW) was used to perform initial searches for all herpes zoster diagnosis codes (053) based on International Classification of Diseases, Ninth Revision (ICD-9) codes. The CRDW also provided the number of patients seen at UIH during the study period. In addition to diagnosis code, demographic variables, including age, gender, race, ethnicity, and medications were extracted. Medical record numbers were then used to perform medical chart review on all patients who had an HZO diagnosis code (053.20-053.29). Patients who received the shingles vaccination were also identified by CPT code (69780).

C. Definition of Outcome and Inclusion/Exclusion Criteria

For HZO cases, medical chart review was performed to confirm the diagnosis. In addition to demographic information, additional clinical information including medications (antivirals and steroids), initial examination findings (conjunctivitis,

epithelial keratitis, stromal keratitis, endothelial keratitis, uveitis, and skin rash), ocular complications at 6 months and 1 year (corneal scarring, glaucoma, neovascularization of the cornea, decreased corneal sensation, keratitis, uveitis, corneal transplant needed), immunosuppressed status, length of follow up, and visual acuity (VA) at presentation, 6 months and 1 year were recorded.

Inclusion criteria for a complete case of HZO were if patients had examination data available within 1 year of initial diagnosis of HZO. Cases were excluded if there was no ocular involvement (dermatitis/skin findings only), if the case was incorrectly coded, or if initial diagnosis was made at an outside hospital without examination data available or longer than 1 year after initial diagnosis.

The main outcome of interest was the presence of any ocular complication (defined as one or more of the following: corneal scarring, glaucoma, neovascularization of the cornea, decreased corneal sensation, keratitis, uveitis, corneal transplant needed) at either 6 months or 1 year from initial presentation.

D. Conceptual Model

The conceptual model for hypothesized risk factors associated with the development of ocular complications was based on review of previous literature and clinical knowledge (Figure 1).

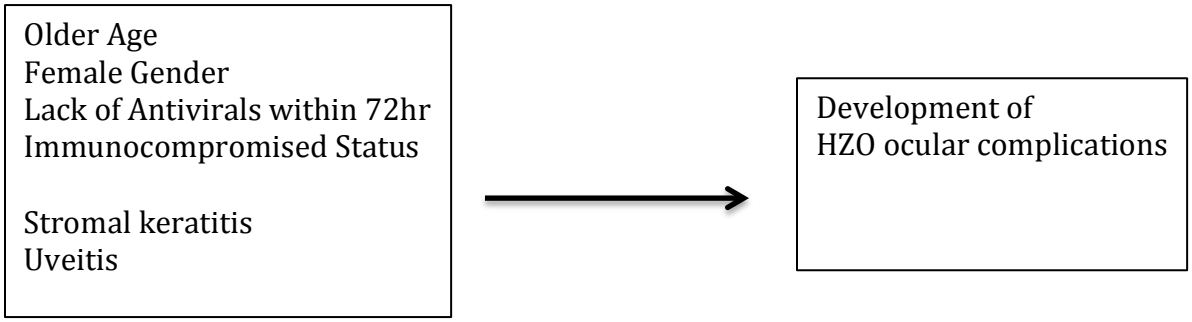

Figure 1. Conceptual model of the risk factors associated with development of ocular complications in HZO

Based on prior studies referenced in the background section, it is hypothesized that older age, female gender, delayed antiviral therapy, and immunocompromised status would be associated with the development of ocular complications in HZO. We hypothesized initial clinical presentation with stromal keratitis and uveitis might also be associated with the development of ocular complications; these clinical findings have been found in other studies to be associated with vision loss and recurrent disease. Mechanisms for these associations are described in detail in the background, but briefly: stromal keratitis is more likely to lead to swelling of the cornea and subsequent corneal opacification, and uveitis can lead to development of scar tissue within the eye and progression of lens opacification or cataract formation, among other sequelae.

E. Statistical Analysis

1. Specific aim A:

The incidence of HZ and HZO cases was calculated by the number of patients with HZ and HZO diagnosis divided by the total number of patients seen at UIH during the time period of the study.

2. Specific aim B:

Of the patients with HZO who were confirmed to be complete cases for the analysis, frequency and means were calculated for categorical and nominal variables, respectively. Bivariate analysis was conducted based on the presence of ocular complications using chi-square test (or Fisher's exact test if frequencies <5) and t-tests for normally distributed continuous variables (or rank sum if non-normally distributed). Prior to statistical analysis with regression models, we checked explanatory variables for collinearity: rash, conjunctivitis, and stromal keratitis were highly correlated and so we used the variable of stromal keratitis because it is more relevant to the pathogenesis of HZO associated ocular complications than conjunctivitis or rash.

Multivariable logistic regression models were used to identify risk factors associated with the development of ocular complications among the explanatory variables. Variables that were significant at $p<0.20$ in bivariate analysis were moved forward to multivariable testing. Using backward selection and based on the conceptual model, variables were removed from the regression model if they failed to reach significance at a level of $p<0.10$.

3. Specific aim C:

The incidence of shingles vaccination was calculated by the number of patients with CPT code for shingles vaccine divided by the total number of patients over age 50 seen at UIH during the time period of the study. Descriptive statistics on the mean time to HZ after vaccination were calculated.

III. RESULTS

A. Specific Aim A: HZ and HZO Incidence

From 2010-2015, there were 1365 patients with a diagnosis of HZ seen at UIH and 411,000 adult patients over age 18 seen during this time period (Table 1). The incidence rate of HZ was 332 per 100,000 (95% CI: 315 – 350 per 100,000). There were 269 (20%) patients with an HZO diagnosis code; of these cases, 48 patients had dermatitis only (no ocular involvement), 99 patients were incorrectly coded, and 122 patients had HZO with ocular involvement, giving an HZO rate of 8.9%. Of those 122 patients with ocular involvement, 27 were excluded from inferential analysis because they did not meet the inclusion criteria for a complete case. Two additional patients were excluded because they were under age 18.

B. Specific Aim B: Ocular Complications and Risk Factors for Ocular Complications

Of the 93 patients with HZO, 25 (27%) developed an ocular complication at either the 6 month or 1 year follow up visit. A summary of the demographic characteristics of the 93 patients with HZO is given in Table 2. The mean age at presentation of HZO was 57.8 years with an equal distribution in patients younger than or older than 60 years of age. There was a higher frequency of female, non-Hispanic Caucasian patients in this cohort. The majority of patients were seen in the eye clinics with 99% of patients receiving antiviral therapy for HZO, and with 60% of patients receiving antiviral therapy within 72 hours of diagnosis. The most common clinical presentation of HZO was conjunctivitis and rash in 58% of patients.

Among those patients with ocular complications, there was a significantly higher frequency of female, Caucasian patients with stromal keratitis compared to those without complications. Visual acuity was worse in patients with ocular complications than in those without at initial, 6 month and 1 year time points, but this did not reach statistical significance. Because visual acuity would be reduced in conditions such as stromal keratitis, this variable was not included in the inferential analysis because of the collinear relationship between these variables.

The distribution of ocular complications at 6 months and 1 year is shown in Table 3. Corneal scarring was the most common complication occurring in 25% of patients with complications.

Based on multivariable logistic regression models shown in Table 4, HZO patients who were female had more than 8 times greater odds of developing ocular complications than males in this cohort when adjusting for age, race, gender, and stromal keratitis. Similarly, HZO patients who presented with stromal keratitis had an 8.4 times greater odds of developing ocular complications than those who did not have stromal keratitis. The final model included only those variables (gender and stromal keratitis) that were significant in the bivariate analysis, remained significant in the adjusted model, and had the lowest AIC demonstrating goodness of fit while remaining the most parsimonious model. Although conjunctivitis appeared to have a protective effect in bivariate analysis, possibly indicating milder disease and lower likelihood of ocular complications, this did not reach statistical significance in the regression models and was left out of the final models because of collinearity with stromal keratitis.

Table I

SUMMARY OF PATIENTS WITH HERPES ZOSTER DIAGNOSIS AT UIH

	N (%)
Number of patients, n	1365
Age, Mean (SD)	52.0 (17.2)
Gender, n (%)	
Female	820 (60.1)
Male	544 (39.9)
Missing	1 (0.1)
Race, n(%)	
Asian/Pacific Islander	67 (4.9)
Black	523 (38.3)
Caucasian	324 (23.7)
Eskimo	2 (0.1)
Hispanic	133 (9.7)
Native Hawaiian	2 (0.1
Other	312 (22.9)
Declined or Missing	2 (0.1)
Ethnicity, n(%)	
Hispanic or Latino	352 (25.8)
Not Hispanic or Latino	978 (71.6)
Declined	32 (2.3)
Missing	3 (0.2)

TABLE II

SUMMARY OF HZO PATIENT CHARACTERISTICS OVERALL AND BY COMPLICATION

	Overall N=93 n (%)	**Any Complication N=25 n (%)**	**No Complication N=68 n (%)**	**P-value**	**Crude OR* (95% CI)**
Age (mean, SD)	57.8 (15.8)	60.9 (13.8)	56.6 (16.4)	0.25	
Age category				0.22	1.79[a]
<60 years	47 (50.5)	10 (21.3)	37 (78.7)		(0.71-4.55)
≥ 60 years	46 (49.5)	15 (32.6)	31 (67.4)		
Gender (n(%))				0.005	4.50
Female	52 (55.9)	20 (38.5)	32 (61.5)		(1.51, 13.37)
Male	41 (44.1)	5 (12.2)	36 (87.8)		
Race				0.02	2.73[b]
Caucasian	37 (39.8)	15 (40.5)	22 (59.5)		(1.05, 7.08)
Asian	3 (3.2)	2 (66.7)	1 (33.3)		
Black	26 (27.4)	4 (15.4)	22 (84.6)		
Eskimo	1 (1.1)	1 (100)	0		
Hispanic	6 (6.5)	0	0		
Other	20 (21.5)	3 (15)	17 (85)		
Ethnicity				0.22	3.10
Non-hispanic	75 (80.7)	23 (30.7)	52 (69.3)		(0.65,14.75)
Hispanic	16 (17.2)	2 (12.5)	14 (87.5)		
Unavailable	2 (2.2)				
Location of Dx				0.0005	7.97[c]
Eye clinic	48 (51.6)	21 (43.7)	27 (56.3)		(2.46, 25.80)
ED	22 (23.7)	1 (4.5)	21 (95.5)		
Other	23 (24.7)	3 (13.0)	20 (87.0)		
Antivirals				0.27	N/A
Yes	89 (98.9)	23 (25.8)	66 (74.2)		
No	1 (1.1)	1 (100)	0		
Steroids				0.73	1.43
Yes	12 (13.5)	4 (33.3)	8 (66.7)		(0.39,5.25)
No	77 (86.5)	20 (26.0)	57 (74.0)		
Immunocompromised				0.54	0.52
No	68 (79.1)	19 (28.0)	49 (72.0)		(0.13, 1.99)
Yes:	18 (21.9)	3 (16.7)	15 (83.3)		
DM	9 (10.5)				
Transplant	1 (1.2)				
HIV/AIDS	5 (5.8)				
Autoimmune	2 (2.3)				
Cancer	1 (1.2)				
Meds within 72hr				0.29	1.73
Yes	53 (60.2)	16 (30.2)	37 (69.8)		(0.63, 4.77)
No	35 (39.8)	7 (20.0)	28 (80.0)		
Conjunctivitis				0.01	0.29
Yes	54 (58.1)	9 (16.7)	45 (83.3)		(0.11, 0.75)
No	39 (41.9)	16 (41.0)	23 (59.0)		
Epithelial Keratitis				0.24	0.56
Yes	39 (41.9)	8 (20.5)	31 (79.5)		(0.21, 1.48)
No	54 (58.1)	17 (31.5)	37 (68.5)		

TABLE II (continued)

SUMMARY OF HZO PATIENT CHARACTERISTICS OVERALL AND BY COMPLICATION

	Overall N=93 n (%)	**Any Complication N=25 n (%)**	**No Complication N=68 n (%)**	**P-value**	**Crude OR* (95% CI)**
Stromal Keratitis				<0.0001	7.14 (2.56, 19.93)
Yes	36 (38.7)	18 (50.0)	18 (50.0)		
No	57 (61.3)	7 (12.3)	50 (87.7)		
Endothelial keratitis				0.54	1.45 (0.44, 4.76)
Yes	15 (16.1)	5 (33.3)	10 (66.7)		
No	78 (83.9)	20 (25.6)	58 (74.4)		
Uveitis				0.31	0.52 (0.17, 1.58)
Yes	27 (29)	5 (18.5)	22 (81.5)		
No	66 (71)	20 (30.3)	46 (69.7)		
Rash				0.002	0.23 (0.08, 0.60)
Yes	54 (58.1)	8(14.8)	46 (85.2)		
No	39 (41.9)	17 (43.6)	22 (56.4)		
Initial logMAR VA	1.2 (1.4)	1.8 (1.9)	0.9 (1.1)	0.09	
6 month logMAR VA	1.1 (1.3)	1.3 (1.6)	0.7 (0.4)	0.68	
1 year logMAR VA	0.9 (1.1)	1.1 (1.2)	0.4 (0.5)	0.18	

[*] Crude odds ratio of any ocular complication for each variable

[a]OR calculated with young age as reference group

[b] OR calculated by comparing Caucasian versus all other race groups.

[c]OR calculated by comparing Eye clinics versus all other locations

TABLE III

SUMMARY OF OCULAR COMPLICATIONS AT 6 MONTHS AND 1 YEAR

	6 month Complication, N=20 n (%)	**1 year Complication, N=23 n (%)**	**Any complication, N=25 n (%)**
Reduced Corneal Sensation	10 (10.8)	9 (9.7)	11 (11.8)
Glaucoma	2 (2.2)	2 (2.2)	2 (2.2)
Corneal scarring	17 (18.3)	21 (22.6)	23 (24.7)
Uveitis	1 (1.1)	2 (2.2)	2 (2.2)
Keratitis	6 (6.5)	12 (12.9)	13 (14)
Transplant needed	1 (1.1)	0	1 (1.1)
Neovascularization of the cornea	1 (1.1)	4 (4.3)	4 (4.3)

TABLE IV

RISK OF DEVELOPMENT OF OCULAR COMPLICATIONS IN HZO

	Crude OR (95% CI)	**Model 1: Full model[a] aOR (95% CI)**	**Model 2: Parsimonious model[b] aOR (95% CI)**	**Model 3: Parsimonious model[c] aOR (95% CI)**
Female Gender	4.50 (1.51,13.4)	5.31 (1.15, 24.5)	7.96 (2.02, 31.4)	8.9 (2.27, 35.1)
Caucasian Race	2.73 (1.05, 7.08)	1.70 (0.43, 6.77)	1.90 (0.55, 6.53)	
Stromal keratitis	7.14 (2.56, 19.9)	5.91 (1.38, 25.3.5)	8.37 (2.26, 30.9)	9.69 (2.66, 35.4)
Model Fit AIC		87.7	75.2	72.6
Likelihood Ratio		P<0.004	P<0.0001	P<0.0001

[a] Full logistic regression model adjusting for *a priori* conceptualized factors of importance: age, gender, race, ethnicity, immunosuppressed status, medications within 72 hours, antivirals, steroids, initial visual acuity, epithelial keratitis, stromal keratitis, endothelial keratitis, uveitis.

[b] Parsimonious model adjusting for age, race, gender, stromal keratitis

[c] Parsimonious model adjusting for gender, stromal keratitis (removing all other non-significant variables)

C. Specific Aim C: Vaccination Data

Of the 163,900 adult patients over age 50 seen during the study period, 687 patients (0.4%) received the shingles vaccine, including 58% female and 49% black patients. Of those patients who received the shingles vaccine, 4 (0.5%) patients had confirmed HZ a mean of 454 days following vaccination, including 2 (0.2%) patients with HZO. All patients were female and 50% were black. Of the 2 patients with HZO following vaccination, HZO developed 2 years (mean=784 days) following shingles vaccination; 1 patient had lymphoma, 1 patient had collagen vascular disease. Two patients who developed shingles 9 days and 238 days after vaccination, respectively, had no history of immunosuppression.

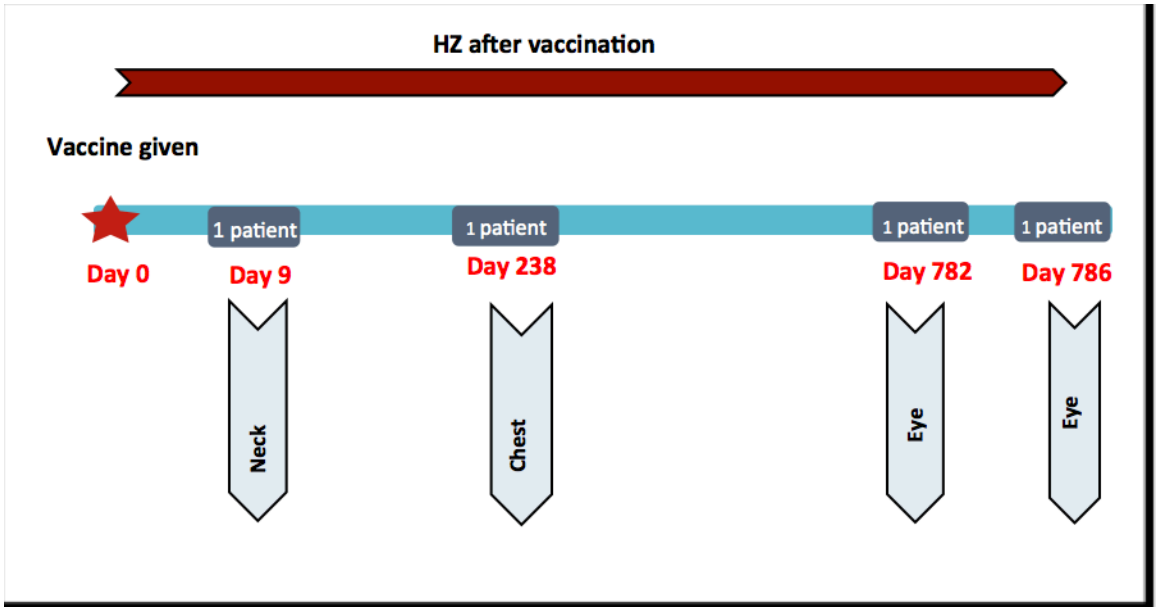

Figure 2. Time course for patients with HZ and shingles vaccination

IV. DISCUSSION

In this study, HZ affected 0.3% of the adult population seen at a large urban hospital system over the course of 5 years, with 20% of those affected having a diagnosis of HZO, though comprehensive chart review indicated that confirmed HZO with ocular involvement was present in 8.9% of patients with HZ. More than one quarter of HZO patients with eye involvement developed ocular complications within 1 year of diagnosis of HZO, with female gender and stromal keratitis being significant risk factors for development of complications.

A. Gender in HZ/HZO

Our study demonstrated that HZ affects women more often than men, with 60% of HZ patients and 56% of HZO patients with female gender, and that female gender is more likely to be associated with development of ocular complications. Several other studies have similar findings of HZ occurring more commonly in women[18,25,42]; other studies that did not demonstrate this were from predominantly male veterans administration populations.[10]

It has been postulated that women may have a different response to latent viral infection than men, with one study demonstrating that women had a higher incidence of shingles and herpes simplex virus infection compared to men, while there was no difference in primary varicella zoster virus infection.[25] Animal models and human studies have demonstrated biological differences between female and males in innate and adaptive immunity, with females demonstrating higher levels of pro-inflammatory proteins and more robust cell-mediated and humoral responses

to antigens compared to males.[27] While in theory, this upregulated cell-mediated response should provide some protective effect against developing HZ, the subsequent proinflammatory pathway may lead to development of more severe disease with complications. Sex hormones, including a decline in levels of estrogen and progesterone with menopause, most likely play some role in the differential immune response and thereby susceptibility to HZ in females compared to males. Female patients also have different responses to vaccinations, with higher efficacy but higher rates of adverse reactions, including inflammatory reactions. Regardless of the mechanism for why female patients have a higher incidence of HZ, they represent a group to be targeted for shingles vaccination. Among the patients vaccinated in our study, 58% were female.

It is also unclear whether women are more likely to seek out care for HZ, including tertiary eye care. In one study on health seeking behaviors, there was no difference in seeking care for HZ based on sex, and 91% of individuals sought care for HZ.[43]

B. <u>Initial Eye Findings as Risk Factors for Complications in HZO</u>

Stromal keratitis was also highly associated with the development of ocular complications. In other studies, stromal keratitis has been associated with higher risk for vision loss compared to other types of presenting features of HZO.[9] Because of the pathophysiology of HZO associated stromal keratitis, it is possible that this type of inflammation is an intermediate variable in the conceptual model on the development of ocular complications. Recurrent stromal keratitis can lead to

opacification of the cornea and development of abnormal blood vessels within the otherwise clear cornea; both of these were included among possible ocular complications. However, other types of keratitis, including epithelial keratitis and endothelial keratitis can also lead to the development of these complications. We included stromal keratitis in the final regression models because it does not directly lead to all of the possible ocular complications, including glaucoma, uveitis, and reduced corneal sensation. Many patients with HZO may also present with one finding such as conjunctivitis on initial presentation and then develop a different type of inflammation (stromal keratitis) if they have recurrent disease. [10] To date, there is not a good understanding of why some patients present with one particular eye finding (i.e. epithelial or stromal keratitis) compared to other patients (conjunctivitis only), but based on our data, stromal keratitis is a risk factor for subsequent ocular complications. In a sensitivity analysis removing stromal keratitis from the regression models, there was no difference in the direction, magnitude or significance of the other variables.

There appeared to be an inverse relationship between stromal keratitis and conjunctivitis/rash. This again may have been related to the fact that complete cases included in analysis could have been initially diagnosed elsewhere and referred to the UIH eye clinics within 1 year of initial diagnosis. This may introduce a referral bias since patients who were initially seen in the community and then referred in to a tertiary care eye center are more likely to have more severe disease. Patients who were initially seen in our health system with acute HZO with rash and eye findings such as conjunctivitis may be less likely to develop ocular complications. In a study

of antiviral use in HZO, patients treated with antivirals were more likely to have conjunctivitis than untreated patients; it is unclear whether this represents the fact that treated patients had less severe disease or that conjunctivitis is an early disease manifestation and may be seen in patients who present with acute disease. [30] In a number of studies, conjunctivitis represents the most common ocular manifestation of HZO.[9,10] We excluded cases where patients were lost to follow up at the 6 month or 1 year follow up visit in order to avoid the assumption that cases who did not follow up did not develop ocular complications. In a sensitivity analysis, we removed conjunctivitis from the final regression model in case of the (inverse) collinearity between conjunctivitis and stromal keratitis without a significant effect on the magnitude or direction of the results.

Prior studies have lacked standardization on the definition and timing of ocular complications in HZO. Some studies describe ocular complications at the onset of disease, while others refer to acute compared to chronic or recurrent disease.[8-10,12] While presenting eye manifestations are commonly reported, including conjunctivitis, keratitis by type (epithelial, stromal, endothelial), or uveitis, there is variability in description of ocular complications. Some studies focus on inflammatory (i.e. keratitis, uveitis) compared to non-inflammatory (i.e. neurotrophic keratitis) complications, whereas other studies focus more on visual acuity outcomes and risk factors for vision loss.[12,29] In this study, we identified presenting eye manifestations and then recorded eye findings, including complications at 6 months and 1 year follow up because of the potential for different ocular manifestations past the acute phase of disease. By the 6 month follow up

visit, it can be possible to distinguish between those patients with HZO who are developing/have developed ocular complications and may require long-term anti-inflammatory and/or antiviral therapy and those whose disease resolves after the acute episode without additional sequelae.

C. Vaccination

Uptake of shingles vaccination with the ZVL was low in our patient population. Insurance coverage for vaccination is not guaranteed or requires a co-payment, which may contribute to low patient willingness for vaccination. Patients may also have a number of other co-morbidities and primary care providers may make shingles vaccination a lower priority compared to influenza or pneumococcal vaccines in elderly patients. Alternatively, patients may have been vaccinated outside our health care system, but this is unlikely because most patients receive this vaccine through their primary care physician visits, which were captured by our record review.

Reactivation of HZ was low after shingles vaccination, with only 4 cases reported among 687 vaccinees, 2 of which had HZO and known immunocompromised states. As discussed previously, certain immunocompromised states are acceptable for receiving the live vaccine, but the individual's immune response to the vaccine may not be as robust as an immunocompetent patient. This may be the reason why we saw 2 patients develop HZO within 2 years after vaccination; it is known that the effect of ZVL wanes over time and is less efficacious in older patients. This may also hold true for patients with different levels of

immunosuppression. Our study time period preceded RZV availability, but there may be additional barriers to this type of vaccination in this patient population, including the high cost of the vaccine and need for 2 doses 2 months apart.

D. Limitations

This study has limitations as a retrospective study. Because we were conducting initial searches from a clinical research hospital database, there were variables such as smoking status and body mass index that we did not have access to that may have provided additional information on factors associated with complications in HZ and HZO. It would have been helpful to have more information regarding development of post-herpetic neuralgia in our HZ patient population, as this condition is a known complication that can be associated with HZO and can be associated with significant morbidity. In our hospital system, pain management for post-herpetic neuralgia is most often managed by the primary care physician and so data on medications and severity were lacking from the more detailed ophthalmology chart review. Since this study was conducted, the patient electronic medical record contains information regarding smoking status and pain level for each patient; going forward, newer electronic medical record systems will enable improvement in capturing data on potentially modifiable factors that may be related to development of HZ. These factors include but are not limited to tobacco and alcohol use, body mass index, immunosuppressive medications, underlying blood disorders such as anemia, and vitamin D deficiency, which may play a role in development of HZ.

Another limitation is that only one trained ophthalmologist was conducting the chart review of patients that had been managed by other ophthalmologists. From discerning handwriting on paper charts to interpreting exam details, there could be errors in recording specifics of initial presentation and ocular complications in HZO. However, our use of strict inclusion criteria for complete cases for analysis and review and exclusion of incorrect diagnosis codes contributed to the overall validity of our data.

Use of ICD-9 diagnosis codes can be problematic in terms of accuracy of identifying patients with an actual diagnosis of HZO. During the chart review, many cases of herpes simplex keratitis were noted to be incorrectly coded as HZO; even the clinical chart demonstrated inconsistencies given the commonly used abbreviations of HZV (for herpes zoster keratitis) and HSV (herpes simplex keratitis). Although health system studies examining ICD-9 code accuracy have demonstrated good positive predictive values for HZO with 138 of 152 cases identified by ICD-9 code confirmed by medical record review similar to how this study was conducted, there are still potential coding errors that can occur.[15] A recent study demonstrated the use of natural language processing algorithms to detect specific HZO diagnoses from medical chart review.[44] These natural language processing algorithms were able to search through over 1 million clinic visit notes to detect sentences and sections within the medical record that would identify cases of HZO; compared to 1.7% of patients with HZO identified with ICD-9 diagnosis code, this system identified 13.9% of patients with HZO.[44] These algorithms may provide

a promising method of conducting future epidemiologic studies on less common diagnoses that may be otherwise incorrectly or inadequately coded.

The fact that there is a tertiary care eye center within our hospital system likely contributes to the fact that our numbers of overall eye involvement and ocular complications are high compared to population based studies.[8] Of the 27 cases of HZO not included in complete case analysis, 52% had some type of ocular complication at last follow up, 44% had corneal scarring and 26% had a surgical procedure such as a corneal transplant for ocular complications related to HZO. While the numbers of ocular complications may be inflated due to the nature of our referral base and may not be generalizable to all HZ or HZO cases, it sheds light on the most severe cases and significant morbidity that can be associated with HZO.

V. CONCLUSIONS AND FUTURE DIRECTIONS

HZ and HZO are of significant public health concern given the increasing incidence, younger age at onset, and significant morbidity associated with disease. While traditionally thought to affect the elderly, HZ was seen in middle aged individuals in our cohort. Female patients had a higher incidence of HZO and were more likely to develop ocular complications. Stromal keratitis is also an important risk factor for the development of ocular complications in HZO.

Vaccination for shingles is low in this patient population, as was reactivation of HZ related to the live virus shingles vaccine. There is no available data for rates of use of the recombinant shingles vaccine, but this may be a promising intervention to prevent HZ and HZO in adult populations over age 50.

A current randomized clinical trial, the Zoster Eye Disease study, is examining whether chronic antiviral therapy may help to prevent chronic or recurrent inflammation in HZO patients (clinicaltrials.gov NCT03134196). Results of this study may be beneficial for patients with risk factors for ocular complications in HZO in preventing ongoing disease and vision loss.

As our treatment and prevention options for HZ and HZO grow, knowledge of the epidemiologic characteristics of HZ and HZO can help to target at risk populations for appropriate utilization of vaccination and treatments and prevention of disease and morbidity.

CITED LITERATURE

1. Liesegang TJ. Herpes zoster ophthalmicus natural history, risk factors, clinical presentation, and morbidity. *Ophthalmology.* 2008;115(2 Suppl):S3-12.

2. Ragozzino MW, Melton LJ, 3rd, Kurland LT, Chu CP, Perry HO. Population-based study of herpes zoster and its sequelae. *Medicine (Baltimore).* 1982;61(5):310-316.

3. McDonald EM, de Kock J, Ram FS. Antivirals for management of herpes zoster including ophthalmicus: a systematic review of high-quality randomized controlled trials. *Antivir Ther.* 2012;17(2):255-264.

4. Warren-Gash C. Herpes Zoster: Epidemiological Links With Stroke and Myocardial Infarction. *J Infect Dis.* 2018;218(suppl_2):S102-S106.

5. Erskine N, Tran H, Levin L, et al. A systematic review and meta-analysis on herpes zoster and the risk of cardiac and cerebrovascular events. *PLoS One.* 2017;12(7):e0181565.

6. Zerboni L, Sen N, Oliver SL, Arvin AM. Molecular mechanisms of varicella zoster virus pathogenesis. *Nat Rev Microbiol.* 2014;12(3):197-210.

7. Laing KJ, Ouwendijk WJD, Koelle DM, Verjans G. Immunobiology of Varicella-Zoster Virus Infection. *J Infect Dis.* 2018;218(suppl_2):S68-S74.

8. Yawn BP, Wollan PC, St Sauver JL, Butterfield LC. Herpes zoster eye complications: rates and trends. *Mayo Clin Proc.* 2013;88(6):562-570.

9. Szeto SK, Chan TC, Wong RL, Ng AL, Li EY, Jhanji V. Prevalence of Ocular Manifestations and Visual Outcomes in Patients With Herpes Zoster Ophthalmicus. *Cornea.* 2017;36(3):338-342.

10. Tran KD, Falcone MM, Choi DS, et al. Epidemiology of Herpes Zoster Ophthalmicus: Recurrence and Chronicity. *Ophthalmology.* 2016;123(7):1469-1475.

11. Kaufman SC. Anterior segment complications of herpes zoster ophthalmicus. *Ophthalmology.* 2008;115(2 Suppl):S24-32.

12. Ghaznawi N, Virdi A, Dayan A, et al. Herpes zoster ophthalmicus: comparison of disease in patients 60 years and older versus younger than 60 years. *Ophthalmology.* 2011;118(11):2242-2250.

13. Hoang-Xuan T, Buchi ER, Herbort CP, et al. Oral acyclovir for herpes zoster ophthalmicus. *Ophthalmology.* 1992;99(7):1062-1070; discussion 1070-1061.

14. Ho JD, Xirasagar S, Lin HC. Increased risk of a cancer diagnosis after herpes zoster ophthalmicus: a nationwide population-based study. *Ophthalmology.* 2011;118(6):1076-1081.

15. Pimentel MA, Browne EN, Janardhana PM, et al. Assessment of the Accuracy of Using ICD-9 Codes to Identify Uveitis, Herpes Zoster Ophthalmicus, Scleritis, and Episcleritis. *JAMA Ophthalmol.* 2016;134(9):1001-1006.

16. Wolfson LJ, Daniels VJ, Altland A, Black W, Huang W, Ou W. The Impact of Varicella Vaccination on the Incidence of Varicella and Herpes Zoster in the United States: Updated Evidence From Observational Databases, 1991-2016. *Clin Infect Dis.* 2019.

17. Borkar DS, Tham VM, Esterberg E, et al. Incidence of herpes zoster ophthalmicus: results from the Pacific Ocular Inflammation Study. *Ophthalmology.* 2013;120(3):451-456.

18. Kong CL, Thompson RR, Porco TC, Kim E, Acharya NR. Incidence Rate of Herpes Zoster Ophthalmicus: A Retrospective Cohort Study from 1994 through 2018. *Ophthalmology.* 2019.

19. Kawai K, Gebremeskel BG, Acosta CJ. Systematic review of incidence and complications of herpes zoster: towards a global perspective. *BMJ Open.* 2014;4(6):e004833.

20. Chan AY, Conrady CD, Ding K, Dvorak JD, Stone DU. Factors associated with age of onset of herpes zoster ophthalmicus. *Cornea.* 2015;34(5):535-540.

21. Davies EC, Pavan-Langston D, Chodosh J. Herpes zoster ophthalmicus: declining age at presentation. *Br J Ophthalmol.* 2016;100(3):312-314.

22. Hope-Simpson RE. The Nature of Herpes Zoster: A Long-Term Study and a New Hypothesis. *Proc R Soc Med.* 1965;58:9-20.

23. Yawn BP, Gilden D. The global epidemiology of herpes zoster. *Neurology.* 2013;81(10):928-930.

24. Schroder C, Enders D, Schink T, Riedel O. Incidence of herpes zoster amongst adults varies by severity of immunosuppression. *J Infect.* 2017;75(3):207-215.

25. Fleming DM, Cross KW, Cobb WA, Chapman RS. Gender difference in the incidence of shingles. *Epidemiol Infect.* 2004;132(1):1-5.

26. Weinberg A, Enomoto L, Marcus R, Canniff J. Effect of menstrual cycle variation in female sex hormones on cellular immunity and regulation. *J Reprod Immunol.* 2011;89(1):70-77.

27. Fink AL, Klein SL. Sex and Gender Impact Immune Responses to Vaccines Among the Elderly. *Physiology (Bethesda).* 2015;30(6):408-416.

28. Nithyanandam S, Dabir S, Stephen J, Joseph M. Eruption severity and characteristics in herpes zoster ophthalmicus: correlation with visual outcome, ocular complications, and postherpetic neuralgia. *Int J Dermatol.* 2009;48(5):484-487.

29. Nithyanandam S, Stephen J, Joseph M, Dabir S. Factors affecting visual outcome in herpes zoster ophthalmicus: a prospective study. *Clin Exp Ophthalmol.* 2010;38(9):845-850.

30. Severson EA, Baratz KH, Hodge DO, Burke JP. Herpes zoster ophthalmicus in olmsted county, Minnesota: have systemic antivirals made a difference? *Arch Ophthalmol.* 2003;121(3):386-390.

31. Oxman MN, Levin MJ, Johnson GR, et al. A vaccine to prevent herpes zoster and postherpetic neuralgia in older adults. *N Engl J Med.* 2005;352(22):2271-2284.

32. Morrison VA, Johnson GR, Schmader KE, et al. Long-term persistence of zoster vaccine efficacy. *Clin Infect Dis.* 2015;60(6):900-909.

33. Williams WW, Lu PJ, O'Halloran A, et al. Surveillance of Vaccination Coverage among Adult Populations - United States, 2015. *MMWR Surveill Summ.* 2017;66(11):1-28.

34. Willis ED, Woodward M, Brown E, et al. Herpes zoster vaccine live: A 10year review of post-marketing safety experience. *Vaccine.* 2017;35(52):7231-7239.

35. Heath G, Depledge DP, Brown JR, et al. Acute Retinal Necrosis Caused by the Zoster Vaccine Virus. *Clin Infect Dis.* 2017;65(12):2122-2125.

36. Charkoudian LD, Kaiser GM, Steinmetz RL, Srivastava SK. Acute retinal necrosis after herpes zoster vaccination. *Arch Ophthalmol.* 2011;129(11):1495-1497.

37. Menghini M, Raja V, Raiter J, Balaratnasingam C, Constable IJ. Acute Retinal Necrosis Associated with Herpes Zoster Vaccination. *Retin Cases Brief Rep.* 2018.

38. Lal H, Cunningham AL, Godeaux O, et al. Efficacy of an adjuvanted herpes zoster subunit vaccine in older adults. *N Engl J Med.* 2015;372(22):2087-2096.

39. Cunningham AL, Lal H, Kovac M, et al. Efficacy of the Herpes Zoster Subunit Vaccine in Adults 70 Years of Age or Older. *N Engl J Med.* 2016;375(11):1019-1032.

40. Hesse EM, Shimabukuro TT, Su JR, et al. Postlicensure Safety Surveillance of Recombinant Zoster Vaccine (Shingrix) - United States, October 2017-June 2018. *MMWR Morb Mortal Wkly Rep.* 2019;68(4):91-94.

41. Bastidas A, de la Serna J, El Idrissi M, et al. Effect of Recombinant Zoster Vaccine on Incidence of Herpes Zoster After Autologous Stem Cell Transplantation: A Randomized Clinical Trial. *JAMA.* 2019;322(2):123-133.

42. Kawai K, Yawn BP. Risk Factors for Herpes Zoster: A Systematic Review and Meta-analysis. *Mayo Clin Proc.* 2017;92(12):1806-1821.

43. Hales CM, Harpaz R, Bialek SR. Self-reported herpes zoster, pain, and health care seeking in the Health and Retirement Study: implications for interpretation of health care-based studies. *Ann Epidemiol.* 2016;26(6):441-446 e443.

44. Zheng C, Luo Y, Mercado C, et al. Using natural language processing for identification of herpes zoster ophthalmicus cases to support population-based study. *Clin Exp Ophthalmol.* 2019;47(1):7-14.

VITA

Name: Ann-Marie Lobo-Chan

Education

2001	BA *magna cum laude*	Psychology	Rice University
2005	MD with honors	Medicine	LSUHSC-New Orleans
2020	MS (candidate)	Epidemiology	University of Illinois School of Public Health

Postdoctoral Training

6/05-6/06	Intern	Transitional Intern	Cambridge Health Alliance
7/06-6/09	Resident	Ophthalmology	Harvard Medical School, Massachusetts Eye and Ear Infirmary
7/09-7/10	Clinical Fellow	Ocular Immunology/ Uveitis	Harvard Medical School, Massachusetts Eye and Ear Infirmary

Faculty Academic Appointments

8/10-6/14	Instructor	Ophthalmology	Harvard Medical School
7/14-7/15	Assistant Professor	Ophthalmology	Harvard Medical School
8/15-present	Assistant Professor	Ophthalmology	University of Illinois at Chicago

Honors and Prizes

1997-2001	Rice Presidential Honors	Rice University	Academic recognition
2001	Psi Chi Honor Society	National Psychology Honor Society	Academic achievement
2001	Golden Key National Honor Society	National Honor Society	Academic achievement
2003	National Student Research Forum		Research award
2001-2005	LSUHSC Honors Program	LSUHSC	Research program award
2004-2005	Alpha Omega Alpha	National Medical Honor	Academic

		Society	achievement
2005	Luis Perez Memorial Award	LSUHSC Department of Ophthalmology	Academic award
2008	Visionary of Boston		Volunteer award
2017-	Best Doctors in America		Recognition award by peers
2019	Achievement Award	American Academy of Ophthalmology	Award for contributions to Academy scientific and educational programs
2019	Castle Connolly	Top Doctor's: Exceptional Women in Medicine	Recognition award by peers
2019-20	Illinois Magazine Top Doctor's	Top Ophthalmologist	
2020	Castle Connolly	Top Doctor	Recognition award by peers

Appointments at Hospitals/Affiliated Institutions

8/10-12/13	Staff Ophthalmologist	Ophthalmology	Massachusetts Eye and Ear Infirmary
8/10-7/15	Staff Ophthalmologist	Ophthalmology	Massachusetts General Hospital Brigham and Women's Hospital
1/14-7/15	Associate Surgeon	Ophthalmology	Massachusetts Eye and Ear Infirmary
8/15-present	Physician Surgeon	Ophthalmology	University of Illinois Hospital

Major Administrative Leadership Positions

Local

2015	Course co-director, Uveitis Instruction Course	Massachusetts Eye and Ear Infirmary
2016-present	Co-director, Uveitis Service	University of Illinois at Chicago, Department of Ophthalmology & Visual Sciences
2019-present	Co-director, Uveitis/Medical Retina Fellowship	University of Illinois at Chicago, Department of Ophthalmology & Visual Sciences

Regional, National and International

2017-2018	Leadership Development Program for Women	Association for Research in Vision and Ophthalmology

Committee Service

Local

2013	Pharmacy and Therapeutics Committee 2013-2014	Massachusetts Eye and Ear Infirmary Ophthalmology Physician Representative
2017	Customer Service Committee	University of Illinois at Chicago, Department of Ophthalmology & Visual Sciences

Regional, National and International

2013-present	Item Writing Committee for American Board of Ophthalmology Written and Oral Board Examinations 2013-present	American Board of Ophthalmology Uveitis Committee Member
2013-present	Ophthalmic Knowledge Assessment Program Committee 2013-present	American Academy of Ophthalmology Uveitis Subspecialty Committee Representative
2016-2019	Diversity Initiatives Committee	Association for Research in Vision and Ophthalmology
2019-present	Program Chair	Chicago Ophthalmological Society

Professional Societies

2006-present	American Academy of Ophthalmology	Fellow
2007-present	Association for Research in Vision and Ophthalmology	Member
2008-present	Women in Ophthalmology	Member
2008-present	American Society of Cataract and Refractive Surgeons	Member
2010-present	American Uveitis Society	Member
2012-present	Asia Pacific Academy of Ophthalmology	Scientific Program Chair 2013, 2019
2013-present	New England Ophthalmologic Society	

	2013-2015	Member, Program Committee
2015-present	International Ocular Inflammation Society	Member
2015-present	American Eye Study Club	Member
2015-present	Chicago Ophthalmological Society	Member

Editorial Activities

2016-	Editorial Board Member	Ophthalmology News and Education Network, American Academy of Ophthalmology
2018-	Section Editor	Advances in Ophthalmology and Optometry, Volume 3

Peer reviewed publications in print or other media

Research Investigations

1. Li, J.Z., Tucker, J.D., **Lobo, A**.M., Marra, C.M., Davis, B.T., Papaliodis, G.N., Felsenstein, D., Durand, M.L., Yawetz, S., Robbins, G.K. Ocular syphilis in HIV-positive individuals. *Clin Infect Dis.* 2010 Aug 15;51(4): 468-71. PMID: 20604717

2. Tucker, J.D, Li, J.Z., Robbins, G.K., Davis, B.T., **Lobo, A**.M., Kunkel, J., Papaliodis, G.N., Durand, M.L., Felsenstein, D. Ocular Syphilis Among HIV Patients: A Systematic Analysis of the Literature. *Sexually Transmitted Infections.* 2011 Feb;87(1):4-8. PMID: 20798396

3. William, M., Faez, S., Papaliodis, G.N., **Lobo, A.M**. Golimumab for the treatment of refractory juvenile idiopathic arthritis associated uveitis. *J Ophthalmic Inflamm Infect*. 2012 Dec; 2(4):231-3. PMID: 22581347

4. Faez S., **Lobo A.M.**, Sobrin L., Papaliodis G.N. Treatment of seronegative spondyloarthropathy-associated uveitis with golimumab: retrospective case series. *Clin Experiment Ophthalmol.* 2014 May-Jun;42(4):392-5. PMID: 24024585

5. Faez,S., **Lobo, A.M**., Unizony,S.H., Stone, J.H, Papaliodis, G.N., Sobrin, L. Ocular inflammatory disease in patients with Polymyalgia Rheumatica: A case series and review of the literature. *Clin Rheumatology* 2016 Jan;35(1):251-8. PMID: 24696366

6. Lou, S., Larkin, K., Winthrop, K., Rosenbaum, J., and members of Uveitis Specialists Study Group. Lack of consensus in the diagnosis and treatment of ocular tuberculosis among uveitis specialists. *Ocular Immunology and Inflammation*. 2015 Feb;23(1):25-31. (member of Uveitis specialists study group). PMID: 25019973

7. Papavasileiou, E., Prasad, S., Freitag, S.K., Sobrin, L., **Lobo, A.M.** Ipilimumab-

induced ocular and orbital inflammation. *Ocular Immunology and Inflammation.* 2016 Apr;24(2):140-6. PMID: 25760920.

8. Roh, M., Yasa, C., Cho, H., Nicholson, L., Uchiyama, E., Young, L.H., **Lobo, A.M**., Papaliodis, G.N., Durand, M.L., and Sobrin, L. The role of serological titres in the diagnosis of ocular toxoplasmosis. *Acta Ophthalmol*. 2016 Aug; ;94(5):521-2. PMID 26426456.

9. Davoudi, S., Navarro-Gomez, D., Shen, L., Ung, C., Ren, A., Sullivan, L., Kwon, M., Janessian, M., Comander, J., Gai, X., **Lobo, A.M.**, Papaliodis, G.N., Sobrin, L. NOD2 genetic variants and sarcoidosis-associated uveitis. *American Journal Ophthalmology Case Reports*. 2016 Jun 1;3:39-42. PMID: 29503906.

10. Grotting, L.A., Davoudi, S., Uchiyama, E., **Lobo, A.M**., Papaliodis, G.N., Sobrin, L. Pre-papillary vitreous opacities associated with Behcet's disease: a case series and review of the literature. *Graefe's Archive for Clinical and Experimental Ophthalmology.* 2017 Oct;255(10):2017-2021. PMID: 28725920.

11. Sevgi, D.D., Davoudi, S., Talcott, K.E., Cho, H., Guo, R., **Lobo, A.M.,** Papaliodis, G.N., Turalba, A., Sobrin, L., Shen, L. A retrospective study on the effects of the fluocinolone implant and Ahmed valve in patients with uveitic glaucoma. *Digital Journal of Ophthalmology.* 2017 Sep 11;23(3):63-70. PMID: 29162989

12. Davoudi S, Chang VS, Navarro-Gomez D, Stanwyck LK, Sevgi DD, Papavasileiou E, Ren A, Uchiyama E, Sullivan L, **Lobo AM**, Papaliodis GN, Sobrin L. Association of genetic variants in *RAB23* and *ANXA11* with uveitis in sarcoidosis. *Molecular Vision.* 2018 Jan 21;24:59-74. PMID:29416296.

13. **Lobo, A.M**., Gao, Y., Rusie, L., Houlberg, M., Mehta, S.D. Association between eye diagnosis and positive syphilis test results in a large, urban sexually transmitted infection/primary care clinic population. *International Journal of STD & AIDS.* 2018 Mar;29(4):357-361. PMID:28820347.

14. Borkar DS, Moustafa GA, Eton EA, Koulisis N, Kloek CE; **Perioperative Care for Intraocular Lens Study Group.** Incidence of unexpected peripheral retinal findings on dilated examination 1 month after cataract surgery: Results in the Perioperative Care for Intraocular Lens Study. J Cataract Refract Surg. 2018 Jun;44(6):780-781. PMID:29861055.

15. Moustafa GA, Borkar DS, McKay KM, Eton EA, Koulisis N, Lorch AC, Kloek CE; **PCIOL Study Group**. Outcomes in resident-performed cataract surgeries with iris challenges: Results from the Perioperative Care for Intraocular Lens study. *J Cataract Refract Surg*. 2018 Dec;44(12):1469-1477. PMID: 30391157

16. Borkar DS, Lains I, Eton EA, Koulisis N, Moustafa GA, van Zyl T, Kloek CE; **PCIOL Study Group**. Incidence of Management Changes at the Postoperative Week One Visit after Cataract Surgery: Results from the PCIOL Study. *Am J Ophthalmol*. 2018 Oct 16. Epub ahead of print. PMID:30339795.

17. Darwish, DY, Patel SN, Gao Y, Bhat P, Chau FY, Lim JI, Kim JE, Jose J, Jonas KE, Chan RVPC, Mehta SD, **Lobo, AM.** Diagnostic Accuracy and Reliability of Retinal Pathology Using the Forus 3nethra Fundus Camera Compared to Ultra Wide-Field Imaging. *Eye*. 2019 Jan 24. Epub ahead of print. PMID: 30679873.

18. Oliver GF, Stathis RM, Furtado JM, Arantes TE, McCluskey PJ, Matthews JM; **International Ocular Syphilis Study Group,** Smith JR. Current ophthalmology practice patterns for syphilitic uveitis. *Br J Ophthalmol.* 2019 Jan 30. Epub ahead of print. PMID: 31021330.

Other Peer Reviewed Publications:

1. Thiagalingam, S., Tarongoy, P., Hamrah, P., **Lobo, A**.M., Nagao, K., Barsam, C., Bellows, R., Pineda, R. Making brown eyes blue: complications of cosmetic iris implants. *J Cataract Refract Surg* 2008;34(7):1222-1224. PMID: 18571095

2. **Lobo, A.M.** and Papaliodis, G.N. A 37 year old man with a black spot in his vision: a case of Susac syndrome. Digital Journal of Ophthalmology. Grand Rounds case. www.djo.harvard.edu. PMID: 23362373

3. Lobo, A.M., Stacy, R., Cestari, D., Stone, J.H., Jakobiec, F.A., Sobrin, L. Optic nerve involvement with panuveitis in Sweet syndrome. *Ocular Immunology and Inflammation*. 2011 Jun;19(3):167-70. PMID: 21595532

4. Hunter, R.S., and **Lobo, A.M.** Dexamethasone intravitreal implant for the treatment of noninfectious uveitis. *Clinical Ophthalmology* 2011;5:1613-1621. PMID: 22140307

5. **Lobo, A.M.,** Rhee, D. Delayed interval of involvement of the second eye in a male patient with bilateral Chandler's syndrome. *British Journal of Ophthalmology*. 2012;96:146-147. PMID: 20710048

6. Huynh, N., Shildkrot, E., **Lobo, A.M.,** Sobrin, L. Intravitreal triamcinolone for cancer-associated retinopathy refractory to systemic therapy. *J Ophthalmic Inflamm Infect.* 2012 Sep;2(3):169-71. PMID: 22415770

7. Papavasileiou, E. and **Lobo, A.M**. Birdshot chorioretinopathy in a male patient with facioscapulohumeral muscular dystrophy. *J Ophthalmic Inflamm Infect* 2015 Mar 12;5:7. PMID: 25861398

8. Gupta, M., Jardeleza, M.S.R., Kim, I., Durand, M., Kim, L., and **Lobo, A.M.** Varicella zoster virus necrotizing retinitis in two patients with Idiopathic CD4 Lymphocytopenia. *Ocular Immunology and Inflammation.* 2016 Oct; 24(5):544-8. PMID: 26472486

9. **Lobo, A.M.**, Agelidis, A.M., Shukla, D. Pathogenesis of herpes simplex keratitis: the host cell response and ocular surface sequelae to infection and inflammation. *The Ocular Surface.* 2019 Jan;17(1):40-49. PMID: 30317007

10. Munro, M., Yadavalli, T., Fonteh, C., Arfeen, S., **Lobo-Chan, A.M**. Cytomegalovirus retinitis in HIV and non-HIV individuals. *Microorganisms MDPI.* 2020

Non-peer reviewed scientific or medical publications/materials in print or other media

1.Lobo, A.M. and Papaliodis, G.N. Perioperative evaluation and management of cataract surgery in uveitis patients. *International Ophthalmology Clinics*.Winter 2010; 50(1): 129-37. PMID: 20057302

2. Lobo, A.M., Sobrin, L., and Papaliodis,G.N. Drug delivery options in the treatment of ocular inflammation. *Seminars in Ophthalmology*. 2010 Sep-Nov; 25(5-6): 283-8. PMID: 21091013

3. Hunter, R. and **Lobo, A.M.** Current diagnostic approaches to infectious anterior uveitis. *International Ophthalmology Clinics.* 2011 Fall; 51(4):145-56. PMID: 21897147

4. **Lobo, A**.M. Anterior chamber biopsy. In: Eliott and Rao (eds), Surgical management of intraocular inflammation and infection. London: JP Medical, 2013: 33-40.

5. **Lobo, A.M**., Sobrin, L., and Durand, M.L. Ocular infections in transplant patients. In: Safdar (ed), Principles and Practice of Transplant Infectious Disease. New York: Springer. *In press.*

6. Lorch, A. and **Lobo, A.-M.** (2015) 'Iritis', in Schlossberg, D. (ed.) Clinical Infectious Disease:. Cambridge: Cambridge University Press, pp. 97–101.

7. Vodopivec, I., **Lobo, A.M**., and Prasad, S. Ocular inflammation in neuro-rheumatic disease. *Seminars in Neurology.* 2014 Sep;34(4):444-57. PMID: 25369440

8. Uchiyama, E., Papaliodis, G.N., **Lobo, A.M**., Sobrin, L. Side-effects of anti-inflammatory therapy in uveitis. *Seminars in Ophthalmology*. 2014 Nov; 29(5-6):456-67. PMID: 25325874

9. Liu, Y., **Lobo, A.M.** and Sobrin, L. Endophthalmitis in immunocompromised and

diabetic patients. In: Durand, Young, and Miller (eds). Endophthalmitis. New York: Springer, 2016:223-238.

10. **Lobo, A.M.** Juvenile idiopathic arthritis. In: Papaliodis, G.N. (ed) Uveitis: A practical guide to the diagnosis and treatment of intraocular inflammation. New York: Springer, 2017: 183-188.

11. Darwish, D., Zhou, M., **Lobo, A.M.** Viral retinitis. In: Rao, Rodger, Schallhorn (eds), Advances in Intraocular Inflammation Imaging and Treatment. New York: Springer.

12. Starnes, T.W., Bhat, P., **Lobo, A.M**. Birdshot chorioretinopathy. In: Gon Yu (eds), Retina Atlas: Inflammatory and infectious ocular disorders. New York: Springer.

13. Chen, J., **Lobo-Chan, A.M**., Chan, R.V.P.C., Bhat, P. Tumor necrosis factor alpha inhibitor therapy. In: Advances in the Diagnosis and Management of Uveitis. London: IntechOpen. 2019.

14. Chen, J., Bhat, P., **Lobo-Chan, A.M.** Perioperative management of uveitic cataracts. In: Yanoff (ed), Advances in Ophthalmology and Optometry, Volume 4. 2019.

Professional educational materials or reports, in print or other media

Lobo, A.M., Thiagalingam, S., Allen, C. Mucormycosis. Digital Journal of Ophthalmology. Oculoplastics Knowledge Review 23. www.djo.harvard.edu 2007.

Chee, R, Patel Gupta, M, **Lobo, A-M**, Chan, RVP. Update on the diagnosis and management of pediatric retinal disease. *Retinal Physician.* April 2017.

Retina Times: KOL Corner. Managing acute anterior uveitis. Spring 2019, Issue 78;Vol 37(1): 43-48.

Abstracts, Poster Presentations, and Exhibits Presented at Professional Meetings

1.Lobo, A.-M., Chodosh, J., Papaliodis, G.N. Immunosuppressive therapy with mycophenolate mofetil in patients receiving the Boston keratoprosthesis. Poster presentation, Association for Research in Vision and Ophthalmology, Fort Lauderdale, FL. 2010.

2. Benitah, N.R., Lobo, A.-M., Papaliodis, G.N. Outcomes of complicated cataract extractions in uveitic patients. Poster presentation, Association for Research in Vision and Ophthalmology, Fort Lauderdale, FL. 2011.

3. Hunter, R.S., Ledoux, D., Lobo, A.-M. Outcomes of TNF alpha inhibitor therapy in juvenile idiopathic arthritis associated uveitis. Poster presentation, Association for Research in Vision and Ophthalmology, Fort Lauderdale, FL. 2012

4. Lobo, A.-M., Faez, S., Sobrin, L., Papaliodis, G.N. Course of uveitis in arthritis patients on golimumab. Presentation, American Uveitis Society meeting, Chicago, IL. 2012

5. Lobo, A-M., Faez, S., Lo, M., Papaliodis, G.N., Ledoux, D. Ocular complications in juvenile idiopathic arthritis associated uveitis patients on TNF inhibitor therapy. Poster presentation, Association for Research in Vision and Ophthalmology, Orlando, FL. 2014

6. Papavasileiou, E., Prasad, S., Freitag, S.K., Sobrin, L., Lobo, A-M. Ipilimumab-induced ocular and orbital inflammation. Presentation, American Uveitis Society meeting, Chicago, IL. 2014

7. Zhou, M., Goldstein, D., Bhat, P., Leiderman, Y., Lim, J., Chau, F., Ulanski, L., Mieler, W., Lobo, A-M. Prognostic implications of quantitative polymerase chain reaction in the severity of necrotizing herpetic retinitis. Presentation, Association for Research in Vision and Ophthalmology, Seattle, WA. 2016

8. Lobo, A.-M., Rusie, L., Gao, Y, Houlberg, M, Mehta, S. Association between eye diagnosis and positive syphilis test results in a sexually transmitted infection/primary care clinic population. Presentation, Association for Research in Vision and Ophthalmology, Baltimore, MD. 2017

9. Jogin, J., Cortina, M.S., de la Cruz, J., Djalilian, A.R., Jain, S., Sugar, J., Tu, E., Lobo, A.-M. Visual outcomes and corneal surgery in patients diagnosed with herpetic stromal keratitis based on race. Association for Research in Vision and Ophthalmology, Baltimore, MD. 2017.

10. Darwish, D., Patel, SN, Kim, JE, Gao, Y, Bhat, P, Chau, FY, Lim, JI, Jonas, KE,

Chan, RV, Mehta, S, Lobo, A-M. Diagnostic accuracy and reliability of retinal pathology using the Forus 3nethra fundus camera compared to ultra wide-field imaging. Association for Research in Vision and Ophthalmology, Baltimore, MD. 2017

11. Ghelani, S, Bhat, P, Leiderman, YI, Lim, JI, Ulanski, LJ, Mieler, WF, Goldstein, DA, Lobo, A-M. A comparison of visual outcomes and clinical management of CMV retinitis in HIV and non-HIV positive patients. Association for Research in Vision and Ophthalmology, Baltimore, MD. 2017

12. Darwish, D., de la Cruz, J., Sugar, J., Lobo, A.-M. Reactivation of herpes zoster ophthalmicus following live varicella zoster virus vaccination. Association for Research in Vision and Ophthalmology, Honolulu, HI. 2018

13. Lobo, A.-M., Shukla, D. Heparanase upregulation in human corneal tissues infected with herpes simplex virus type 1. Association for Research in Vision and Ophthalmology, Honolulu, HI. 2018

14. Maiz, Alejandra, Alam, Minhaj Nur, Doctor, Priyanka, Lobo-Chan, Ann-Marie, Leiderman, Yannek, Lim, Jennifer I., Yao, Xincheng, Bhat, Pooja. Quantitative Analysis of OCT Angiography findings in Birdshot Chorioretinopathy. Association for Research in Vision and Ophthalmology, Honolulu, HI. 2018.

14. Darwish, D., de la Cruz, J., Sugar, J., Lobo, A-M. Ocular complications in herpes zoster ophthalmicus. Association for Research in Vision and Ophthalmology, Vancouver, BC. 2019

15. Arfeen, S., Bhat, P., Lobo, A-M. Outcomes of diagnostic anterior chamber tap in uveitis patients. Association for Research in Vision and Ophthalmology, Vancouver, BC. 2019

16. Haseeb, A., Munro, M., Lobo, A-M, Bhat, P. Topical carbonic anhydrase inhibitors as a therapeutic adjunct in uveitic cystoid macular edema. Association for Research in Vision and Ophthalmology, Baltimore, MD. 2020

17. Munro, M., Chang, A. Lobo, A-M, Bhat, P. Presumed tuberculosis uveitis: diagnostic and therapeutic challenges. Association for Research in Vision and Ophthalmology, Baltimore, MD. 2020